

## Case Report

---

# Solitary posterior triangle neck mass as the rare sole presentation of papillary thyroid carcinoma

Irfan Mohamad<sup>1</sup>, Thin Thin Win<sup>2</sup>, Md Salzihan Md Salleh<sup>2</sup>, Baharudin Abdullah<sup>1</sup>

### Abstract:

*Introduction: Papillary thyroid carcinoma is the most common differentiated thyroid malignancy. It offers good prognosis and the presentation is usually consistent with an enlarged thyroid, mostly solitary nodule which biochemically euthyroid and radiologically normal appearance. On rare occasions, the thyroid gland enlargement can present together with multiple neck lymphadenopathy.*

*Case report: We report a case of middle aged man presented with a posterior neck mass without any other symptom. Histopathology report of the excised mass confirmed the diagnosis of, papillary thyroid carcinoma which warranted total thyroidectomy and neck dissection.*

**Key words:** Lymphadenopathy, thyroid, carcinoma, papillary.

### Introduction:

Presence of thyroid follicular cells in fine needle aspiration for cytology (FNAC) of lateral neck swellings with benign-appearing thyroid tissue in lymph node should be evaluated with extreme caution. Excisional biopsy is necessary even if follicular cells are benign looking. If follicular cells are found in lymphoid background, the diagnosis is always metastatic papillary thyroid carcinoma (PTC). Owing to its propensity for lymphatic spread, cervical lymphadenopathy can be present without the primary tumour being evident<sup>1</sup>.

1. Department of Otorhinolaryngology - Head & Neck Surgery, School of Medical Sciences, Universiti Sains Malaysia Health Campus, 16150 Kota Bharu, Kelantan, Malaysia.
2. Department of Pathology, School of Medical Sciences, Universiti Sains Malaysia Health Campus, 16150 Kota Bharu, Kelantan, Malaysia.


**Address of Correspondence:** Dr. Irfan Mohamad, Department of Otorhinolaryngology - Head & Neck Surgery, School of Medical Sciences, Universiti Sains Malaysia Health Campus, 16150 Kota Bharu, Kelantan, Malaysia. Email : irfan@kb.usm.my

### Case report:

A 33-year-old Malay male, an army was referred for a right upper neck swelling which was slowly increasing in size over nine months duration. The mass did not cause any obstructive or compressive symptom. There was no hoarseness and any nasal complaint. He denied any contact with tuberculosis patient. He was free from any constitutional symptoms such as loss of weight or appetite, chronic cough or any swelling elsewhere in the body.

Clinical examination revealed a 6x5 cm neck swelling located at the right posterior triangle (level V). It was firm and non-tender, mobile in all directions, not attached to underlying structures or to the overlying skin which appeared normal. The mass did not change its size and position during both acts of respiration and deglutition. There was no other swelling either at midline or lateral to the mass, at all levels of the neck. Oral cavity and oropharyngeal examinations were normal. Nasoendoscopy, otoscopy and laryngoscopy also revealed normal findings.

Several investigations which include sputum for acid fast bacilli were negative, chest radiograph was normal and Mantoux test was insignificant. Ultrasonography of the neck revealed an enlarged right cervical lymph node with necrotic changes. FNAC showed normal thyroid follicles with no evidence of malignancy or any lymphoid background appreciated (Figure 1).



**Figure 1:** FNAC showed thyroid follicular cells, with no lymphoid background (x40, in Alcohol fixed Papanicolaou stain)

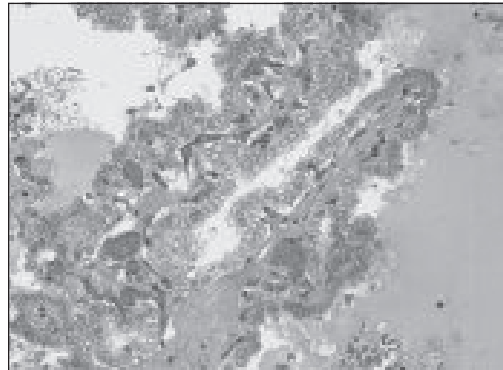
In view of suggestive of thyroid follicular cells in FNAC smears, metastatic thyroid carcinoma could not be ruled out. As the ultrasonography revealed no abnormality of the thyroid gland, computed tomography and radionuclide imaging of thyroid gland were requested. However, all of the radiological investigations gave no extra information besides normal appearance and activity of the thyroid (Figure 2).

Excision biopsy of the only mass was performed. Right level V cystic mass sized 4x5 cm was found located below posterior border of sternocleidomastoid muscle. There was no adhesion to the adjacent structures and no other lymph node seen. It was a well capsulated cystic mass, in which 4 cc of dark coloured fluid was aspirated. Our intra-operative finding diagnosis was branchial cyst.

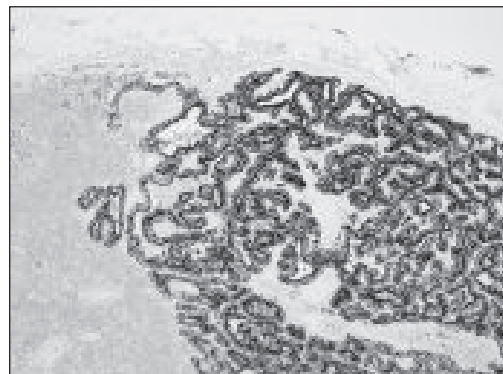

**Figure 2:** Normal uptake on radio-nuclide scanning of the thyroid, with cervical no node positivity demonstrated.

The mass was sent for histopathological examination. It was interpreted as metastatic papillary thyroid carcinoma (Figure 3).

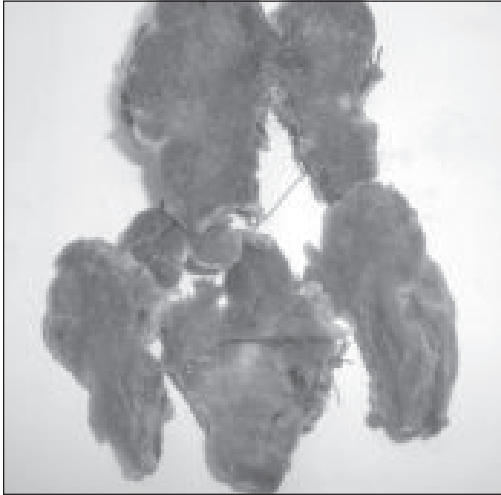


**Figure 3a:** Excised lateral neck swelling showed papillary structures(x40 magnification)

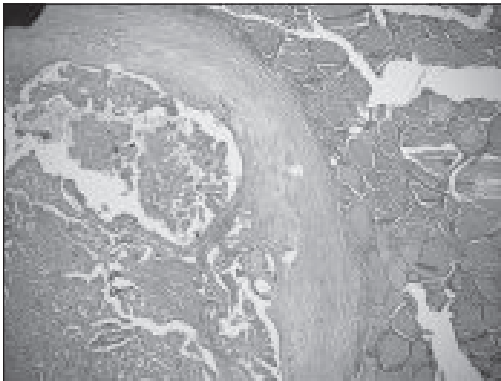


**Figure 3b:** Thyroglobulin IHC stain (x10 magnification)

Following the result, total thyroidectomy and right modified radical neck dissection type III was commenced. Gross specimen of 39 g thyroid gland was removed, together with fat pads in all levels of lymph node (Figure 4 & 5).



**Figure 4:** Both right lobe (upper specimen) and left lobe contained grey white area which signified solid component suggestive of primary lesions.



**Figure 5:** Section from grey white area of left lobe showed macropapillary structures which confirmed the diagnosis (x4)

The final result of PTC was revealed and out of 12 samples of LN histologically examined, only one at paratracheal was positive of metastasis.

#### Discussion:

The involvement of cervical LN in PTC may be the first manifestation of the disease. However, in our case, the pre-excision FNAC showed only thyroid follicular cells without features of lymph node background appreciated. Thus the diagnosis of ectopic or lateral aberrant thyroid was also entertained. The cystic metastasis in the lateral neck lymph node of a PTC may mimic a branchial cyst<sup>2</sup>.

The next step to confirm the diagnosis is by excision of the mass. Excision biopsy of any lateral neck cyst is essential in cases where results of FNAC and ultrasonography are inconclusive<sup>3</sup> As demonstrated in our case, the specimen confirmed the presence of metastatic thyroid carcinoma which warranted total thyroidectomy. Even the thyroid is not enlarged; the primary focus could be within the normal sized gland and be normal on radio-nuclide activity scanning. Intra-thyroidal PTC may be minute and careful examination of many sections may be required. In rare occasions, PTC primary site may disappear and might not be seen in thyroid.

A point to note is that a mass located medial to jugular vein, if contain benign thyroid tissue within the capsule or immediately sub-capsular, can be from thyroid inclusion or sequestered thyroid<sup>4</sup>. The thyroid tissue which is found lateral to the carotid sheath and jugular vein can be considered as lateral aberrant thyroid<sup>5</sup>. However, most of the reported lateral aberrant thyroid cases are not fulfill this definition<sup>6</sup>.

LiVolsi has specifically stated that normal appearing thyroid tissue anywhere within lymph nodes, lateral to the jugular vein represents metastatic papillary thyroid carcinoma, and the term lateral aberrant thyroid tissue should not be used for those lesions<sup>7</sup>. Another study reported a case of

follicular thyroid tissue was found in a lymph node lateral to the carotid sheath in the presence of a thyroid gland which was histologically free of cancer<sup>8</sup>.

**References:**

1. McDermott ID, Watters GW. Metastatic papillary thyroid carcinoma presenting as a typical branchial cyst. *J Laryngol Otol* 1996; 110: 490–2.
2. Verge J, Guixa J, Alejo M, et al. Cervical cystic lymph node metastasis as first manifestation of occult papillary thyroid carcinoma: report of seven cases. *Head Neck* 1999; 21: 370–4.
3. Monchik JM, De Petris G, De Crea C. Occult papillary carcinoma of the thyroid presenting as a cervical cyst. *Surgery* 2001; 129: 429–32.
4. Yuri E, Nikiforov, Paul W. Biddinger, Lester DR Thompson. Diagnostic Pathology and Molecular Genetics of the Thyroid: A Comprehensive Guide for Practicing Thyroid Pathology. Lippincott Williams & Wilkins, 2009; 11 - 28.
5. Batsakis JG, El-Naggar AK, Luna MA. Thyroid gland ectopias [secondary reference]. *Ann Otol Rhinol Laryngol* 1996; 105: 996 - 99.
6. Nishiyama RH. Overview of surgical pathology of the thyroid gland. *World J Surg* 2000; 24(8): 898 - 906.
7. LiVolsi VA. *Surgical Pathology of the Thyroid*. Philadelphia: W.B. Saunders, 1990; 3-23, 403-407.
8. Escofet X, Khan AZ, Mazarani W, Woods WG. Lessons to be learned: a case study approach. Lateral aberrant thyroid tissue: is it always malignant? [Abstract]. *J R Soc Promot Health* 2007; 127(1): 45-6.