

Case Report

Large piece of terracotta foreign body embedded in the submandibular region for two years

Ankur Mukherjee¹, Indranil Sen², Sirshak Dutta³, Ramanuj Sinha⁴

Abstract:

An unusual case of a large piece of terracotta accidentally lodged in the neck and subsequently removed by operation 2 years later is reported. The novelty of this case lies in the facts that 1) a large terracotta foreign body lodged in the neck almost unnoticed for more than 2 years 2) route of entry of the foreign body to neck tissues was not by the more common route of perforation of aero-digestive tract from inside but piercing the neck from outside 3) the 2.5 cm object migrated to another site from apparent site of entry and 4) it was asymptomatic for 2 years despite being close to vital structures other than an inconspicuous cosmetic deformity.

Key words: Foreign body; neck; terracotta

Introduction:

Foreign bodies in the neck have been reported in literature quite extensively but almost all of them were an ingested foreign body penetrating upper aero-digestive tract^{1, 2}. In the few reports of embedded foreign

bodies penetrating from outside, they were removed soon after- as they were the consequences of accidental injury in a symptomatic patient, so specifically searched for^{3,4}. Foreign bodies embedded like this in the head-neck region for a long time are extremely rare⁵ and in none of the reported cases were these lodged close to vital structures.

Case report:

A 29-year-old female visited ENT-OPD with complains of a painless lump in left side of her neck. She noticed it 2 months back and it was non progressive. On examination there was an obvious oval smooth swelling 4x3 cm in size in the left submandibular region. It was a hard geometrical shape object on palpation with smooth surface. There was a 3 cm jagged scar over her chin about 4 cm away from the swelling (Figure 1).

1. RMO cum Clinical Tutor, Department of Otolaryngology, College of Medicine & JNM Hospital, Kalyani, Nadia, India.
2. Associate Professor, Department of Otolaryngology, R.G. Kar Medical College & Hospital, Kolkata, India.
3. Junior Resident, Department of Otolaryngology, R.G. Kar Medical College & Hospital, Kolkata, India.
4. Professor & HOD, Department of Otolaryngology, R.G. Kar Medical College & Hospital, Kolkata, India.

Address of Corresponding: Dr. Ankur Mukherjee, Quarter no. B9, JNM Hospital Doctors' Quarter, Kalyani, Nadia 741235, India.
Email: ankurdoc007@gmail.com

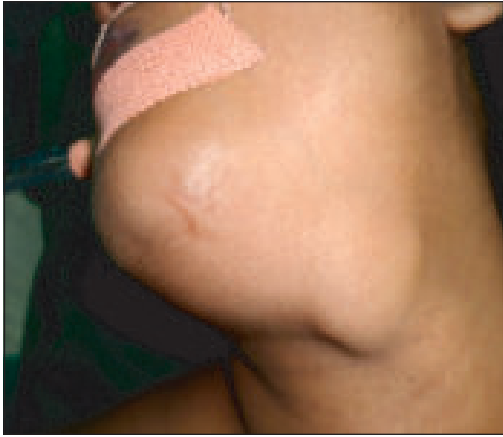

Figure 1: Clinical photograph of the patient.

On careful questioning she said this scar was of an accident two years back when a big flowerpot (a type of fireworks) exploded while she was lighting it during Diwali festival (Kali-Puja). The wound was stitched up in the local hospital. No relevant papers on investigation and treatment, pertaining to the accident was available. CT scan revealed a solid wedge shaped object close to the airway and anterior to the neuro-vascular sheath (Figure 2).

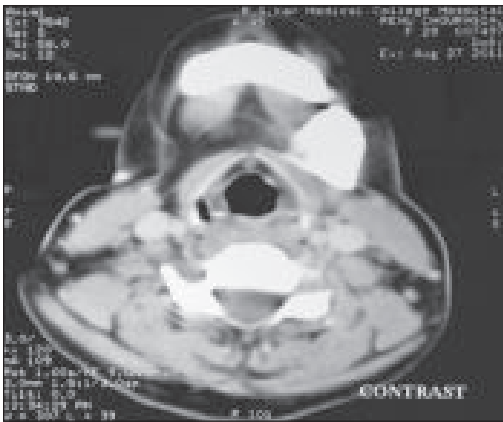


Figure 2: CT scan of neck axial section.

Neck was explored under general anaesthesia and a 2.5x2cm terracotta foreign body (Figure 3), surrounded by a fibrous capsule, was extracted. Evidently, this was the part of the

terracotta pot of the fireworks. Post operative recovery was uneventful.

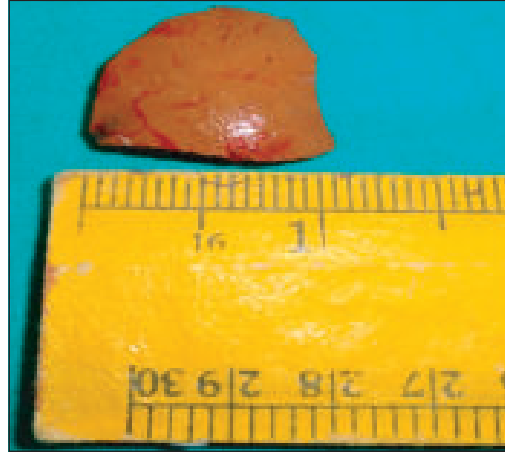

Figure 3: The terracotta foreign body 2.5x2cm after removal.

Discussion:

An embedded foreign body requires a high degree of clinical suspicion for diagnosis⁵, more so if it is asymptomatic. CT scan and plain radiographs help clinicians to locate them. Two radiographs taken at right angles to each other to locate the foreign body in three dimensions are very useful in a set up without CT scan facility⁶.

Why the patient didn't notice the foreign body earlier is a matter of speculation. Probably it migrated from the actual site of entry through the subcutaneous tissue plane around 4 cm away very slowly and patient ignored the initial discomfort. The splinter, being a hot sterile piece of terracotta did not invite any infection.

Conclusion:

This case stresses the importance of exploring every lacerated wound in the first place to look for foreign bodies. Otherwise there may be retained foreign bodies like in this patient. Finger is the most sensitive probe and will readily palpate the buried foreign body. This patient was unique with an asymptomatic

foreign body lying close to vital structures for a long time but not everybody is that fortunate.

References:

1. Pang KP, Pang YT. A rare case of a foreign body migration from the upper digestive tract to the subcutaneous neck. *Ear Nose Throat J* 2002; 81: 730 - 2.
2. Sreetharan SS, Prepagaran. N, Satwant S. Unusual migratory foreign body in the neck, *Singapore Med J* 2004; 45(10): 487 - 8.
3. Chin JTH, Davies SJ, Sandler JP. Retrieval of a metallic foreign body in the neck with a rare earth magnet. *J Accid Emerg Med* 2000; 17: 383 - 7
4. Ghosh LM, Pal PK. An unusual foreign body in neck. *Ind J Otolaryngol* 1989; 41(4): 150 - 1.
5. Vikram A, Mowar A, Kumar S. Wooden foreign body embedded in the zygomatic region for 2 years. *J Maxillofac. Oral Surg* 2011 online published on 6.5.2011 available in <http://www.springerlink.com/content/3528021122m11217/> Last accessed on 21.02.2012
6. Worth HM. Foreign Bodies. In Worth HM (Editor). *Principles and Practice of Oral Radiologic interpretation*, Chicago, Yearbook Medical Publishers 1963: 207-212.