

Case Report

Mid Facial Degloving Procedure: Managing A Case of Multiple Mid Face Fractures with Significant External Deformity

Akhil Chndra Biswas¹, Feroz Ahmed², ASM Lutfar Rahman³, Rajan Karmakar⁴, Farid Uddin Milki⁵, Ahmmad Taous⁶

Abstract

Purpose: The midfacial degloving approach (MFDA) is the primary option for surgical treatment of midface lesion. Usually most benign and malignant paranasal sinus (PNS) tumours are unilateral. So the classic MFDA does not fit for every case. Modifications of the classical MFDA are then tailored accordingly for surgical field exposure to achieve the goal.

MFDA was first suggested by Portmann in 1927, but the modern technique had its origin in 1974 with the report by Casson and colleagues. It was not until Conley and Price first suggested that the technique be used for the excision of neoplastic disease in 1979 that its use was fully realized. It can be of great benefit for the management of various lesions, mainly tumors, of the facial cavities, paranasal sinuses, nasopharynx, orbits, and central compartment of the anterior and middle cranial fossae, allowing adequate bilateral maxillary and lower nasal cavity exposure without cosmetic dysfunction.

Patients: A male patient of 20 years was admitted with history of faciomaxillary trauma having significant external deformity. Under GA open rhinoplasty and reduction & immobilization of fractured segments were done with adequate exposure of midface using midfacial degloving procedure.

Result: We have performed MFDA in one case only for the first time. Utilizing sublabial gingivobuccal incision, a complete transfixion incision, intercartilaginous incision with mucosal detachment of the pyriform aperture nasomaxillary skeleton along with zygoma were exposed adequately. No technical problems and no intraoperative complications related to the surgical procedure were encountered. Cosmetic outcome was also satisfactory.

Conclusion: Midfacial degloving can be considered as an excellent, useful, and safe approach for many lesions of the midface that has a low complication rate with excellent cosmetic outcomes. It provides excellent exposure to the midportion of the craniofacial skeleton, yet avoids external incisions and should be in every head and neck surgeon's armamentarium.

Keywords: midfacial degloving, midface deformity

-
1. Associate Professor, Dept of Otolaryngology - Head and Neck Surgery, Bangladesh Medical College & Hospital.
 2. Resident Assistant Professor, Dept of Otolaryngology - Head and Neck Surgery, Bangladesh Medical College & Hospital.
 3. Junior consultant, Dept of Otolaryngology-Head & Neck Surgery, Bangladesh Medical College Dhaka.
 4. Assistant Professor, Dept of Oral and maxillofacial Surgery, Bangladesh Dental College, Dhaka
 5. Consultant, Dept of Otolaryngology - Head and Neck Surgery, Bangladesh Medical College & Hospital.
 6. Assistant Professor, Dept of Otolaryngology - Head and Neck Surgery, Pabna Medical College, Pabna.

Address of Correspondence: Dr. Akhil Chandra Biswas, Associate Professor, Dept of Otolaryngology - Head and Neck Surgery, Bangladesh Medical College & Hospital, House # 33, Road # 14/A, Dhanmondi R/A, Dhaka - 1209, Bangladesh. Email: dr.akhilbiswas@ yahoo.com

Introduction

The mid facial degloving approach (MFDA) is the primary option for surgical treatment of mid face lesion. MFDA was first suggested by Portman in 1927. The modern technique had its origin in 1974 with the report by Casson and colleagues. But its use was fully realized in 1979 when Conley and Price first suggested the technique for the excision of neoplastic disease. It can be of great benefit for the management of various lesions, mainly tumors, of the facial cavities, paranasal sinuses, nasopharynx, orbits, and central compartment of the anterior and middle cranial fossae, midface fracture (naso-orbital-ethmoidal) allowing adequate bilateral maxillary and lower nasal cavity exposure without cosmetic dysfunction.

Case history

Ranjit Malaker 20 years, C/O : Amal Ch. Datta
Address: Kakchira, Pathorghata, Borguna
was admitted on 11 Jan. 2014 in Bangladesh Medical College & Hospital.



Fig.-1 :

Patient was completely well and active one month back. Unfortunately he experienced a tragic RTA. Primary resuscitative measure was taken in three other centers from primary to tertiary level but without definitive treatment (reduction of fracture).

We in BMCH received the patient as such.

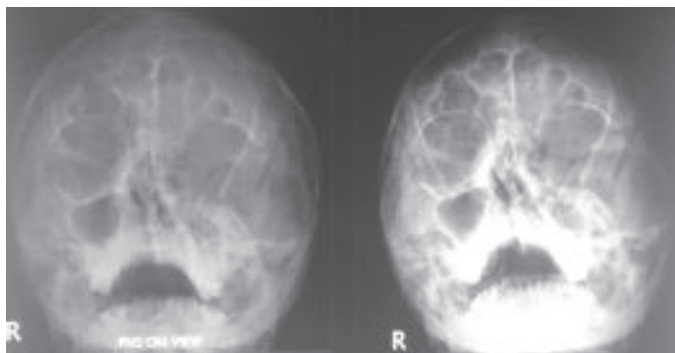


Fig.-2:

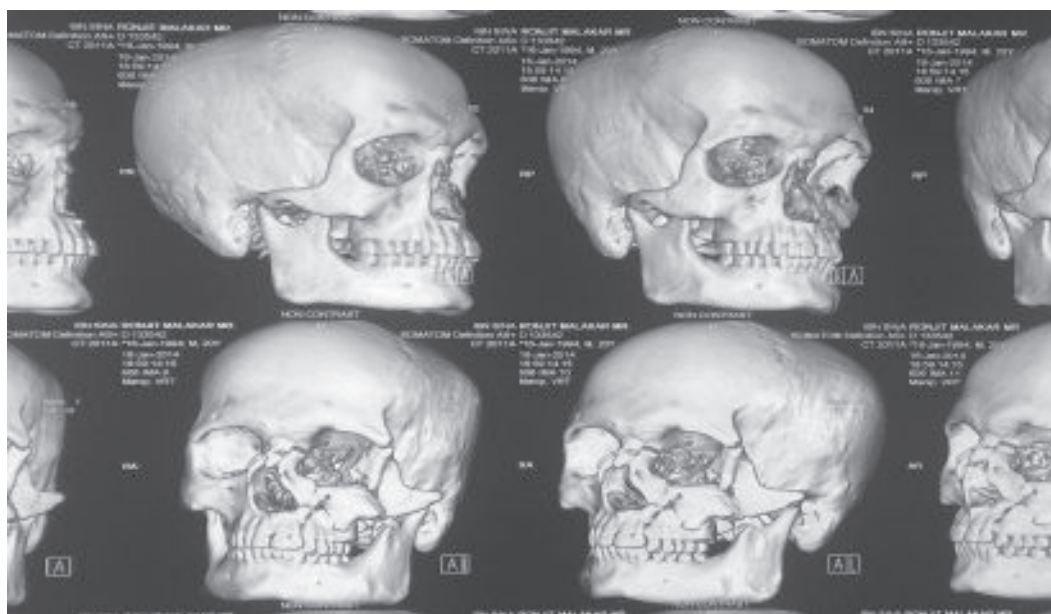
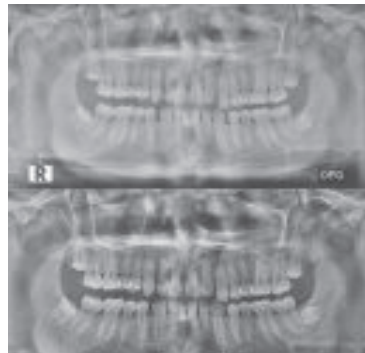
- Patient was clinically assessed and planned for surgical treatment aiming at reduction of fracture with fixation and stabilization to restore normal anatomical contour and to achieve normal physiology as much as possible.
- Nasal bone fracture with depression of root of the nose and gross external deviation towards right side with gross septal deviation.
- Left side of face was significantly depressed with fracture of anterior wall of maxilla from infraorbital margin up to alveolar ridge. Infraorbital margin was also depressed.
- Malar prominence was lost with zygomatic fracture and completely separated from all attachment with surrounding bone.

Complete blood count /RBS/Serum creatinine were within normal range, HBsAg was Positive. Other findings were, blood group A+, X-ray chest revealed nothing abnormal. X-ray PNS shows nasal bone fracture with gross septal deviation, fracture and depression of left infraorbital margin, depression of zygoma with fracture of all its attachment. OPG was normal. CT scan was also done with 3D image.

X-Ray PNS



OPG: Normal

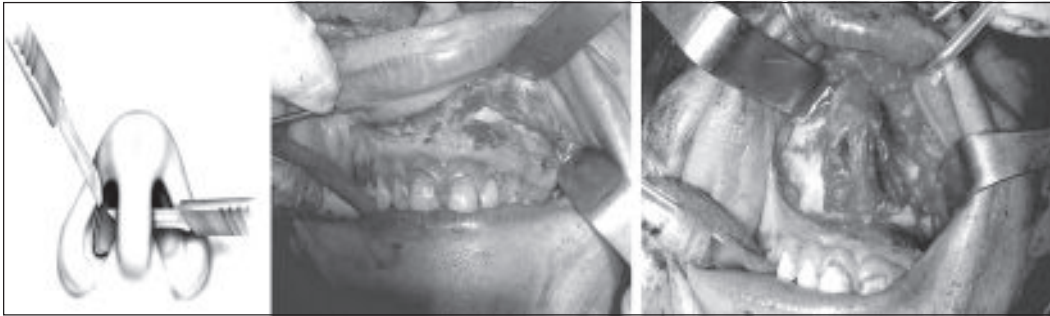


CT scan findings: Complex fractures with displaced edges started at the nasal bridge, extends laterally along the medial wall of the left orbit and then inferiorly along the inferior and then lateral wall of the left orbit, through the walls of maxillary sinus, hard palate, then posteriorly through alveolar process of maxilla into the pterygoid plates on the left side. Comminuted fractures also noted in zygomatic bone and zygomatic arch on left side. Fracture with inferior displacement of left orbital floor. Left retrobulbar fat is herniated and entrapped within fracture posteriorly. Nasal septum also fractured and deviated to the right.

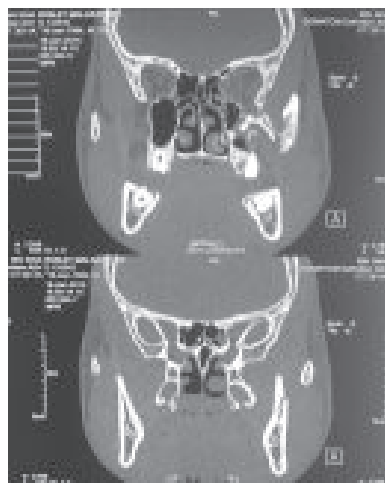

Figure showing the nasal incisions made in MFDA

Sub labial gingivo buccal incision



Post-operative appearance after 1 year:



Management

The patient was operated on 25-01-2014 utilizing sublabial gingivobuccal incision, a complete transfixion incision, intercartilaginous incision with mucosal detachment of the pyriform aperture facial flap was elevated upward upto frontonasal suture and nasomaxillary skeleton along with zygoma were exposed adequately with part of medial, inferior and lateral wall of orbit exposed extending laterally upto the beginning of the zygomatic arch. Old malunited fracture- nasal bone, infraorbital margin, zygomatic bone and ant wall of maxilla was evaluated preoperatively.

Refracture, reduction & stabilisation by miniplate fixation was done satisfactorily along with open rhinoplasty and septal deformity correction.

Discussion

Lateral rhinotomy/ Weber Ferguson are traditional approaches for nasal cavity and paranasal sinus tumor surgeries. This approach provides an excellent surgical exposure; notwithstanding, even with such advantage, its use is limited, because it leaves a prominent scar on the face. The degloving approach was first described in 1974, by Casson et al.¹ and has become very popular because of its major advantages of avoiding facial incisions and providing bilateral exposure of the nasal cavity. Thus, the mid-facial degloving approach has been used as a first option for medial maxillectomy, radical maxillectomy and non-complicated cranio-facial surgeries⁴⁻⁶.

Some changes to the degloving approach have been described, in order to avoid vestibular stenosis, which is the most frequent and significant complication⁷.

The standard procedure comprises an extensive gengivobuccal incision, a transfixating septal incision, an intercartilaginous incision and an incision in the nostril. The vestibular stenosis occurs as a consequence of the circumferential incision that is made in the nasal vestibule during the procedure.

Midfacial degloving was used as an approach in 14 patients to correct post-traumatic deformities in the midface. In eight patients, deformities in the naso-orbito-ethmoid region were corrected. In one patient, a midface fracture (Le Fort II/III) was reconstructed after midfacial degloving. There were no postoperative complications such as stenosis of the nasal aperture or disturbances of the mimic musculature. Midfacial degloving offers good exposure, specially of the central part of the midface, without leaving an external scar. It is useful for reconstructive procedures in patients after midface trauma.⁸

It is known that one of the inconveniences of the type of surgery under study is that it takes longer than its endoscopic counterpart, and the latter is a feasible and very much efficient alternative for the treatment of nasal cavity tumors in their initial stage, because it is less aggressive and brings less complications to the patient's post-op recovery. Notwithstanding, considering larger lesions, even if benign, the endoscopic approach is not adequate.

The MFD approach was used to access naso-orbital-ethmoidal (NOE) and concomitant midfacial fractures for repair in 9 patients with facial trauma.³ Functional and cosmetic results were assessed during follow-up with serial physical examinations and

postreduction films. No significant technical problems were encountered in the treatment of NOE and concomitant fractures. Physical examination and imaging studies showed adequate reduction in all patients, and all patients were satisfied with their short- and long-term functional and cosmetic results.³

In spite of some inconvenient points, degloving is efficient in the treatment of extensive lesions involving the nasal cavity and paranasal sinuses with the advantage of not leaving facial scars.

Conclusion:

Surgical exposure was very much adequate in our case to deal with whole of the midface skeleton with almost no surgical or cosmetic complications. From the perspective of managing this case it can be appreciated that the MFDA is an appropriate procedure to handle any kind of midface lesion like benign and malignant sinonasal tumours. With some modification midline or paramedian skull base lesion can also be addressed. Surgeon's viewing angle and control over lesional dissection is better with this approach avoiding any facial scar. Midfacial degloving can be considered as an excellent, useful, and safe approach for many lesions of the midface that has a low complication rate with excellent cosmetic outcomes. MFDA should be considered an important armamentarium by every head-neck surgeon.

We may conclude that the degloving approach to resect sinonasal tumors or to deal with mid face fracture is effective and bears the advantages of broad surgical exposure, excellent cosmetic results, very low post-operative complication rates.

References

1. Jeon SY, Jeong JH, Kim HS, Seong K, Kim JP. Hemifacial degloving for medial maxillectomy: a modification of midfacial

- degloving approach. *Laryngoscope* 2003; 113(4):754-6.
2. Casson PR, Bonnano PC, Converse JM. The midfacial degloving procedure. *Plast Reconst Surg* 1974;53:102-3.
3. Cultrara A, Turk J, Har-El G. Midfacial Degloving Approach For repair of Naso-orbital-ethmoid And Midfacial Fractures. *Plast Reconst Surg* 2004;6(2):133-5.
4. Maniglia AJ. Indications and techniques of midfacial degloving. *Arch Otolaryngol Head and Neck Surg* 1986;112:750-2.
5. Price JC, Holliday MJ, Johns MR, Kennedy DW, Richtsmeier WJ, Mattox DE. The versatile midface degloving approach. *Laryngoscope* 1988;98: 291-5.
6. Maniglia AJ, Phillips DA. Midfacial degloving for management of nasal, sinus and skull-base neoplasm. *Otolaryngol Clin North Am* 1995; 28: 1127-43.
7. Buchwald C, Bounding P, Kirby B, Falleutin E. Modified midfacial degloving: a practical approach to extensive bilateral benign tumors of the nasal cavity and paranasal sinuses. *Rhinology* 1995;33:39-42.
8. Arnulf Baumann , Rolf Ewers. Midfacial degloving approach for repair of naso-orbital- ethmoid and midfacial fractures. DOI: <http://dx.doi.org/10.1054/ijom.2001.0106>.