

## Case Report

---

# Cervical Vagal Schwannoma: A Case Report

Shouvanik Satpathy<sup>1</sup> Goutam Mondal<sup>2</sup> Anup Kumar Bhowmick<sup>3</sup> Aniruddha Dam<sup>4</sup>

### Abstract

*Cervical vagal schwannomas are rare, slow growing tumours usually occur in patients between thirty and fifty years of age with no sex related predisposition. They are usually asymptomatic benign lesion and complete surgical resection with preservation of neural pathway, whenever possible is the treatment of choice.*

**Key words:** Vagus nerve, benign tumour, schwannomas

### Introduction

Cervical vagal schwannomas are rare, slow growing tumours usually reported to occur in patients between thirty and fifty years of age with no sex related predisposition<sup>2,5,8-11</sup>.

They are usually asymptomatic benign lesion and complete surgical resection with preservation of neural pathway, whenever possible is the treatment of choice<sup>3,4</sup>.

Imaging plays a central role in diagnosing vagal schwannomas.

1. Senior Resident, Dept. of ENT and Head Neck Oncology, Chittaranjan National cancer Institute, West Bengal, India, PIN-700026
2. Associate Professor & Head, Department ENT and Head Neck Oncology, Chittaranjan National cancer Institute, West Bengal, India, PIN- 700026
3. Associate Professor, Department ENT and Head Neck Oncology, Chittaranjan National cancer Institute, West Bengal, India, PIN-700026
4. Associate Professor & Head, Department of Pathology, Chittaranjan National cancer Institute, West Bengal, India, PIN- 700026

**Address of Correspondence:** Dr. Shouvanik Satpathy, Senior Resident, Dept. of ENT and Head Neck Oncology, Chittaranjan National cancer Institute, West Bengal, India, PIN- 700026

### Case report

A fifty years old female, of lower socio-economic status, house wife came to our institute with complaints of a palpable, progressive right sided neck swelling for last nine years.

There was no history of dysphagia, dyspnoea, haemoptysis, change of voice, fever or night sweat.

There was no other specific history in the past.

### Physical examination

revealed a firm, smooth surfaced mass in right side of neck, deep to the sternocleidomastoid muscle in the upper and mid cervical region, measuring 7cm× 5cm, horizontally but restricted in vertical direction.

The concerned mass was nontender, nonpulsatile, without any thrill.

The Right carotid artery was displaced anteriorly.

On auscultation no bruit was heard.

In the oral cavity a smooth bulging was seen over right lateral and part of posterior pharyngeal wall pushing right tonsil anteriorly.

On laryngoscopy with 70 degree endoscope the bulging was extending downwards upto laryngeal inlet, and the right vocal cord was

fixed in cadaveric position which was partially compensated by the left vocal cord.

### Ultrasonography

of neck with Doppler study showed a hypoechoic, encapsulated mass with cystic component of 6cm× 4 cm size in the region of posterolateral aspect of the right common carotid artery, between the right common carotid artery and the right internal jugular vein.

Serosa of the right common carotid artery was involved by the mass.

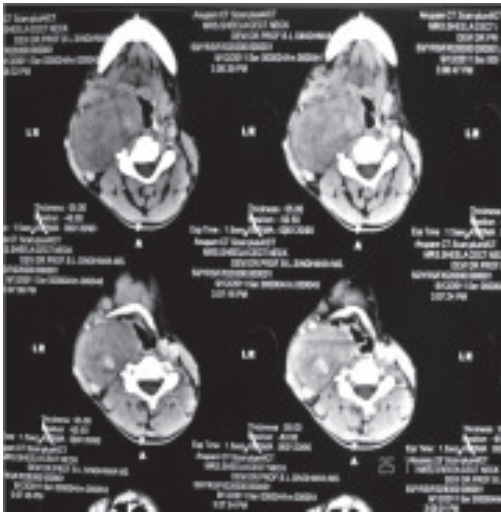
Colour flow was normal on Doppler study.

**USG guided FNAC** was taken from the mass and showed bundles of spindle cells embedded in collagen matrix.

There was no significant nuclear atypia and an impression of benign nerve cell tumour either schwannoma or paraganglioma was made.

### Contrast enhanced CT scan and MRI

neck revealed a large mass in the right carotid space between the right common carotid artery and the right internal jugular vein with extension and displacement of surrounding structures, suggesting vagal paraganglioma or vagal schwannoma as a close possibility [Fig-1].



**Fig.-1:** Contrast enhanced CT scan of neck

The patient then underwent surgery with complete excision of mass.

Cervical incision was given along the natural skin crease anterior to the sternocleidomastoid muscle and the dissection proceeded beneath the muscle.

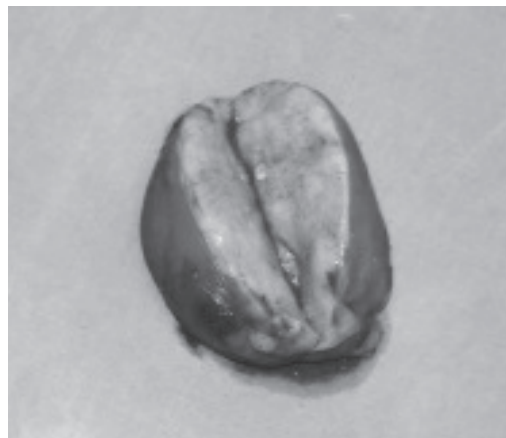
A yellowish white ovoid shaped mass was found measuring 6cm×4cm between the right common carotid artery and the right internal jugular vein which was shifted outwards.

Both superior and inferior end of the mass appeared in continuity with the nerve.

Since an adequate dissection plane could not be achieved between the mass and the right vagus nerve it was impossible to dissect the splayed nerve trunk off the tumour.

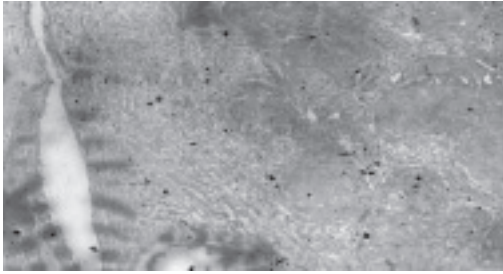
The tumour was resected “en block”.

**On cutting the specimen** whitish fleshy tissue was seen without any cavitation. [Fig-2].



**Fig-2:** Cut section of the specimen

**Histopathological examination**( under 40× magnification) showed encapsulated spindle cell tumour with frequent Verocay bodies alternation with Antoni B type areas.[Fig-3]



**Fig-3:** *microscopic appearance*

### Discussion

Schwannomas are rare peripheral nerve tumours; about one third of these cases occur in the head and neck region<sup>1</sup>.

Clinically, they present as asymptomatic slow-growing lateral neck masses that can be palpated along the medial border of the sternocleidomastoid muscle.

Pre-operative diagnosis of schwannoma is difficult because many vagal schwannomas do not present with neurological deficits.

Several differential diagnoses for vagal paraganglioma of the neck may be considered, like branchial cleft cyst, malignant lymphoma, metastatic cervical lymphadenopathy<sup>2</sup>.

Our case is reported because its rarity and its presentation with classical symptoms of vagal schwannoma.

When symptoms are present, hoarseness is the most common.

Occasionally, a paroxysmal cough may be produced on palpating the mass. This is a clinical sign, unique to vagal schwannoma.

Presence of this sign, associated with a mass located along the medial border of the sternocleidomastoid muscle, should make clinicians suspicious of vagal nerve sheath tumours<sup>[1,3-5]</sup>.

The usefulness of FNAC is still controversial.

The majority of authors do not recommend open or needle biopsy for these masses<sup>2</sup>.

In our case, a FNAC was performed which suggested the possibility of vagal schwannoma or paraganglioma.

There is general agreement concerning the great value of MRI in the pre-operative work-up as it is helpful in diagnosis and in evaluating the extent and the relationship of the tumour with the jugular vein and the carotid artery.

On MRI vagal schwannoma frequently appears as a well-circumscribed mass lying between the internal jugular vein and the carotid artery.

As reported by Furukawa et al.<sup>6,7</sup>, MRI findings are also useful to differentiate pre-operatively between schwannoma of the vagus nerve and schwannoma of the cervical sympathetic chain.

The vagal schwannomas, in fact, displace the internal jugular vein laterally and the carotid artery medially, whereas schwannomas from the cervical sympathetic chain displace both the carotid artery and the jugular vein outwards without separating them<sup>6-10</sup>.

Treatment of vagal nerve tumours is complete surgical excision.

At surgery, these tumours appear as yellowish-white, well-circumscribed masses.

Dissection of the tumour from the vagus with preservation of the neural pathway should be the primary aim of surgical treatment for these tumours.

Incomplete treatment, such as open biopsy, should be avoided, since it makes definitive excision of the tumour much more difficult.

If it is impossible to find an adequate plane and is technically difficult to preserve the integrity of the nerve trunk, the involved segment may be resected and an end-to-end anastomosis performed using microsurgical techniques<sup>3</sup>.

In our case as there was complete vocal cord paralysis preoperatively, the nerve anastomosis was not attempted.

The reported incidence of pre-operative vocal cord paralysis is about 12%.

Therefore, pre-operative assessment of vocal cord mobility should be strongly recommended.

As the nerve sheath tumour of neck is very rare, pre-operative suspicion is very important, and the patient, and the patient's family, should be informed about the possible post-operative neurological complications which is reported in 85% of cases in literature [ 3, 11];

In the presence of post-operative vocal cord palsy, an aggressive voice therapy, for vocal cord compensation, should be started soon after surgery.

#### References

1. Chang SC, Schi YM. Neurilemmoma of the vagus nerve: a case report and brief literature review. *Laryngoscope* 1984; 94: 946-9.
2. Colreavy MP, Lacy PD, Hughes J, Bouchier-Hayes D, Brennan P, O'Dwyer AJ, et al. Head and neck schwannomas – a 10-year review. *J Laryngol Otol* 2000; 114: 119-24.
3. Ford LC, Cruz RM, Rumore GJ, Klein J. Cervical cystic schwannoma of the vagus nerve: diagnostic and surgical challenge. *J Otolaryngol* 2003;32:61-3.
4. Fujino K, Shinohara K, Aoki M, Hashimoto K, Omori K. Intracapsular enucleation of vagus nerve-originated tumours for preservation of neural function. *Otolaryngol Head Neck Surg* 2000; 123: 334-6.
5. Gilmer-Hill HS, Kline DG. Neurogenic tumours of the cervical vagus nerve: report of four cases and review of the literature. *Neurosurgery* 2000;46:1498-503.
6. Furukawa M, Furukawa MK, Katoh K, Tsukuda M. Differentiation between schwannoma of the vagus nerve and schwannoma of the cervical sympathetic chain by imaging diagnosis. *Laryngoscope* 1996;106:1548-52.
7. Saito DM, Glastonbury CM, El-Sayed I, Eisele DW. Para-pharyngeal space schwannomas. Preoperative imaging determination of the nerve of origin. *Arch Otolaryngol Head Neck Surg* 2007;133:662-7.
8. Green JD Jr, Olsen KD, De Santo LW, Scheithauer BW. Neoplasm of the vagus nerve. *Laryngoscope* 1988;98:648-54.
9. Leu YS, Chang KC. Extracranial head and neck schwannomas: A review of 8 years experience. *Acta Otolaryngol* 2002; 122: 435-7.
10. Park CS, Suh KW, Kim CK. Neurilemmomas of the cervical vagus nerve. *Head Neck* 1991;15:439-41.
11. St Pierre S, Theriault R, Leclerc JE. Schwannomas of the vagus nerve in the head and neck. *J Otolaryngol* 1985;14:167-70.