

Case Report

Embryonal Rhabdomyosarcoma: A Case Report

Muntasir Mahbub¹, Nabila Mannan¹, Md. Mazharul Shaheen², Manash Ranjan Chakraborti², AKM Shaifuddin⁴, Shahjahan Kabir⁵, KM Mamun Murshed⁵, Mahmudul Hassan³, Khabiruddin Ahmed³

Abstract

Rhabdomyosarcoma is the most common soft tissue sarcoma of childhood and adolescence. There are four histological types and among them the embryonic types are the most common. It can occur in any anatomic location, although when occurring in the head and neck region, it has an affinity to invade the cranial cavity. Patient was a 5 years old boy who was admitted with the complaints of pain and discharge from the ear, swelling on left side of the upper neck, and mastoid region and a fleshy mass protruding from the ear canal. The mass was confirmed to be Embryonal Rhabdomyosarcoma on histopathology. CT scan of the Head-Neck region, showed extension of the mass into infra-temporal fossa and in the mastoid antrum. After complete excision, the patient was referred to oncology deptt for consultation. The chemotherapy schedule comprised of Vincristine and Dactinomycine for 9-12 cycles. Otolaryngologists need to be aware of this rare condition as it may mimic the symptoms of CSOM or nasal polyp. And also long term followup is needed since recurrence can present several years after initial treatment.

Key Words: Rhabdomyosarcoma, Embryonal tumors, Childhood Head-Neck Tumors

Introduction

Rhabdomyosarcoma is the most common soft tissue sarcoma of childhood and adolescence. It arises from the embryonic muscles tissue or the pluripotential mesenchyme. It is a malignant skeletal

muscle tumour and histologically it resembles the normal foetal skeletal muscle before innervation. The benign variant, rhabdomyoma, is very rare.

There are four histological types - embryonic, alveolar, botryoidal and pleomorphic¹. Approximately 60% of all newly diagnosed rhabdomyosarcomas are of embryonal type, and usually happen in younger children. The alveolar type is less common and found in older children.

Rhabdomyosarcoma accounts for about 60 % of all sarcomas in the paediatric population and 4–8 % of all paediatric cancers. Nearly half of these tumours occur in children under the age of 5. Males are affected 1.5 times more often than females.²

40% of all Rhabdomyosarcoma occur in the head and neck region. It can also involve the extremities and genitourinary tract. It arises

1. Honorary Medical Officer, Deptt of ENT and Head-Neck Surgery, Shaheed Suhrawardy Medical College Hospital (ShSMCH)
2. Associate Professor, Deptt of ENT and Head-Neck Surgery, ShSMCH
3. Professor, Deptt of ENT and Head-Neck Surgery, ShSMCH
4. Junior Consultant, Deptt of ENT and Head-Neck Surgery, ShSMCH
5. Assistant Professor, Deptt of ENT and Head-Neck Surgery, ShSMCH

Address of Correspondence: Dr. Muntasir Mahbub, Honorary Medical Officer, Deptt of ENT and Head-Neck Surgery, Shaheed Suhrawardy Medical College Hospital (ShSMCH)

in three main head and neck sites¹– orbit, parameningeal sites (nasopharynx, nasal fossa, para- nasal sinuses, infra-temporal fossa, ptrygoid fossa, middle ear and mastoid) and non-parameningeal sites (scalp, face, parotid, oral cavity, oropharynx, larynx and neck).

Those arising at parameningeal sites have an affinity to invade the cranial cavity via basal skull foramina and are consequently associated with the worst prognosis.

Nasal or paranasal rhabdomyosarcoma may present with a gradual onset of nasal obstruction and bloody nasal discharge. Tumours within the ear may present with symptoms of bloody discharge and persistent otalgia, despite treatment. A polypoid mass may be visible in the ear canal or nasal cavity.²

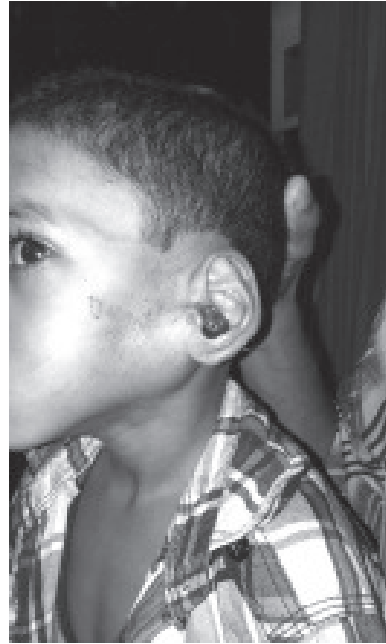Although most cases are sporadic, there are some risk factors, which include: neurofibromatosis, Li-Fraumeni syndrome, Costello syndrome, Noonan syndrome, Beckwith-Wiedemann syndrome, and parental use of cocaine or marijuana. ²

Case Report

Our patient, Master Shamim, 5 years of age, was admitted in the ENT and HNS dept of Shaheed Suhrawardy Medical College Hospital, with the complaints of Pain, Itching and discharge from left ear for 4 months, swelling of the left side of the upper neck, face and mastoid region for 3 months and protrusion of a fleshy mass from the ear canal for 2 months.

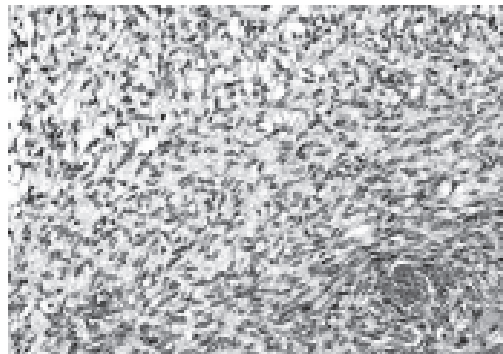
The swelling was tender and warm. Serosanguinous discharge came out from the ear canal on pressing over the swelling.

A biopsy from the protruding aural mass was already taken before his admission; histopathology report revealed the mass to be an Embryonal Rhabdomyosarcoma.



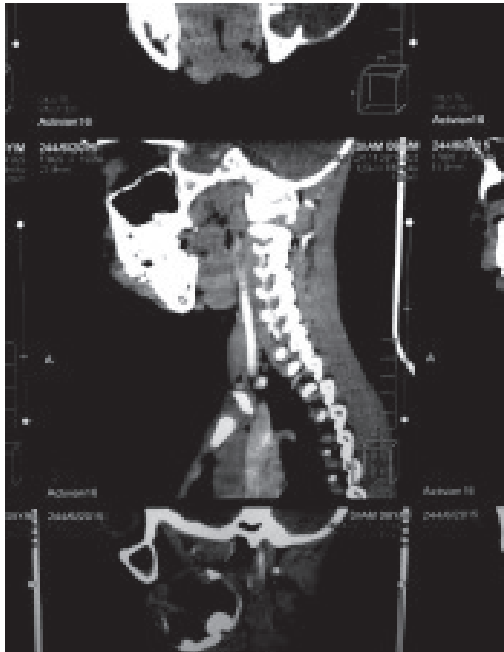
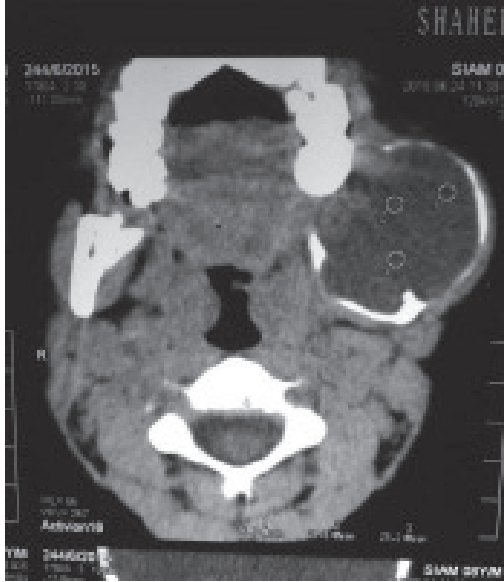
A CT scan of the Head-Neck region was done, which showed the extension of the mass into the temporal and infra-temporal fossa and in the mastoid antrum. The tumor pressed over the base of the skull but it didn't penetrate into the brain.

During surgery, an extended post-auricular incision was given, starting from 3 cm behind the pinna, went vertically downwards and then extended slightly forward into the neck. The facial nerve was intimately incorporated into the mass and had to be sacrificed for proper clearance.



The mass obtained through surgery also revealed to be Embryonal rhabdomyosarcoma on histopathology.

Postoperative chemotherapy schedule comprised of bolus doses of Vincristine and Dactinomycine for 9-12 cycles, which was prescribed by the oncology deptt.



Discussion

Assessment of such a case should include a thorough examination of the upper respiratory tract and head and neck region including the cranial nerves. Flexible nasoendoscopy may be employed in the clinic.

Diagnosis is usually confirmed on biopsy and histopathology. MRI is used to evaluate the primary lesion and to rule out metastatic disease. CT scan may be a useful to determine bony erosion of the skull base and it is the best method to assess the chest for metastasis. In cases of parameningeal rhabdomyosarcoma a cytological examination of CSF may be needed.

There are three commonly used staging systems for rhabdomyosarcoma:³

- I. IRS (Intergroup Rhabdomyosarcoma Study)
- II. TNM, and
- III. Clinical (surgico-pathologic),

IRS clinical grouping is particularly useful because previous studies have indicated comparatively favourable and unfavourable prognostic groups.

The IRS classification includes four groups, based on tumour resectability.³

- I. Group 4 - distant metastatic disease present at onset.

Surgicopathologic criteria including local extension, regional and distant metastases are used to stage rhabdomyosarcoma. When the specific site of origin is incorporated into the TNM staging system as it correlates well with the outcome.

Since the establishment of the IRS (Intergroup Rhabdomyosarcoma Study) Committee in 1972, a multi-modality approach has been adopted in the management of rhabdomyosarcoma. Surgery followed by combination chemotherapy with or without

adjuvant radiotherapy is commonly used as primary treatment for rhabdomyosarcoma.

Complete surgical excision remains a critical component of treatment for rhabdomyosarcoma, however radical surgery is frequently not possible due to close proximity of the tumours to vital structures and also due to the possibility of significant postoperative cosmetic and functional morbidity.

The prognosis for this tumour used to be extremely poor (approximately 10 % of patients survived five years) but over the last 30 years survival rates have increased dramatically (over 80 %), (4) particularly with the introduction of multi-modality therapy in which surgery, multi-agent chemotherapy and radiotherapy have been combined. With more advanced tumours the prognosis is still relatively poor and in those with meningeal involvement the five-year survival is less than 10 %. Younger patients tend to have a more favourable prognosis, for unknown reasons

Conclusion

Although rare in general, the incidence of rhabdomyosarcoma isn't insignificant in the paediatric age group. Its propensity to invade

the cranial cavity along with the metastatic potential makes it a troublesome clinical entity to deal with. Otolaryngologists need to be aware of this condition as initially the tumor may mimic the symptoms of CSOM or nasal polyp, which may sometimes misguide them. So proper preoperative evaluation, preoperative assessment with complete resection, Post-operative chemoradiation, and long term followup is the mainstay of management of this condition.

References

1. Chan A K, Hartley A, Grimer R J, Rare cancers of the head and neck, Watkinson J C, Gilbert R W, Stell Marans Textbook of Head and Neck Surgery and Oncology, 5th ed, Page 801, Hodder and Stoughton Ltd; 2012
2. Macgregor F, Tumours of the head and neck in childhood, Gleeson M, Clarke R, Scott-Brown's Otorhinolaryngology: Head and Neck Surgery, Edition 7th, Volume 1, Page 1255-1258, Edward Arnold (Publishers) Ltd; 2008
3. Yee KW, Embryonal Rhabdomyosarcoma in a Young Boy. Mcgill J Med. 2007 Jan; 10 1: 16–19