

Original Article

Optic Nerve Decompression in Craniofacial Fibrous Dysplasia Involving Optic Canal: An Experience at AIIMS, New Delhi

Bashir Ahmed¹, Alok Thakkar², SM Nurul Irfan³

Abstract

Background: Gradual progression of craniofacial fibrous dysplasia frequently involves sphenoid and ethmoid bone results encasement of optic canal which leads to visual impairment to complete blindness

Methods: Retrospective study was carried out at All India Institute of Medical Sciences on hospital records of 16 cases of craniofacial fibrous dysplasia operated for optic canal involvement with or without visual impairment with an objective to discuss about the indications, suitable timing and outcome of optic nerve decompression in cases of optic canal involvement.

Results: Out of 16 cases, 56.25% were female with mean age 13.06 years. 15 patients had Idiopathic Fibrous dysplasia and 01 had Cranio-metaphyseal dysplasia. 62.5% were polyostotic and 37.5% were monostotic with 62.5% of optic neuropathy. Bilateral lesion occurred in 03 patients. Optic nerve decompression was done for curative treatment in 62.5% and for prophylactic in 37.5% cases. Post-operative visual improvement occurred in 90% patients and in no patient vision was deteriorated.

Conclusion: Prophylactic decompression can be carried out in expert hand for involvement of optic canal in craniofacial fibrous dysplasia for prevention of future visual impairment.

Keywords: Fibrous dysplasia; optic canal; optic neuropathy; optic nerve decompression;

Introduction

Fibrous dysplasia(FD) is a benign, slowly progressive bone disorder of unknown aetiology where normal bone is replaced by various degrees of fibrous tissue and

immature woven bone¹. It presents in childhood or early adolescent^{2,3} in which progression typically arrests at puberty⁴. FD is caused by somatic activating mutations in the subunit of the stimulatory G protein encoded by the gene GNAS á^{5,6}. It appears to arise from a perturbation in the mesenchymal precursor of bone, producing a defect in osteoblastic differentiation and subsequent maturation of bone⁷

It is a relatively uncommon, nonfamilial congenital disorder of bone³ and the disease usually manifest before 3rd decade of life⁸. Patient may present with involvement of

-
1. Classified Specialist in Otolaryngology, Combined Military Hospital, Dhaka, Bangladesh
 2. Professor, Department of Otolaryngology and Head –Neck Surgery, All India Institute of Medical Sciences, New Delhi
 3. Medical Officer, Bangladesh Airforce, Dhaka

Address of Correspondence: Lt Col Md Bashir Ahmed, Classified Specialist in Otolaryngology, Combined Military Hospital, Dhaka, Bangladesh

single bone (monostotic; MFD), multiple bones (polyostotic; PFD) or McCune-Albright Syndrome(MAS). MAS has been classically defined as a triad of PFD, café-au-lait skin macules and endocrinopathies (precocious puberty, hyperthyroidism or acromegaly)⁹. Malignant change may occur as osteosarcoma or other forms of sarcoma in less than 1% of cases of FD¹⁰.

Occasionally, in young children and pre-pubertal adolescents, the lesions may grow rapidly with cortical bone expansion and displacement of adjacent structures such as the eye and the teeth. It frequently affects anterior skull base and encase optic canal. Craniofacial fibrous dysplasia may develop within bone adjacent to the optic canal, grow gradually, and compress the optic nerve leading to visual disturbances^{3,11}. Optic canal involvement causes compression of optic nerve which results progressive venous congestion and subsequent intraneural oedema¹³. The cause of both acute and gradual loss of vision in patients with fibrous dysplasia remains unclear and the pathological course is unknown.

A clinical staging had been suggested by Barrionuevo et al²², for temporal bone involvement in accordance to the progression of the disease. Stage 1: latent or asymptomatic phase, where by the management is conservative with regular follow-up. Stage 2: symptomatic phase and stage 3: stage with complications²².

There is different opinion regarding prophylactic decompression of the optic nerve. However, when visual impairment begins it tends to be progressive^{1,12} and may continue after puberty¹³. Prophylactic decompression is sometimes performed based on the assumption that the risk of future optic neuropathy outweighs the risks of the operation which include postoperative blindness^{13,14}. Use of high speed suction

drill, continuous irrigation, ultrasonic bone curette has reduced the risk of postoperative visual loss recently.

There is inadequacy of study regarding the absolute indications, timing and outcome of surgery in cases of optic canal involvement in FD. The objective of the study is to discuss about the indications, suitable timing and outcome of optic nerve decompression in cases of optic canal involvement with or without features of optic nerve compression in fibrous dysplasia in light of our experience at All India Institute of Medical Sciences, New Delhi.

Methods

Retrospective study was carried out on hospital records at All India Institute of Medical Sciences, New Delhi operated for Craniofacial Fibrous Dysplasia between 1998 to 2015. 16 patients were included in this study who were clinically diagnosed and radiologically confirmed cases having involvement of optic canal. Patients who had no features of optic nerve compression but the lesion has involved the optic canal in CT scan were also included. Diagnosis was confirmed by histopathology in all cases. Skull base FD without involvement of optic canal, unfit for general anaesthesia and unwilling for operation were excluded from this study.

All cases were evaluated by neuro-ophthalmologist for visual analysis. Visual acuity by Snellen's chart test, visual field by Goldman perimeter in cases of visual impairment (equal to or better than 1/60) and colour vision by Ishihara colour plate were carried out. Fundoscopy were done in all cases of visual impairment. High resolution CT scan with minimum 2mm thickness for optic nerve and optic canal were carried out. All patient underwent testing of all relevant endocrine axes. Musculoskeletal radiology

was considered only for suspected cases. Follow up carried out 3 monthly intervals in initial post-operative period, followed by yearly basis. During follow up craniofacial, necessary radiological and ophthalmological evaluation was recorded.

During surgery, high speed drill with suction and irrigation were used for prevention of traumatic or thermal injury to optic nerve. Debulking or shaving and optic nerve decompression through trans ethmoidal route was the mainstay of all forms of surgery. Moore's incision, Moore's with lynch extension, Lateral Rhinotomy and modification of these incisions were used in external and combined approaches according to the extension of disease.

Results

16 patients with Craniofacial FD with or without visual impairment was operated for optic canal involvement over past 18 years. In 16 patients 19 optic nerve were decompressed. Among those 09 (56.25%) were female and 07(43.75%) were male. Age ranges from 05 years to 35 years with mean age 13. 12 out of 16 (75%) were 20 years or below and 4(25%) were above 20 years of age. 15 patients had Idiopathic FD and 01 had Cranio-metaphyseal dysplasia.

In regards of bone involvement 10 were polyostotic(62.5%) and 06(37.5%) were monostotic. In PFD 01 was associated with cranio-metaphyseal dysplasia. All patient presented with mild to moderate headache, 10(62.5%) with orbital and or periorbital pain with gradual visual impairment. Clinically 10(62.5%) had decreased visual acuity, 08(50%) had features of optic neuropathy at Fundoscopy, 09(56.25%) had proptosis, 07(43.75%) had facial swelling or deformity.

01 presented with mouth breathing, widely separated eye, torsional nystagmus and nasal deformity. Presenting symptoms are given in Table-I.

Table-I
Presenting symptoms

Gradual vision loss	: 10 (62.5%)
Proptosis	: 09 (56.25%)
Craniofacial swelling /	
Facial deformity	: 07 (43.75%)
Headache/periorbital pain	: 10 (62.5)
Skeletal deformity	: 01 (6.25%)
Nasal deformity	: 01 (62.5%)

Most commonly involved bones are Ethmoid 12(75%), Sphenoid 10(62.5%), Frontal 04(25%), Maxilla 03(18.75%), Temporal 01 (6.25%) and Parietal 01(6.25%). Bilateral lesion occurred in 03(18.75%) patients; 01 of whom had cranio-metaphyseal dysplasia with skeletal Erlemeyer's Flask deformity. The Cranio- metaphyseal dysplasia disease was extensive and completely encircled the optic nerve in both side. Optic canal diameter was 1.5mm in both side. The skull bones affected are shown in table-II.

In HRCT scan, all cases had optic canal involvement but optic nerve compression were present in 13 eyes in 10 patients (62.5%). These all patients presented with gradual visual impairment from a duration of 12 weeks to 12 months. 06 patients (37.5%) had no optic nerve compression due to narrowing of optic canal in HRCT scan and they also had no clinical features of it but dysplastic foci involved the optic canal and had potential risk of optic nerve compression in future.

Table-II
Diagnosis and bone involvement

Case no	Age	Sex	Diagnosis	Bones involvement
1	12	Female	Craniofacial FD	Lt Sphenoid and Ethmoid
2	16	Female	FD Ethmoid	Ethmoid
3	34	Male	FD Lt Ethmoid	Lt Sphenoid and Ethmoid
4	15	Male	Craniofacial FD	Rt Frontal and Sphenoid
5	8	Female	Craniofacial FD	Rt Ethmoid and Sphenoid
6	20	Female	Craniofacial FD	Rt Maxilla and sphenoid
7	26	Male	Ethmoid FD	Lt Ethmoid
8	22	Male	Craniofacial FD	Rt Sphenoid, Ethmoid, Frontal, Temporal and Maxilla
9	18	Male	Ethmoid FD	Ethmoid
10	35	Male	Ethmoid FD	Ethmoid
11	12	Female	Craniofacial FD	Bilateral Frontal and Sphenoid
12	18	Female	Bilateral Craniofacial FD	Rt Ethmoid, Sphenoid, Maxilla, Frontal and Temporal
13	7	Female	Rt Ethmoid FD	Rt Ethmoid
14	13	Female	Bilateral Sphenoid FD	Bilateral Sphenoid
15	13	Female	Sphenoid FD	Rt Sphenoid
16	5	Male	Cranial metaphyseal dysplasia	Bilateral Sphenoid, Ethmoid, Temporal and Parietal

Optic nerves were decompressed in all cases. Endoscopic approach was followed in 05, External approach by Lateral Rhinotomy in 09 and combined approach in 02 cases. Image guided navigation was utilized in all 2 combined approaches. Per operative CSF leak occurred in 01 case which was immediately closed by soft tissue graft and fibrin glue. He was also managed by lumbar drain, mannitol, antibiotic and Eptoin. During post-operative period vision improved in 11/13(84.6%) cases. In no cases

vision was deteriorated in post-operative period. 01 patient had PL-ve in Lt eye preoperatively; who had no improvement of vision in post-operative period in Lt eye. In 02 patients vision was restricted up to hand movement ; they had little improvement of vision after surgery. All 06 cases who underwent prophylactic optic nerve decompression had no vision changes during post-operative period. Surgical outcome and indications are shown in Table III.

Table-III
Visual outcome of Surgery

Case no	Approaches of Operation	Pre-operative visual acuity	Post-operative visual acuity	Indication for operation	Fundoscopy finding
1	External	Rt- 6/6, Lt- 6/36	Rt- 6/6, Lt- 6/18	Decreased Lt VA	Nil
2	External	Rt- 6/6, Lt- 6/6	Rt- 6/6, Lt- 6/6	Prophylactic	Nil
3	External	Rt- 6/6, Lt- 6/6	Rt- 6/6, Lt- 6/6	Prophylactic	Nil
4	External	Rt- FC 1m, Lt- 6/6	Rt- 6/36, Lt- 6/6	Rt optic neuropathy	Pale Rt optic disk
5	Endoscopic	Hand movement(HM) 50cm Rt, 6/6 Lt	Rt- 6/36, Lt- 6/6	Rt optic neuropathy	Pale Rt optic disk
6	External	Rt- 6/6, Lt- 6/6	Rt- 6/6, Lt- 6/6	Prophylactic	Nil
7	Endoscopic	Rt- 6/6, Lt- 6/36	Rt- 6/6, Lt- 6/18	Decreased Lt VA	Nil
8	Endoscopic	Rt- 6/60, Lt- 6/6	Rt- 6/36, Lt- 6/6	Rt optic neuropathy	Pale Rt optic disk
9	External	Rt- 6/6, Lt- 6/6	Rt- 6/6, Lt- 6/6	Prophylactic	Nil
10	Endoscopic	Rt- 6/6, Lt- 6/6	Rt- 6/6, Lt- 6/6	Prophylactic	Nil
11	External	Rt- 6/60, Lt- 6/6	Rt- 6/36, Lt- 6/6	Rt optic neuropathy	Pale Rt optic disk
12	External	Rt- PL+ve, Lt- 6/36	Rt- HM close to face, Lt- 6/18	Bilateral optic neuropathy	Bilateral pale optic disk
13	External	Rt- 6/6, Lt- 6/6	Rt- 6/6, Lt- 6/6	Prophylactic	Nil
14	Combined	Rt- 6/12, Lt- HM 3m and Counting Finger (CF) 1m	Rt- 6/9, Lt- CF 3m	Lt optic neuropathy	Pale Lt optic disk
15	Endoscopic	PL +ve Bilateral	PL +ve Bilateral (Subjective mild improved vision)	Bilateral optic neuropathy	Pale bilateral optic disk
16	Combined	PL +ve Rt, PL -ve Lt	Rt- PL +ve, Lt- PL -ve	Bilateral optic neuropathy	Pale bilateral optic disk

Discussion

FD is predominantly a disease of adolescent and early childhood. In MFD and PFD, progression of the lesions appears to taper off as the patient approaches to puberty. Although active disease is continued; symptoms into adulthood are uncommon¹⁶. Skull base FD can present from 4 years up to late age with an average age of 22 years and a female male ratio is 2:1. About 60% of which presents at below 20 years of age¹⁶. Our cases also presented at early age from 5 years and 75% of which presented below 20 years of age. There is no sex preference. MFD represents 70% of cases and most commonly affecting the ribs and femur, next common is craniofacial bones. PFD involve the long bones, skull, and cranial base. Of significance, in 50 to 100% of patients with the polyostotic form and in 10% with the

monostotic variant craniofacial involvement is present³. Sex prevalence of Female 56.25% and male 43.75% of our series correlates with series of Ricalde P et al³ but prevalence of MFD and PFD respectively 37.25% and 62.5% does not correlates; as only craniofacial FD with optic canal involvement are taken in our series.

Most commonly involved bones of skull base are ethmoid 70%: followed by sphenoid 43%, frontal 33% and Maxilla 29%¹⁶. Our patients are closer to same involvement of bones with 75% ethmoid, sphenoid 62.5%, frontal 25% and Maxilla 18.75%. FD appears to arise from a perturbation in the mesenchymal precursor of bone, producing a defect in osteoblastic differentiation and subsequent maturation of bone. Molecular biological findings have provided some insight of site of origin. One of the putative defects appears

to involve a missense mutation, which gives rise to an anomaly of intracellular signalling that produces increased cell proliferation and inappropriate cell differentiation, resulting in a disorganized fibrotic bone matrix¹. Additionally, increased interleukin-6 may also play a role in the development of fibrous dysplasia⁷.

Similar to other series, the most frequent ophthalmic sign was proptosis 62.5%, optic neuropathy 56.25%. It is recognised that compressive optic neuropathy does not always supervene, even with anatomical narrowing of the optic canal^{17,18}. It usually occurs in a chronic and progressive manner or may also manifest in an acute and impressive fashion. Visual impairment has been ascribed to a multitude of underlying pathological processes. One of these processes appears to involve progressive diminution of optic nerve venous drainage and, ultimately, retinal ischemia that develops due to optic nerve compression resulting from fibrous dysplasia-related optic canal stenosis. The arrangement of fibres within the optic nerve at the optic canal is such that the peripheral fibres run circumferentially along the periphery of the nerve, central vision may be preserved in cases in which there are peripheral visual field defects³. Other causes of ophthalmic signs include exophthalmos-induced optic nerve traction, sinus mucocoele formation, with increased intraorbital pressure, spontaneous haemorrhage, bone cyst formation, or rare vascular events¹¹.

CT scan accurately establishes the diagnosis and extent of bone involvement. Involvement of optic canals, orbital fissures, frontonasal ducts and osteomeatal complex can be best evaluated by CT scanning. CT characteristics of fibrous dysplasia, include expansion of the involved bone with heterogenous pattern of CT densities associated with scattered or confluent islands of bone formation. Exact evaluation of optic canal for canal dimension, site of foci, extent of nerve compression etc. can

be made by CT scan. Furthermore, CT scan can differentiate fibrous dysplasia from other osteodystrophies of the skull base including osteogenesis imperfecta, Paget's disease and osteopetrosis.

Ocular complications have been classified into primary and secondary processes². Primary complications include involvement of the frontal bone with proptosis; the skull base with extraocular muscle palsies and trigeminal neuralgia; the optic canal with visual loss and optic atrophy; the sphenoid bones with chiasmal compression; and the maxillary bone with epiphora. Secondary complications comprise malignant change, ossifying fibroma formation, and development of a mucocoele²⁰.

Optic nerve involvement in FD of Sphenoid bone may be about 50% to 90%¹¹. It may vary from partial to complete encasement. Up to 76% may cause bilateral involvement. Of these bilateral cases 75% may have complete circumferential encasement and 25% partial encasement and all the canals may be patent¹⁹. In a series Cuttler and colleagues²³ shows 100% involvement optic nerve in 87 patients with more than 50% encasement in 83% cases. In our series, we found 4 patients (25%) of bilateral optic canal involvement. Optic nerve involvement is also similar to Lee et al¹¹ series of 62.5%.

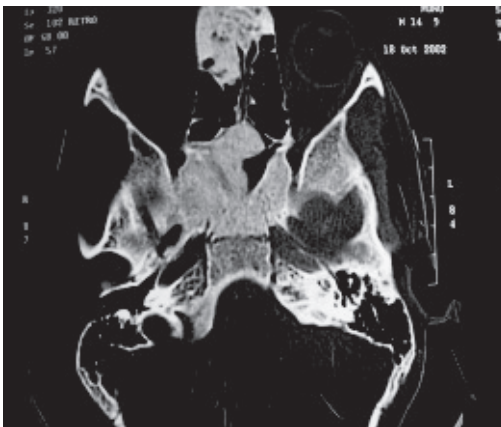The surgical treatment of fibrous dysplasia is based on two different approaches, conservative or radical. Conservative shaving or osseous contouring has been recommended by some authors. who maintained that periodic contouring could be performed until a static phase was reached, even if continued growth was observed after conservative treatment. However, interventions have become more aggressive as advances have been made in surgical techniques and now a day most authors are in favour of radical surgical therapy, which permits the complete removal of the lesion followed by immediate reconstruction²¹.

Role of optic nerve decompression in Craniofacial FD around the optic nerve in patients with normal vision is controversial as resection of dysplastic bone carries a risk of surgically induced visual loss. High risk of surgical injury in patients of sensitive compressed optic nerve is also reported²⁴. Meta-analysis by Moran et al²⁵ shows; 65% patients maintains static vision in long term follow up for surgical decompression of optic nerve in symptomatic and 87% in asymptomatic optic canal involvement. In our series, asymptomatic decompressed eyes have 100% static visual stability which is closer to Moran et al's series. It becomes possible due to modern equipment and surgeon's high expertise.

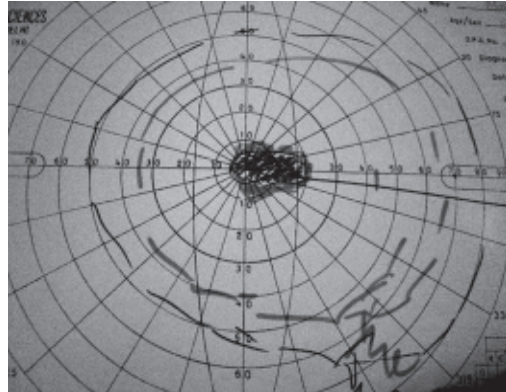
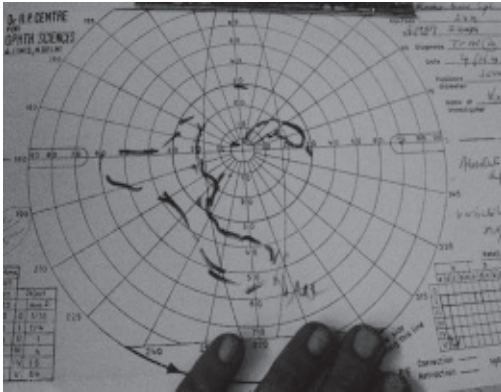
It's also a matter of debate for improvement of vision in cases of compressive optic neuropathy. Optic canal decompression surgery can be either therapeutic or prophylactic, the goal of such surgery is to maintain vision and must be balanced against the risk of postoperative visual loss. CT findings of encasement or constriction of the optic canal do not always correlate with the results of the neuro-ophthalmologic examination. Fibrous dysplasia should be managed according to the results of the clinical examination and that diagnostic imaging. All patients should be in

regular follow up for appropriate treatment. Prophylactic decompression of the optic nerve cannot be recommended on the basis of diagnostic imaging alone, since the results of such imaging do not correlate with loss of vision¹⁹.

We followed conservative approach, keeping considerations of maintenance of facial cosmetic similarity, functional improvement and maximum disease removal with the help of high speed drill, continuous irrigation and suction. We used navigator system where necessary. 19 optic nerves of 16 patients were decompressed. Among operated 16 cases no patient had any visual deterioration. Post-operative visual improvement occurred in 84.6%(11/13) optic neuropathy cases. Among this 01 had mild subjective improvement). 01 patient who had PL-ve in Lt eye; did not have any visual improvement. In cases of prophylactic surgery; no post-operative visual loss was also recorded. One of the case presented with gradual visual loss for one year. On examination, she had visual acuity in Lt eye 6/36 which improved in post-operative period up to 6/9. It indicates that decompression of optic nerve in compressive neuropathy improves the vision until preoperatively it become PL-ve.



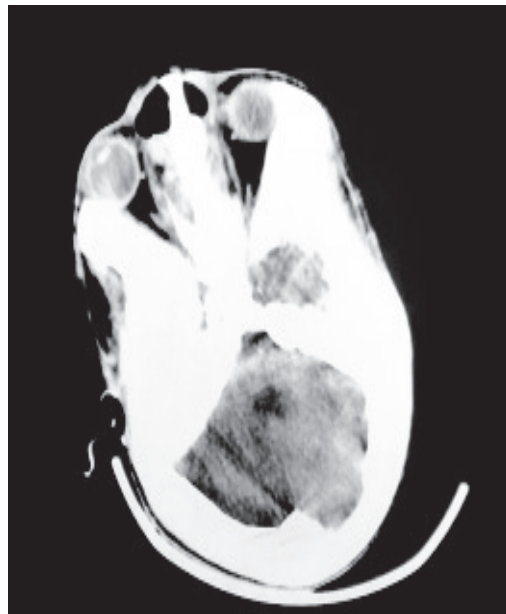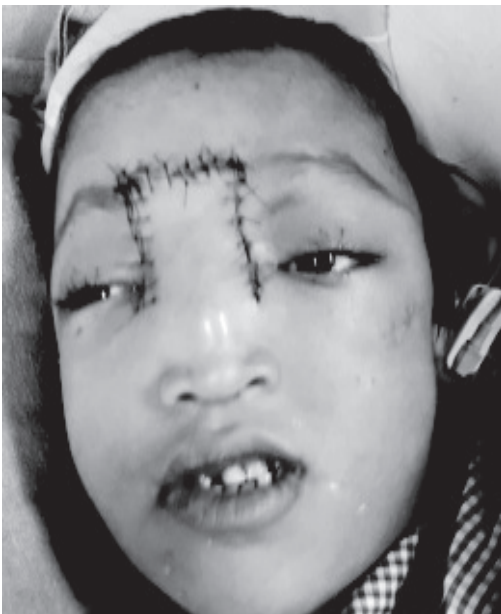Case-4 (CT scan shows involvement of Ethmoid, Sphenoid, temporal bones with bilateral narrowing of optic canal. Patient presented with bilateral visual impairment, proptosis and facial deformity. Post operative image shows vertical displacement of right eye).

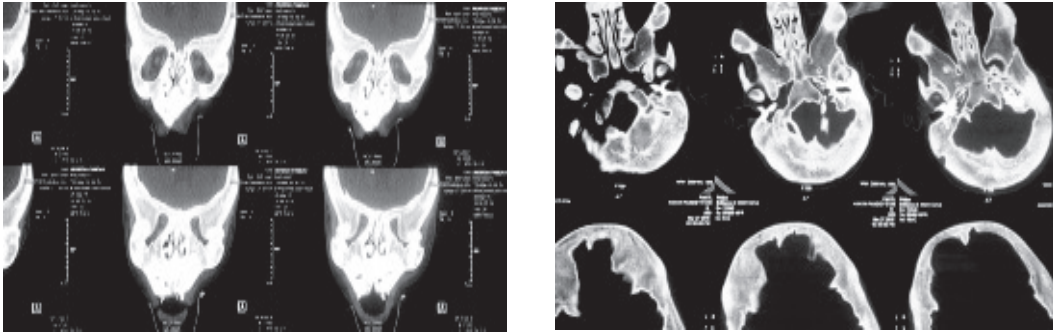


Case-4 (Absolute visual field defect in preoperative period. In post operative period visual field improved after 3 months)

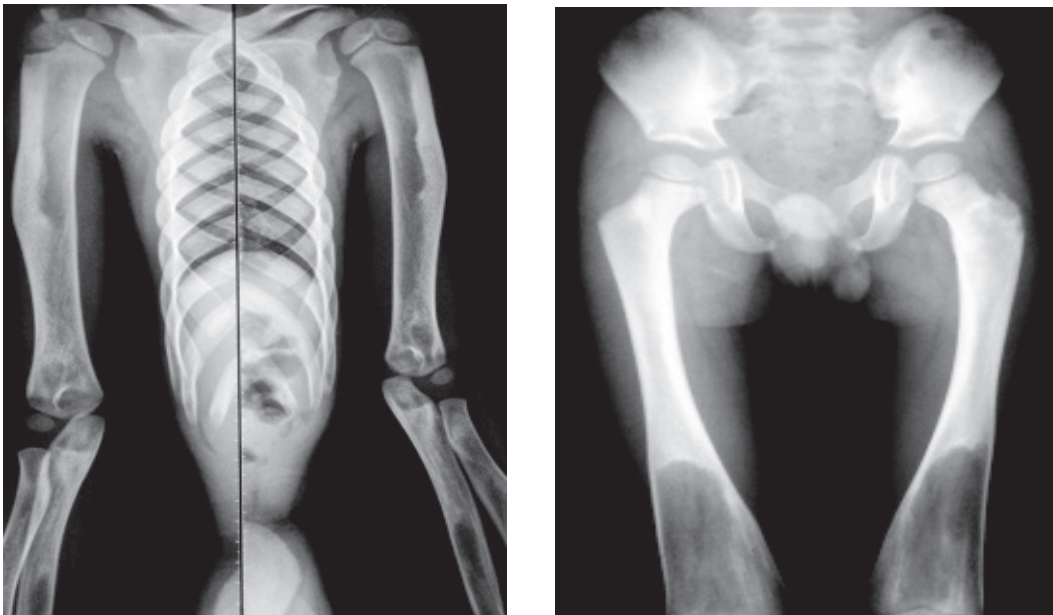
01 of our case was associated with Craniometaphyseal dysplasia which is a rare condition characterized by progressive thickening of bones in the skull and abnormalities in the limbs; metaphyseal dysplasia. Bone overgrowth in the head causes many of the signs and symptoms. Affected individuals typically have distinctive facial features; such as a wide nasal bridge, prominent forehead, wide-set eyes and a prominent jaw. Children with this condition

may have breathing or feeding problems caused by narrow nasal passages. Sclerosis of the skull may lead to asymmetry of the mandible, as well as to cranial nerve compression, that may finally result in hearing loss and facial palsy²⁵. The x-rays of individuals with craniometaphyseal dysplasia show unusual shaped long bones, particularly the large bones in the legs. The metaphyses are wider and appear less dense in people with this condition.





Case-16 (Widely separated eyes, flattening of nasal bridge and widening of nasal septum in cranio metaphyseal dysplasia. Bilateral involvement of skull base, severe compression of optic nerve at the level of optic canal. Optic canals are 1.5 mm in diameter in both sides)



Case-16 (Erlenmeyers Flask deformity of skeleton in Cranio Metaphysial dysplasia)

Conclusion

Role of optic nerve decompression in craniofacial fibrous dysplasia is controversial but timely intervention can save and improve vision. Extent of optic nerve encasement does not correlate with extent of visual impairment. All compressive optic neuropathy can be decompressed until preoperative visual acuity becomes PL-ve.

Use of modern equipment's; like high speed drill system, continuous irrigation and suction and navigating system can make precise, non-traumatic and safe decompression of optic nerve with adequate shaving and debulking of dysplastic bone for aesthetic improvement of facial deformity. Prophylactic surgical intervention by expert surgeon can prevent future impairment of vision.

References

1. Riminucci M, Fisher LW, Shenker A, Spiegel AM, Bianco P, Gehron Robey P: Fibrous dysplasia of bone in the McCune-Albright syndrome: abnormalities in bone formation. *The American journal of pathology* 1997; 151(6):1587-1600.
2. Nager GT, Kennedy GW, Kopstein E. Fibrous dysplasia: a review of the disease and its manifestations in the temporal bone. *The Annals of Otol Rhinol Laryngol (supplement)* 1982; 92:1-52.
3. Ricalde P, Horswell BB. Craniofacial fibrous dysplasia of the fronto orbital region: a case series and literature review. *J Oral Maxillofac Surg* 2001;59: 157-68.
4. Rootman J. Disease of the orbit. Philadelphia: Lipincott, 1988: 356-9.
5. Schwindinger WF, Francomano CA, Levine MA: Identification of a mutation in the gene encoding the alpha subunit of the stimulatory G protein of adenyl cyclase in McCune-Albright syndrome. *Proc Natl Acad Sci U S A* 1992, 89(11):5152-5156.
6. Weinstein LS, Shenker A, Gejman PV, Merino MJ, Friedman E, Spiegel AM: Activating mutations of the stimulatory G protein in the McCuneAlbright syndrome. *N Engl J Med* 1991, 325(24):1688-1695.
7. Yamamoto T, Ozono K, Kasayama S, et al: Increased IL-6 production by cells isolated from the fibrous dysplasia tissues in patients with McCune–Albright syndrome. *J Clin Invest*, 1996; 98: 30–35.
8. Finney HL, Roberts TS: Fibrous dysplasia of the skull with progressive cranial nerve involvement. *Surg Neurol* 1976, 6(6):341–343.
9. Albright F, Butler MA, Hampton AO, et al: Syndrome characterized by osteitis fibrosa disseminata, areas of pigmentation and endocrine dysfunction with precocious puberty in females. *N Engl J Med* 1937; 216:727–746.
10. Tsai EC, Santoreneos S, Rutka JT: Tumors of the skull base in children: review of tumor types and management strategies. *Neurosurg Focus* 2002, 12(5): e1.
11. Chen Y-R, Bredahl A, Chang C-N. Optic nerve decompression in fibrous dysplasia: indications, efficacy, and safety. *Plast Reconstr Surg* 1997; 99(1):22–30.
10. Parekh SG, Donthineni-Rao R, Ricchetti E, Lackman RD: Fibrous dysplasia. *The Journal of the American Academy of Orthopaedic Surgeons* 2004; 12(5):305-313.
13. Chen YR, Bredahl A, Chang CN: Optic nerve decompression in fibrous dysplasia: Indications, efficacy, and safety. *Plast Reconstr Surg* 1997; 99:22–33.
14. Edelstein C, Goldberg RA, Rubino G: Unilateral blindness after ipsilateral prophylactic transcranial optic canal decompression for fibrous dysplasia. *Am J Ophthalmol* 1998; 126:469–471.
15. Davies ML, Macpherson P: Fibrous dysplasia of the skull: disease activity in relation to age. *British Journal of Radiology* 1991, 64(763):576-579.
16. Lawrence w, Lustig, Michael J, Holliday, Edwar F, McCurthy, George t, Nager: Fibrous dysplasia involving the skull base and temporal bone. *Arch*

- otolaryngology and head neck surgery,2001;127:1239-1247.
17. Shields JA. Diagnosis and management of orbital tumours. Philadelphia: Saunders, 1989.
 18. K Bibby, R McFadzean: Fibrous dysplasia of the orbit. British Journal of Ophthalmology 1994; 78: 266-270.
 19. Janice S. Lee, Edmond F, John A, et al : Normal vision despite narrowing of the optic canal in fibrous dysplasia; The New England Journal of Medicine 2002; 347(21): 1670-1676.
 20. Schwartz DT, Alpert M. The malignant transformation of fibrous dysplasia. Amj MedSci 1964; 247: 1-20.
 21. Munro IR, Chen YR. Radical treatment for fronto-orbital fibrous dysplasia: The chain-link fence. Plast Reconstr Surg. 1981; :719.
 22. Barrionuevo CF, Marcallo FA, Coelho A, Cruz GA, Morcellin M, Patrocinio JA. Fibrous dysplasia and the temporal bone. Arch Otolaryngol 1980; 106: 298-301.
 23. Cutler CM, Lee JS, Butman JA. Longterm outcome of optic nerve encasement and optic nerve decompression in Fibrous dysplasia: Risk factors for blindness and safety of observation. Neurosurgery 2006; 59:1011.
 24. Lei P, Bai H, Wang Y, et al. Surgical treatment of Fibrous dysplasia. Surg Neurol 2009; 72(suppl 1): S 17.
 25. Nurnberg, P., Thiele, H., et al. Heterozygous mutations in ANKH, the human ortholog of the mouse progressive ankylosis gene, result in craniometaphyseal dysplasia. Nature Genet 2001; 28: 37-41.