

## Case Report

---

# Primary Laryngeal Tuberculosis Masquerading Laryngeal Malignancy

Nik Mohd Syukra Nik Abdul Ghani<sup>1,2</sup>, Hazama Binti Mohamad<sup>2</sup>, Nik Khairani Nik Mohd<sup>1</sup>, Amran Mohamad<sup>1</sup>

### Abstract:

*Nowadays, tuberculosis (TB) infection shows re-emergence again in many other part of the world due to HIV/AIDS- related disease, low socioeconomic as well as insurgence of multidrug resistance tuberculosis. TB is a disease which is primarily affects a lung. However it also can affect other organs as a secondary disease in a body via hematogenous or lymphatic spread. As in ENT field, TB also can manifest as a solely ear, nose or throat (ENT) disease such as in primary laryngeal tuberculosis (TB). In the past, laryngeal TB typically presented as a secondary disease with ulcerated laryngeal lesions in advanced pulmonary tuberculosis patient. In our case, we report a case of primary laryngeal tuberculosis masquerading as laryngeal malignancy in adult patient without pulmonary tuberculosis. In conclusion, in a patient who presented with various laryngeal symptoms, physician should be aware of the reemergence of laryngeal tuberculosis and the various manifestation of the disease.*

**Keywords:** Primary laryngeal tuberculosis, supraglottic mass, tracheostomy

### Case report

33 Malay man, chronic smoker referred from respiratory team who presented with history of worsening noisy breathing for 1 month associated with changes of voices for 3 months duration. There was also intermittent shortness of breath. However there was no dysphagia, odynophagia, prolonged cough, hemoptysis, haematemesis and chest pain. There was no fever, no night sweat but

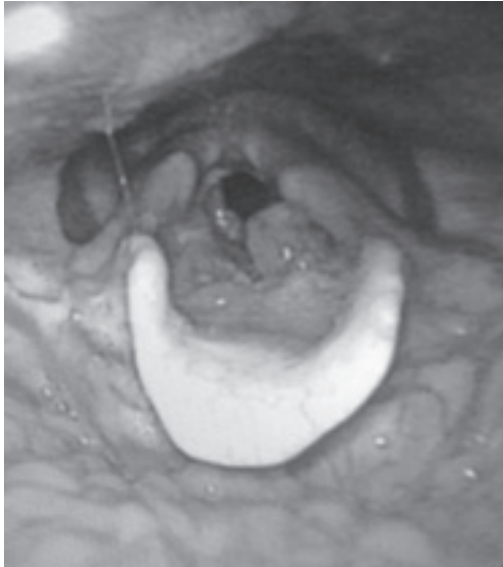significant loss of weight within 1 month duration. Otherwise there was no neck swelling and he denied contact with PTB patient.

On examination, patient had an inspiratory stridor with oxygen saturation of 100% under room air. Then examination with a 70 degree laryngoscope showed solitary papillomatous mass at supraglottic region arising from arytenoid and aryepiglottic fold obstructing laryngeal airway. Both vocal fold were mobile and equal symmetrically. The epiglottis, vallecula, piriform fossae also were normal. (Figure 1)

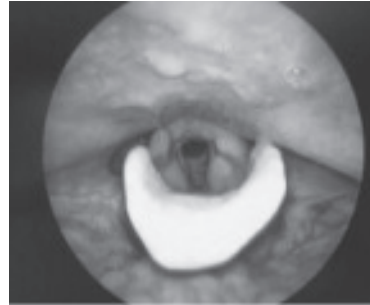
An emergency tracheostomy was commenced under local anaesthesia with direct laryngoscopy, rigid bronchoscopy and biopsy under general anaesthesia. Intraoperative findings showed hard broad base papillomatous mass just superior to left true vocal fold occupying left vestibular fold (true cord was spared). It extends to anterior commissure

- 1 Department of Otorhinolaryngology-Head and Neck Surgery, Hospital Sultanah Nur Zahirah Kuala Terengganu, Terengganu, Malaysia
- 2 Department of Otorhinolaryngology, Head and Neck Surgery, School of Medical Sciences, University Sains Malaysia Health Campus, 16150 Kubang Kerian, Kelantan, Malaysia.

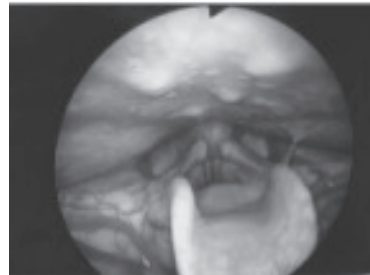
**Address of Correspondence:** Dr. Nik Mohd Syukra Nik Abdul Ghani, Department of Otorhinolaryngology-Head and Neck Surgery, Hospital Sultanah Nur Zahirah Kuala Terengganu, Terengganu, Malaysia



**Fig.-1:** 70 degree scope image showed multiple papillomatous mass at supraglottic region arising from arytenoid and aryepiglottic fold obstructing laryngeal inlet

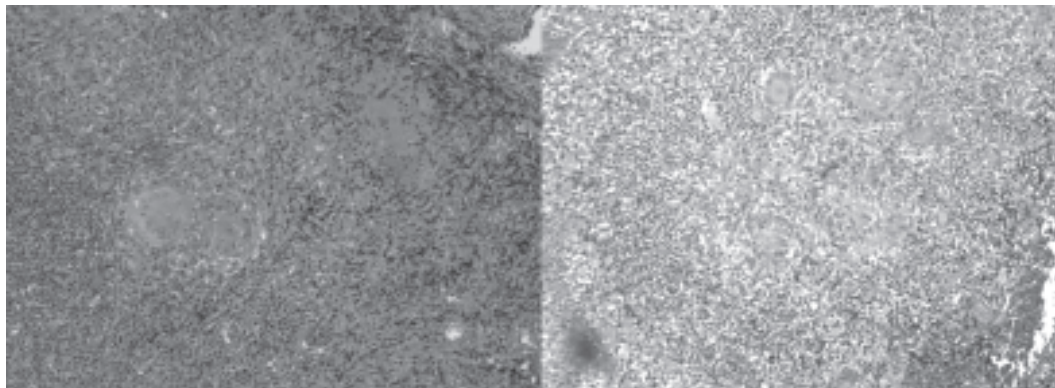


in abducted vocal fold position



in adducted vocal fold position

**Fig.-2:** 70 degree scope image showed complete resolution of supraglottic mass after completing anti tuberculosis medication



**Fig.-3:** stratified squamous epithelium exhibiting numerous epithelioid granulomas. Some of granulomas show central necrosis with the final impression of granulomatous inflammation suggestive of TB

obstructing the laryngeal inlet with no contact bleeding, a subglottic area and upper part of trachea were normal. A debulking of papillomatous mass using laryngeal microdebrider performed at the same time.

Later, histopathological examination of the biopsied mass revealed tissue covered by stratified squamous epithelium exhibiting

numerous epithelioid granulomas. Some of granulomas show central necrosis with the final impression of granulomatous inflammation suggestive of TB.

Patient was referred back to respiratory team for initiation of anti-tuberculosis therapy with the diagnosis of primary laryngeal TB. TB workout revealed normal chest x-ray, 3

consecutive day of sputum AFB smear were negative, the mantoux test also revealed no significant findings. All baseline blood profile were within normal range.

Patient was discharged home well with non-cuff tracheostomy tube size 7.5mm. Patient attended regular follow up while on anti TB medication. His general condition improved well until day 48 on anti TB medication, the tracheostomy tube was successfully decannulated and prior to that repeated a 70 degree scope showed complete resolution of supralaryngeal mass with patent airway (Figure 2).

### Introduction

The incidence of laryngeal tuberculosis (TB) has greatly decreased as a result of improvement in public immunization and the effectiveness of anti-tuberculosis chemotherapy. Laryngeal TB commonly secondary to a tuberculous lesion disseminated from other part in the body, or rarely a primary affection from inhaled tubercle bacilli settling directly on the larynx. Laryngeal tuberculosis is a rare which accounts for less than 8% of all extrapulmonary tuberculosis<sup>1</sup>. It can be either primary or secondary lesion. Secondary tuberculosis is theoretically always a complication of active pulmonary tuberculosis. The possible routes of spread are either direct contact of sputum containing tubercle bacilli or blood and lymph borne bacilli deposited locally. Furthermore, only few reported cases of primary laryngeal tuberculosis causing upper airway obstruction which account 0.5-1% of population in developing countries<sup>2</sup>. Although it is rare, physician should be aware that primary laryngeal tuberculosis may present with upper airway obstruction mimicking laryngeal malignancy. Laryngeal tuberculosis presentation may varies from isolated glottis

involvement such as vocal cord mass or involvement of supraglottic mass including arytenoids, aryepiglottic fold or epiglottis<sup>3</sup>. Till now there are few case reported as laryngeal TB presented with upper airway obstruction<sup>4</sup>. In developing country like Malaysia, although vaccination of BCG given to children as part of the immunization, the incidence of TB is rising, mostly attributed by the influx of immigrants from other Asian countries and immunocompromised state such as in AIDS patients<sup>5</sup>

### Discussion

Commonly laryngeal TB is a secondary manifestation of extrapulmonary tuberculosis of pulmonary TB infection. Lately, the increasing trend of cases of primary laryngeal tuberculosis has been reported in a few literatures. The previous mode of infection was direct spread along the airway involving mostly the posterior larynx, but currently it can involve any area of the larynx<sup>6</sup>. Few hypotheses have explained the infection pathways to the larynx and the hematogenous spread is the one most accepted. The airborne theory of contamination, advocate that the bacilli directly contaminate the mucosa, whereas in the lymphatic hypotheses thought there was a retrograde contamination from the tracheobronchial lymph nodes by explaining the frequent ipsilateral involvement seen in laryngeal and pulmonary lesions<sup>7</sup>. Laryngeal involvement has been observed in 15% to 37% of the cases of pulmonary tuberculosis, but as primary involvement it account only 19% of the tuberculosis cases<sup>8</sup>.

Most physicians do not consider tuberculosis in the differential diagnosis of various laryngeal symptoms, resulting in misdiagnosis and wrong treatment. In addition, AIDS and other immunosuppressive diseases have increased and will further contribute to the incidence and spectrum of

tuberculosis. This trend urges otolaryngologist to be on the alert about the emergence of the laryngeal tuberculosis with atypical clinical manifestations. Although it is rare today, laryngeal tuberculosis must be considered in the differential diagnosis of laryngeal lesions. In our case, the diagnosis of primary laryngeal tuberculosis was confirmed with biopsy specimen which suggestive of granulomatous disease (figure3). Other causes of granulomatous diseases with head and neck manifestations include granulomatosis with polyangiitis, Churg-Strauss syndrome, Behçet disease and sarcoidosis or other infectious include cat-scratch disease, syphilis, leprosy, actinomycosis, rhinoscleroma and fungal infections<sup>9</sup>. The diagnosis should be suspected in all individuals with hoarseness and significant dysphagia and could be confirmed with appropriate diagnostic tools, leading to proper treatment. The clinical manifestations of laryngeal tuberculosis have changed and seem to be different from those of classic reports. It can even occur without pulmonary tuberculosis, and the characteristics of lesions seem to be more nonspecific. It might be important to consider tuberculosis in the differential diagnosis of nonspecific laryngeal disease mimicking malignancy. Although airway obstruction rarely occurs in laryngeal TB, but in our case there was need of prompt urgent tracheostomy to secure the airway and responded well with anti-tuberculosis chemotherapy.

Laryngeal tuberculosis is still a frequent complication of pulmonary tuberculosis. However, there can be primary laryngeal lesions without any pulmonary involvement, and these cases seem to manifest as nonspecific, polypoid, single lesions that are very difficult to differentiate from other cause of chronic laryngeal disease. The successful

management of patients with laryngeal tuberculosis relies on clinical suspicion, prompt diagnosis, and early initiation of appropriate antituberculous chemotherapeutic regimen. The otolaryngologist can no longer rely on systemic or pulmonary symptoms to suggest laryngeal tuberculosis and must include tuberculosis as a possible etiological laryngeal lesion. The similarity of laryngeal tuberculosis to chronic laryngeal disease demands consideration of tuberculosis in the differential diagnosis of inflammatory laryngeal disease.

### References

1. Gomes T, Reis-Santos B, Bertolde A, Johnson JL, Riley LW, Maciel EL. Epidemiology of extrapulmonary tuberculosis in Brazil: a hierarchical model. *BMC infectious diseases*. 2014;14(1):9
2. Benwill JL, Sarria JC. Laryngeal tuberculosis in the United States of America: a forgotten disease. *Scandinavian journal of infectious diseases*. 2014;46(4):241-9
3. Gandhi S, Kulkarni S, Mishra P, Thekedar P. Tuberculosis of larynx revisited: a report on clinical characteristics in 10 cases. *Indian journal of otolaryngology and head and neck surgery : official publication of the Association of Otolaryngologists of India*. 2012;64(3):244-7
4. Tulunay OE. Laryngitis—diagnosis and management. *Otolaryngologic Clinics of North America*. 2008;41(2):437-51
5. Ramadan HH, Tarazi AE, Baroudy FM. Laryngeal tuberculosis: presentation of 16 cases and review of the literature. *The Journal of otolaryngology*. 1993;22(1):39-41.

6. El Ayoubi F, Chariba I, El Ayoubi A, Chariba S, Essakalli L. Primary tuberculosis of the larynx. *European annals of otorhinolaryngology, head and neck diseases*. 2014;131(6):361-4
7. Junaid M, Qadeer S, Sobani Z, Haroon S, Ghaffar S. Laryngeal Tuberculosis Presenting With Primary Symptoms Of Laryngeal Carcinoma. *SAARC Journal of Tuberculosis, Lung Diseases and HIV/AIDS*. 2013;10(1):40-2
8. Sá LCBd, Meirelles RC, Atherino CCT, Fernandes JRC, Ferraz FR. Laryngopharyngeal tuberculosis. *Revista Brasileira de Otorrinolaringologia*. 2007;73(6):862-6.
9. Nwawka OK, Nadgir R, Fujita A, Sakai O. Granulomatous Disease in the Head and Neck: Developing a Differential Diagnosis. *RadioGraphics*. 2014; 34(5): 1240-56