

Case Report

Hairy Polyp in the Nasopharynx - A Case Report

Sheikh Hasanur Rahman¹, Md. Idrish Ali², Md. Wahiduzzaman³, Chiranjib Sing Sinha⁴, Kamrul Hassan Tarafder⁵

Abstract:

Background: Hairy polyp or dermoid is a benign bigeminal congenital germ cell tumour. It is a rare condition in the nasopharynx. Hairy polyp in head and neck region consists less than 5% of that occurs in whole body.

Objective: To report a rare nasopharyngeal benign condition presented without obstructive symptoms.

Case: A four-year-old female child presented with a pedunculated dermoid tumour attached to the left lateral wall of nasopharynx. There was an associated unilateral cleft in soft palate. The tumour was removed by dissecting with bipolar diathermy by combined endonasal endoscopic and transoral approach.

Conclusion: Hairy polyp in nasopharynx may present as an incidental asymptomatic mass in throat and may be associated with a cleft palate.

Introduction:

Hairy polyp or dermoid is a benign bigeminal congenital germ cell tumour composed of ectodermal and mesodermal elements¹. Less

than 5% of it occurs in head and neck region². Its occurrence in nasopharynx is rare^{3,4}. It was first reported in 1784^{3,5}. Till 2012 a total of 170 cases in nasopharynx were reported⁶. Usually it presents due to its obstructive features – breathing or feeding difficulties^{1,7}. It usually presents in the first year of life; but it may present within hours to eighth decade of life^{3,4,8,9}. Hairy polyp is associated neither with a particular congenital syndrome nor with genetic abnormality. But rarely it may be associated with other congenital malformations such as cleft palate, absent uvula, auricular deformities, facial hemihypertrophy, ankyloglossia, osteopetrosis and atresia of carotid artery^{7,8,10}. Hairy polyps are successfully treated by simple surgical excision. With adequate removal these lesions do not or rarely recur^{5,8,9}. A combined transoral and nasoendoscopic surgical resection offer better outcome without any late complication as compared to blind resection¹¹.

1. Associate Professor, Department of Otolaryngology - Head and Neck Surgery, Bangabandhu Sheikh Mujib Medical University (BSMMU), Dhaka.
2. Consultant, Department of Otolaryngology-Head and Neck Surgery, (BSMMU), Dhaka.
3. Assistant Professor, Department of Otolaryngology- Head and Neck Surgery, (BSMMU), Dhaka.
4. Resident, Department of Otolaryngology-Head and Neck Surgery, (BSMMU), Dhaka.
5. Professor, Department of Otolaryngology-Head and Neck Surgery, (BSMMU), Dhaka.

Correspondence: Sheikh Hasanur Rahman, Associate Professor, Department of Otolaryngology - Head and Neck Surgery, Bangabandhu Sheikh Mujib Medical University (BSMMU), Dhaka. Phone: +88-01711-540139; E-mail: drbaborent@gmail.com

Case Report:

A four-year-old female child presented with the complaints of her mother of having a rounded mass in the throat for about six months. There was no breathing or feeding difficulties. The mass was grayish-white in colour, smooth, rounded and hard in consistency (Fig.-1). It was pedunculated and attached to the left lateral wall of nasopharynx. From nasopharynx it was protruding into the oropharynx. There was an associated unilateral cleft in the left side of the soft palate (Fig.-2). CT scan of nasopharynx revealed a soft tissue shadow with hyperdense area in the nasopharynx (Fig.-3). The tumour was removed by dissecting with bipolar diathermy by combined endonasal endoscopic and transoral approach retracting the soft palate. The surface of the removed mass was grayish-white and smooth. After sectioning the cut surface was variegated with different types of

soft tissue within it. There were two well-formed teeth like structures and bones within it (Fig.-4). Histological examination revealed that the tumour was covered with keratinizing squamous epithelium with epidermal appendages and the stroma contained fat, fibrous tissue, cartilage, bone and tooth like structures. There was no evidence of any endodermal element.

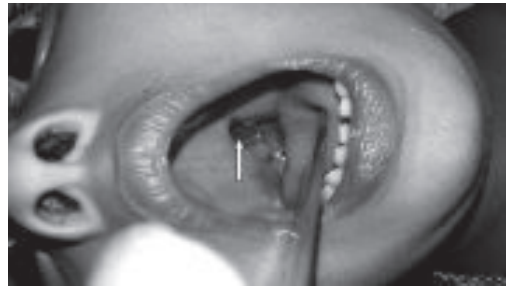

Fig.-2: A cleft in the left side of the soft palate.

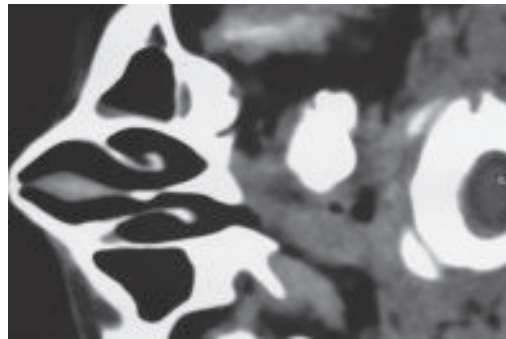


Fig.-3: An isodense shadow in the nasopharynx with an irregular hyperdense area within it.




Fig.-1: Smooth rounded mass seen in oropharynx after retracting the soft palate.

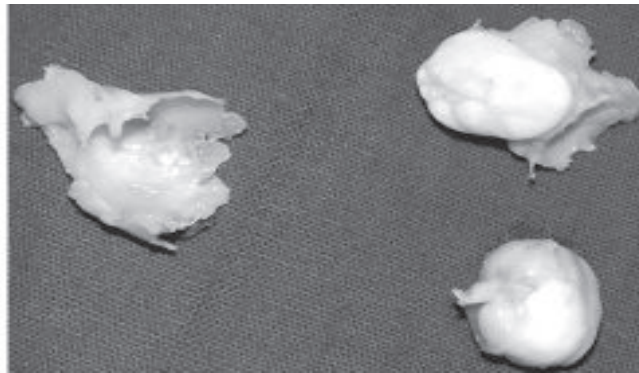
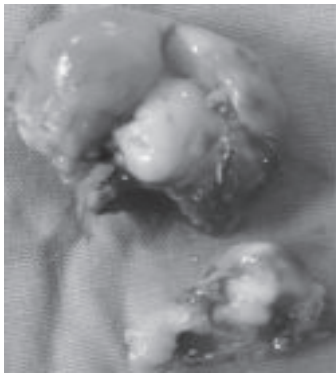


Fig.-4: Bones and well-formed tooth-like structures

Discussion:

Hairy polyp or dermoid in nasopharynx is a rare condition.^{3,4} It was first reported in 1784 by Ford as quoted by Brown-kelly.⁵ Till 2012 a total of 170 cases of nasopharyngeal hairy polyps were reported⁶. Arnold in 1870 classified congenital germ cell tumours into 4 categories: Teratomas, Teratoids, Epignathi, and Dermoids. Teratomas consist of 3 germ layers (ectoderm, mesoderm, and endoderm). The cells and tissues are differentiated so that organ can be recognized histologically. Teratoids are also trigeriminal but are composed of poorly differentiated tissues. Epignathi demonstrate highly differentiated trigeriminal layers in which well-formed organs and limbs of a parasitic fetus (fetus in fetu) are present. Dermoids are derived from only two germ layers (ectoderm and mesoderm).^{4,12} These tumours can present at any age, but mostly present in the first year of life.⁴ Presentation after the age of 20 is rare.^{1,3,4,9} Females are more frequently affected (F:M = 6:1).^{2,13,14} Most of reported cases were on the left side what is seen in the present case as well.⁶ The reason for predilection for females and left side is unknown.^{6,15} The present case is a four-year-old female child who presented with an incidental finding of a mass in the throat. But usual presentation is feeding or breathing difficulties^{1,7} and very rarely needs tracheostomy.¹⁶ Although it is associated neither with a particular congenital syndrome nor with genetic abnormality, rarely it may be associated with other congenital malformations such as cleft palate, absent uvula, auricular deformities, facial hemihypertrophy, ankyloglossia, osteopetrosis, and atresia of carotid artery.^{7,8,10} The present case has a small unilateral cleft in the left side of the soft palate. Hairy polyps are successfully treated by simple surgical excision. With adequate removal these lesions do not or rarely

recur.^{5,8,9} In the present case the tumour could be easily and completely removed by bipolar diathermy dissection using combined endonasal endoscopic and transoral approaches by retracting the soft palate. No peroperative or postoperative consequences were observed.

Conclusion:

Hairy polyp in nasopharynx may present as an incidental asymptomatic mass in throat and may be associated with a cleft palate.

References:

1. Abdullah VJ, Hassett CAV. Benign Conditions of Nasopharynx. In; Scott-Brown's Otolaryngology, Head and Neck Surgery. Seventh edition. Hodder Arnold 2008; London, Great Britain. PP. 2116-29.
2. Holt GR, Holt JE, Weave RG. Dermoids and Teratomas of the Head and Neck. Ear, Nose and Throat Journal. 1979; 58: 520-3.
3. Haddad J Jr, Senders CW, Leach CS, Stool SE. Congenital Hairy Polyp of the Nasopharynx Associated with Cleft Palate: Report of two cases. International Journal of Paediatric Otorhinolaryngology. 1990; 20:127-35.
4. Resta L, SantangeloA, Lastilla G. The S.C. 'Hairy polyp' or 'Dermoid' of the nasopharynx (An unusual observation in older age). Journal of Laryngology Otolaryngology. 1984; 98:1043-1046.
5. Jarvis SJ, Bull PD. Hairy Polyps of Nasopharynx. Journal of Otolaryngology. 2002; 116 (6): 467-9.
6. Yilmaz M, Ibrahimov M, Ozturk O, Karaman E, Aslan M. Congenital Hairy Polyp of the Soft Palate. International Journal of Paediatric Otorhinolaryngology. 2012; 76: 5-8.

7. Green VS, Pearl GS. A 24-Year-Old Woman with a Nasopharyngeal Mass. *Archives of Pathology and Laboratory Medicine*. 2006; 130: 33-34.
8. Zam HH, Hazama M, Suzina SAH, Husna NF, Irfan M. Nasopharyngeal Hairy Polyp as a Rare Cause of Neonatal Respiratory Distress: A Case Report. *Malaysian Journal of Medicine and Health Science*. 2013; 9(2): 81-84.
9. McShane D, Sherif EI, Doyle-Kelly W, Fennell G, Walsh M. Dermoids ('Hairy Polyps') of the oro-nasopharynx. *The Journal of Laryngology and Otology*. 1989(June); 103: 612-15.
10. Gambino M, Cozzi DA, Aceti MGR. Two Unusual Cases of Pharyngeal Hairy Polyp Causing Intermittent Neonatal Airway Obstruction. *International Journal of Oral and Maxillofacial Surgery*. 2008; 37: 761-2.
11. Agarwal N, Canabar D, Morrison GA. Combined Transoral and Nasendoscopic resection of an Eustachian Tube Hairy Polyp Causing Neonatal Respiratory Distress. *American Journal of Otolaryngology*. 2009; 30(5): 343-6.
12. Jarrahy R, Cha St, Mathiasen RA, et al. Congenital Teratoma of the Oropharyngeal Cavity with Intracranial Extension: Case Report and Literature Review. *Journal of Craniofacial Surgery*. 2000; 11(2): 106-12.
13. Kelly A, Bough Jr. ID, Luft JD. Hairy Polyp of the Oropharynx: Case Report and Literature Review. *Journal of Pediatric Surgery*. 1996; 704-6.
14. Walsh RM, Phillip G, Salama NY. Hairy Polyp of the Oropharynx: An Unusual Cause of Intermittent Neonatal Airway Obstruction. *International Journal of Paediatric Otorhinolaryngology*. 1996; 34: 129-34.
15. Kalcioğlu MT, Can S, Aydın NE. Unusual case of Soft Palate Hairy Polyp Causing Airway Obstruction and Review of the Literature. *Journal of Pediatric Surg*. 2010; 45(12): e5-e8.
16. Chaudhary AP, Love JM, Fisher JE, Gambrino AG. Teratoid Tumours of the Nasopharynx. *Archives of Otolaryngology*. 1978; 104: 517-25.