

Original Article

Evaluation of Tubercular Cervical Lymphadenopathy: Diagnostic and Therapeutic Utility

AKM Asaduzzaman¹, Md. Kabir Uddin², Mohammad Ali Azad³ Abdullahis Safi⁴, Wasim Selimul Haque⁵

Abstract:

Introduction: Lymphadenitis is the most common extrapulmonary manifestation of tuberculosis. It remains both diagnostic and therapeutic challenge as not only mimics other diseases but also inconsistent physical and laboratory findings. Diagnosis is difficult often requiring biopsy.

Aim: Aim of the study was to evaluate the role of surgical dissection of tuberculous cervicle lymphadenopathy for diagnosis as well as therapeutic purpose.

Methods: This observational study was conducted during the time period of 01 july 2015 to 30 june 2017 in ENT & Pulmonology department, combined military hospital Dhaka on 100 patients who have undergone surgical neck dissection.

Result: In our study total 100 patients were biopsied. Among them 56 patient was diagnosed as tubercular lymphadenitis after lymphnode excision biopsy. Among them 47 tubercular lymphadenitis patient responded to ATT (CAT-1), only 2 patient developed cold abscess which required further surgery. Six patient showed relapse during follow-up and 9 patient did not respond to CAT-1 treatment (treatment failure). Surgical intervention along with CAT-2 treatment showed cure in all of them.

2nd surgical interventions were done in total 17 patients, 2 TB abscess during ATT (CAT-1 HRZE), 9 treatment failure patients and 6 relapse patients along with ATT (CAT-2 SHRZE) and all these patients had no relapse or treatment failure during further follow up.

Keyword: Tubercular lymphadenopathy, Anti tubercular drug, surgical treatment

-
1. Classified ENT Specialist & Head-Neck Surgeon, Dept. of ENT and Head-Neck Surgery, Combined Military Hospital, Dhaka.
 2. Classified Medicine specialist, Dept. of Medicine, Combined Military Hospital, Dhaka.
 3. Classified ENT Specialist & Head-Neck surgeon, Dept. of ENT and Head-Neck surgery, Combined Military Hospital, Dhaka
 4. Graded ENT Specialist & Head-Neck surgeon, Dept. of ENT and Head - Neck Surgery, Combined military hospital, Dhaka
 5. Classified Specialist in pathology, Dept. of Pathology, Armed Forces Institute of Pathology, Dhaka

Address of correspondence: Col (Dr.) AKM Asaduzzaman, Classified ENT Specialist & Head-Neck surgeon, Dept. of ENT and Head - Neck surgery, Combined Military Hospital, Dhaka. Cell: 01769014786, E-mail: asad 100780@gmail.com

Introduction:

Tuberculosis (TB) is a granulomatous inflammatory disease caused by mycobacterium tuberculosis. Lymphadenitis is the most common extrapulmonary manifestation of tuberculosis. Tuberculous lymphadenopathy commonly involves lymph nodes of the head and neck region (posterior and anterior cervical chains, supraclavicular fossae, submandibular) in which cervical lymphadenopathy is most common.¹⁻³ It is important for otolaryngologists to be aware of TB in head and neck region and its various manifestations. Tuberculous lymph-adenopathy is not a life-threatening problem, but does require treatment by physicians and surgeons. The majority of patients tend to be young, healthy, working adults without constitutional symptoms. However, lymphadenopathy can progress to abscess and fistula formation, which can be disabling and socially unacceptable.⁴ ATT under dots is the main treatment while surgery is required for enlarged lymph nodes or tuberculous lymph node which does not regress with medication.⁵ Surgical techniques include aspiration, incision and drainage, curettage, complete surgical excision of the affected lymph nodes and overlying skin and selective nodal or functional neck dissection when required.⁶

The diagnosis of TB is mainly based on a positive mycobacterial smear and/or culture, Gene X-Pert positive or the histopathological presence of a chronic or caseating granuloma.⁷ Histopathology and Gene X-pert is the most confirmatory test.⁸

In this study an attempt was made to evaluate the role of surgical dissection in tubercular cervical lymphadenopathy for diagnostic and therapeutic purposes.

Methods:

This observational study was conducted at Combined Military Hospital, Dhaka during the

period of Jan 2015 to December 2016. The patient those reported to ENT outpatient department and those referred from Pulmonology and various other department are included in the study. The patient didn't had the confirmatory FNAC report underwent excision biopsy. In biopsy, materials is divided into three parts (1/3rd in normal saline for c/s, 1/3rd in normal saline for Gene X-pert, 1/3rd in formalin for histopathology.

Diagnostic findings were recorded in predesigned "diagnostic notes" register. Charts of the patients both male and female in the age range from 12 to 74 years were reviewed and operation notes analyzed. Total number of cases were 100. Approval of the Institutional Ethical committee was obtained for publishing the study. All patients gave informed written consent prior to study.

Inclusion criteria for tubercular lymphadenitis is clinical sign symptoms + caseation granuloma OR granuloma + Gene X-pert positive. Asymptomatic TB (without constitutional symptoms of TB) but biopsy showed caseation granuloma or granuloma + Gene X-pert positive also included in the study.

Patients do not response to anti tubercular therapy (CAT-1 HRZE) undergone surgical intervention (excision, neck dissection etc) along with anti tubercular medication (CAT-2 SHRZE) for tubercular cervical lymphadenopathy. Required data regarding diagnostic findings and method of surgery were retrieved. Data thus obtained were analyzed using SPSS version 16 for testing the significance of data, Pearson chi square was used as test of significance. A p-value of <0.05 was considered statistically significant.

Results:

Out of total 100 patients operated, 28 were male and 72 were female.

Incidence of tubercular lymphadenitis was more in case of female. The ratio of male and female is 2.57:1. The age range of the patients was 12-74 years.

Tubercular lymphadenitis was diagnosed in 56 patient. 3 sarcoidosis, 2 kikuchi disease, 2 toxoplasmosis, 3 foreign body granuloma, 8 lymphoma, 16 metastatic carcinoma, 6 non specific lymphadenitis and 4 patient was undiagnosed.

Table I
Distribution of Biopsy findings of cervical lymphadenopathy patient (n=100)

Biopsy findings	Number of pt(n=100)
Tuberculosis –caseation granuloma or granuloma+ Gene X-pert positive	56
Sarcoidosis	03
Kikuchi disease	02
Toxoplasmosis	02
Foreign body granuloma	03
Lymphoma	08
Metastatic carcinoma	16
Non specific lymphadenitis	06
Undiagnosed	04

Table-I shows Biopsy findings of 100 cervical lymphadenopathy patient

After completion of ATT (CAT-1 HRZE) out of total 56 patients 47 patients were cured, and 9 patients were not cured (treatment failure). out of 47 cured patient 2 patients developed abscess formation during the course of ATT

(CAT-1 HRZE). subsequently they required surgical intervention and was completely cured. Among the 9 patients who had not been cured after completion of ATT CAT-I. 4 patients developed cold abscess without any sinus, 1 patients developed cold abscess with sinus, 1 patients got tubercular lymphadenopathy of other site of neck, 2 patients had lymph node positive for caseating necrotizing granuloma in cytology with no change in size, and the rest 1 patients showed similar cytology with increased size of lymph node. Out of 47 cured patients 6 had relapse during follow up.

Surgical interventions were done in total 17 patients, 2 TB abscess during ATT (CAT-1 HRZE), 9 treatment failure patients and 6 relapse patients along with ATT (CAT-2 SHRZE) and all these patients had no relapse or treatment failure during further follow up.

Table II
Distribution of patient status in relation to tubercular lymphadenitis (n=56)

SEX	Number of Patient	Percentage
Male	12	21.42%
Female	44	78.58%

Table-III shows the incidence of cervical lymphadenitis in relation to sex.

Table III
Distribution of laboratory findings after surgical excision of TB node(n=56)

Features	Findings	Number of patient %
Histopathology	Caseation necrosis	48 (85.71%)
Gene X-pert	Positive	13 (23.21%)
Culture sensitivity	AFB	2 (3.57%)

Table-III shows Distribution of laboratory findings after surgical excision of TB node(n=56)

Table IV
Distribution of patient developed complications during/after anti tubercular drug (n=11)

No of patient	Complications
6	Abscess(cold abscess)
1	Tubercular sinus
1	TB lymphnode to other site of neck
2	Having caseation necrosis but no change in size
1	Having caseation necrosis but increase in size

Table -IV shows percentage of patient developed complications during/after anti tubercular therapy (CAT-1)

Table V
Distribution of patient and Pattern of surgery who have undergone 2nd surgical intervention (n=17)

Pattern of surgery	Number of patient
Excision of Lymphnode	7
En-Block resection	6
Selective neck dissection	4

Table V shows number of patient and Types of surgery who needs surgical intervention Number of patients cured by tubercular chemotherapy or combination of surgery with tubercular chemotherapy.

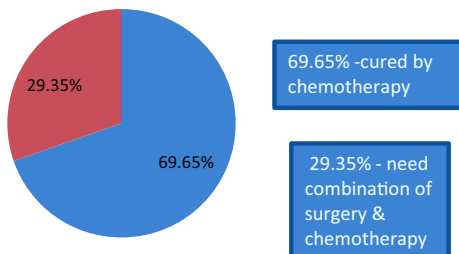


Fig-1 shows pie diagram of cure rate following chemotherapy and combination of surgery and chemotherapy

Discussion:

The most common manifestation of mycobacterial infection encountered in otolaryngological practice is cervical lymphadenopathy (Munck and Mandpc, 2003).⁹ A higher proportion of the patients are females (Polakova, 1993; Dvorski, 1989).¹⁰TCL is not a life-threatening problem, but does require treatment by physicians and surgeons. The majority of patients tend to be young, healthy, working adults without constitutional symptoms. However, lymphadenopathy can progress to abscess formation and fistula formation, which can be disabling and socially unacceptable. Physical and laboratory findings may be inconsistent or unreliable. They can mimic other pathologic processes which may be treated with either surgery or medication¹¹

ATT under DOTS is the main treatment while surgery is required for enlarged lymph nodes or TCL which does not regress with medication¹².

In our study out of total 56 patients patients were completely cured by ATT(CAT-1 HRZE) alone and only 02 required surgical interventions, 6 patients who were cured by ATT(CAT-1 HRZE)had relapse and required 2nd surgical interventions. Surgical interventions were done in total 17 patients{(2 TB abscess patients during ATT(CAT-1 HRZE),9 treatment failure patients and 6 relapse patients} and all these patients were completely cured without relapse or treatment failure after surgical intervention and (CAT-2 SHRZE) during follow up. Similar findings were reported in other studies. A study by Kanjanopas K et al found 100 % cure rate after complete surgical excision of the node before receiving a full course of medication. All 34 cases treated with modified neck dissection before a full course of medication were cure¹³.

Another study conducted by K. F. Sui et al reported 100 %cure rate after excision of all

grossly involved lymph node. In a study by Subrahmanyam M³⁵ patients treated with surgery and chemotherapy, 29 patients were completely cured, and out of 70 patients who had treated only with chemotherapy 52 patients were completely cured¹⁴.

In this study, among the 9 patients who had not been cured after completion of ATT cat-I, 4 patients developed cold abscess without any sinus, 1 patient developed cold abscess with sinus, 1 patient got tubercular lymphadenopathy of other site of neck, 2 patients had lymph node positive for caseating necrotizing granuloma in cytology with no change in size, and the rest 1 patient showed similar cytology with increased size of lymph node. Out of 41 cured patients 6 had relapse during follow up. In study by Kanjanopas K et al¹⁴, six of the 14 who

were treated with drug therapy alone had problems: 2 progressed to abscess formation and 4 had residual enlargement of their lymph nodes that required surgery. Of the 47 cases with multiple cervical lymph nodes ≤ 3 cm in diameter, 13 were treated with medication alone; 9 (69%) did well and 4 developed an abscess and had residual lymphadenopathy.

Similar to other studies, our study has also reported that combination of surgical intervention with anti tubercular chemotherapy showed better outcome compared to chemotherapy alone.

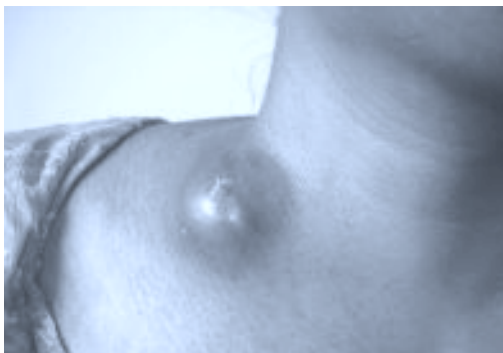

Fig.-1: A 25 yrs lady presented with tubercular abscess.

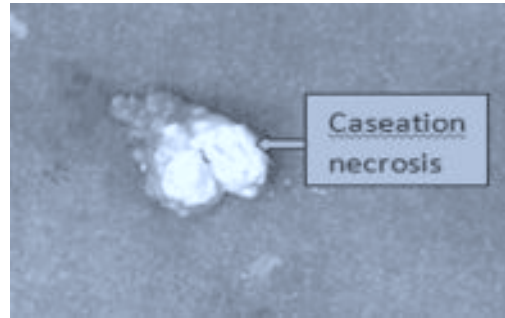


Fig.-2: Cut section of TB neck node with central caseation necrosis




Fig.-3: Cut section of TB neck node with central caseation necrosis

Conclusion:

Surgical intervention has strong role to confirm diagnosis in undiagnosed patient. Antitubercular treatment is main treatment for tubercular lymphadenitis but in those patients who developed complications and those got relapse or failure to antitubercular treatment require surgical interventions. Early surgical intervention in these patients reduce complications such as abscess, sinus, fistula formation, or spread of disease to other parts of body. Timely surgical intervention also reduce the morbidity and increase the quality of life of patients.

References:

1. Cantrell RW, Jensen JH, Reid D. Diagnosis and management of

- tuberculous cervical adenitis. *Arch Otolaryngol* 1975;101:53–7.
2. Hooper AA. Tuberculous peripheral lymphadenitis. *Br J Surg* 1972;59:353–9.
 3. Kent DC. Tuberculous lymphadenitis: Not a localized disease process. *Am J Med Sci* 1967; 254: 866–74.
 4. Kanlikama M, Mumbuc S, Bayazit Y, Sirikci A. Management strategy of mycobacterial cervical lymphadenitis. *J Laryngolotol* 2000;114: 274-8.
 5. Castro DJ, Hoover L, Zuckerbraun L. Cervical mycobacterial lymphadenitis medical vs surgical management. *Arch Otolaryngol* 1985;111: 816-9.
 6. Danielides V, Patrikakos G, Moerman M, Bonte K, Dhooge C, Vermeersch H. Diagnosis, management and surgical treatment of non-tuberculous mycobacterial head and neck infection in children. *ORL J Otorhinolaryngol Relat Spec.* 2002;64:284-289.
 7. Michael RC, Michael JS. Tuberculosis in otolaryngology: clinical presentation and diagnostic challenges. *Int J Otolaryngol.* 2011; 2011:686894. doi10.1155/2011/686894
 8. Lau SK, Kwan S, Lee J, Wei WI. Source of tubercle bacilli in cervical lymphnodes: a prospective study. *J laryngol Otol.* 1991 jul;105(7): 558-619.
 9. Munck K, Mandpc AH. Mycobacterial infections of the head and neck. *Otolaryngol Clin North Am* 2003; 36: 569-76.
 10. Polakova K. Tuberculosis lymphadenitis, the most frequent symptoms of extrapulmonary tuberculosis. *Bratisl Lek Listy (Slovakia)* 1993; 94: 504-6.
 11. Kanlikama M, Mumbuc S, Bayazit Y, Sirikci A. Management strategy of mycobacterial cervical lymphadenitis. *J Laryngolotol* 2000;114: 274-82
 12. Castro DJ, Hoover L, Zuckerbraun L. Cervical mycobacterial lymphadenitis medical vs surgical management. *Arch Otolaryngol* 1985; 111: 816-9.
 13. Kanjanopas K, Siripan N and Phoophitphong R. Tuberculous cervical lymphadenopathy and the role of surgical treatment. *Southeast Asian J Trop Med Public Health.* 2014;45:1419-24.
 14. K. F. Siu, A. Ng, J. Wong. Tuberculous lymphadenopathy: a review of results of surgical treatment. *Anz Journal Of Surgery.* 1983; 53:253–7.
 15. Kanjanopas K, Siripan N and Phoophitphong R. Tuberculous cervical lymphadenopathy and the role of surgical treatment. *Southeast Asian J Trop Med Public Health.* 2014;45:1419-24.