

Case Report

Huge Intramuscular Cavernous Hemangioma involving SCM, Trapezius and scalene anterior: A Case Report

Akhil Chandra Biswas¹, Nazmul Hossain Chowdhuri², Feroz Ahmed³, Fariduddin Milki⁴, Tareq Mohammad⁵, ASM Lutfur Rahman⁶

Abstract:

Intramuscular hemangiomas are rare benign neoplasms accounting for <1% of all hemangiomas and <20% are found in head and neck area. The muscle most frequently involved is the masseter muscle and very few cases have been reported for the occurrence of these hemangioma in the Sternocleidomastoid, trapezius muscle and scalene anterior muscles. Here, we are presenting a case report of intramuscular hemangioma involving these muscles in a 10-years-old boy.

Key words: *Intramuscular, Cavernous Hemangioma, Sternocleidomastoid, Trapezius*

Introduction:

The first report of a case of intramuscular hemangioma is attributed to Liston in 1843, which called this entity an “erectile tumor.” Intramuscular hemangiomas (IH) are rare, benign vascular neoplasms frequently arising within the skeletal muscle of the trunk and extremities. These account for less than 1% of all hemangiomas, and head and neck

involvement is considered unusual¹. Histologically it is thought to be as hamatoma or neoplasm². Generally, hemangiomas are more commonly affected female than male. They are frequently seen on the trunk and extremities, but up to 20% of hemangiomas are located at the head and neck region^{2,3}. Although the majority are cutaneous or mucosal hemangioma, the intramuscular hemangiomas are extremely rare accounting for 0.8% of all hemangiomas^{4,5}. Here we present a case that involved the Sternomastoid, trapezius and scalene anterior muscles. So far we believe, it is the first reported case of such involvement.

Case summary:

In 15th jan 2017 a 10 years old cute boy was admitted in our ENT department with a Swelling in left lateral side of neck since birth.

According to the patient’s mother, she noticed a neck swelling just after birth,

1. Associate Professor, Department of ENT, Bangladesh Medical College, Dhaka
2. Assistant Registrar, Department of ENT, Bangladesh Medical College, Dhaka
3. Resident Surgeon, Department of ENT, Bangladesh Medical College, Dhaka
4. Consultant, Department of ENT, Bangladesh Medical College, Dhaka
5. Assistant Registrar, Department of ENT, Bangladesh Medical College, Dhaka
6. Consultant, Department of ENT, Bangladesh Medical College, Dhaka

Address of Correspondence: Dr. Akhil Chandra Biswas, Associate Professor, Department of ENT, Bangladesh Medical College, Dhaka

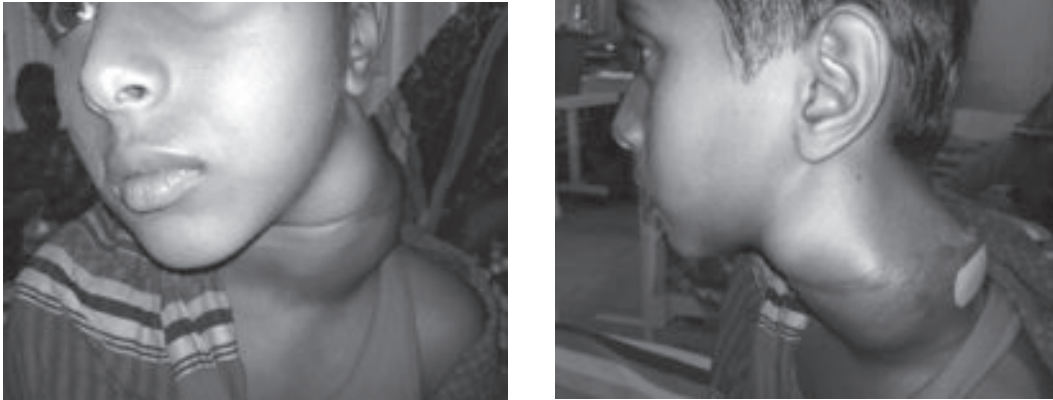


Fig 1(a,b): AP and lateral view

initially it was very small, approximately 2x2 cm and gradually increasing in size, associated with mild low grade diffuse local pain, that does not radiate to any site. He had no problem related to the swelling, such as voice change, swallowing problem, or movement of limbs etc. except mild pain, cosmetic problem and fear of malignancy. He underwent surgery on 19th day for this problem but the swelling remained as such.

On Examination, There was a large diffuse swelling on the left side of neck extending from the angle of the mandible upto sternal end of clavicle, posterolaterally the vertebral column, medially near the midline approximately 10 cmX8 cm, with a scar mark over the swelling (Fig: 1,2). It does not moves with swallowing

The swelling was non tender, soft to firm in consistency; temperature was normal, irregular surface, approximately 10 cmX8 cm. It was free from overlying skin and underlying structure, prominent on contraction of left SCM. No palpable cervical lymphadenopathy. All the cranial nerves were intact.

After USG and FNAC our final diagnosis was cavernous hemangioma. We advised for color Doppler, MRI neck, but patient party refused due to their financial problem. Other investigations for GA were within normal limit. Operation was done on 17th January 2017.

Procedure and finding: Under all aseptic precaution a **schobinger** incision with a **lazy s** on vertical limb was made and the mass was exposed by elevating the **subplatysmal suprajugular** flap composed of skin subcutaneous tissue and platysma (Fig.- 2).

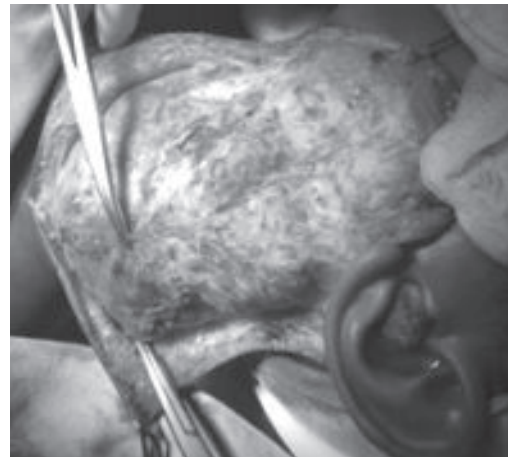


Fig.-2: After elevating the subplatysmal flap

The mass was extremely vascular with multiple engorged veins, multilobular, bluish in color and the sternomastoid muscle was found very thin and almost engulfed by the lesion. Dissection started from midline after skeletonizing internal jugular vein (Figure 3), CCA, Xth nerve.

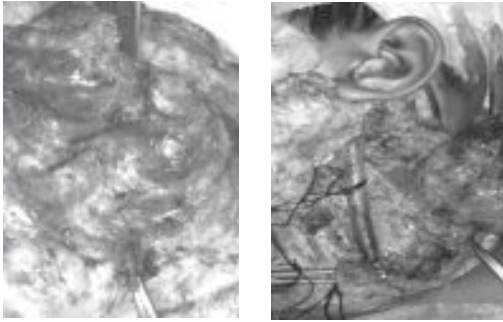


Fig.-3 Lesion separated from the IJV & retracted laterally

On further exposure the mass was found to invade the fibers of the trapezius posterolaterally and scalene muscles. Multiple branches of cervical plexus were also encircled by the tumor. Major part of sternomastoid and trapezius and was excised along with the lesion and part of involved scalene muscle can be dissected free from the lesion by bipolar diathermy. The spinal accessory nerve was encircled by the lesion so it was intentionally sacrificed. Whole lesion was excised with the help of bipolar diathermy and wound closed in layers leaving a drain tube in situ.

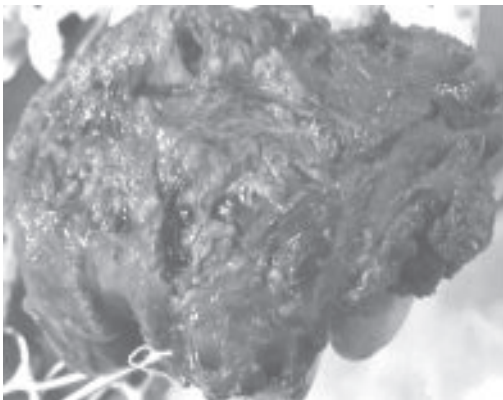


Fig.-4: The lesion after complete excision showing the muscular and vascular component

Postoperatively he had pain on Abduction and external rotation of shoulder. But it was significantly improved after regular physiotherapy.

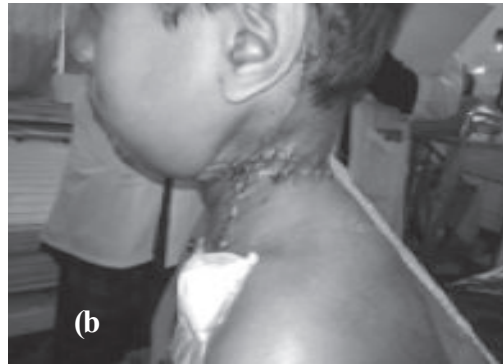
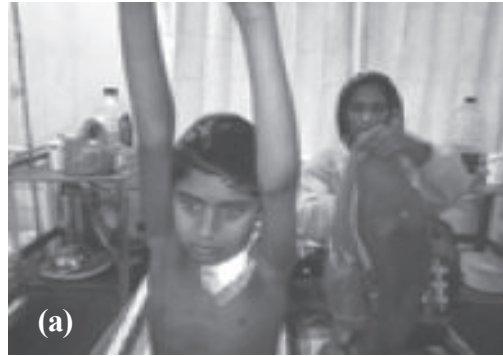
Fig.- 5 (a & b): 7th POD

Histopathologically there were both muscular and vascular components suggestive of intramuscular cavernous hemangioma.

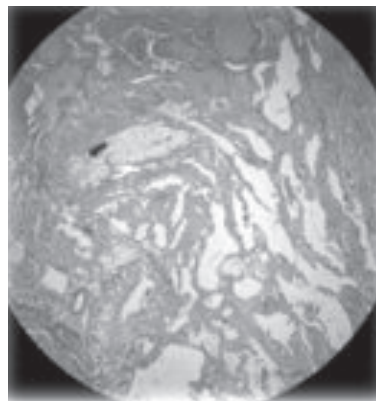


Fig.-6: Histopathological picture

Discussion:

Hemangioma are benign proliferative vascular lesions characterized by increased endothelial cell turnover that usually appears after birth, grow rapidly, and then involute over the years. Within the wide spectrum of vascular lesions, intramuscular hemangioma are very rare accounting for <1% of all Hemangioma.

The masseter muscle is the most frequent muscle, accounting for 5% of all intramuscular Hemangioma. The trapezius, periorbital, sternocleidomastoid, and temporalis muscles follow the masseter muscle in frequency⁶. There are very few cases in the literature regarding intramuscular hemangioma involving both SCM & trapezius.

In 1843, Liston was the first to report a case of intramuscular cavernous hemangioma naming it as an "erectile tumor." Intra muscular hemangiomas are considered hamartomatous lesions and thought to arise from abnormal embryonic rests⁷.

Developmentally, intramuscular Hemangioma represents congenital vascular malformations. They generally develop in patients during the first three decades of life with no gender predispositions. Most hemangioma are recognized clinically and do not require any investigation. The predominant complaint is presence of a slowly enlarging mass⁸.

Intramuscular hemangioma rarely display any clinical symptoms or signs that reveal their vascular nature. They usually presents with a normal overlying skin, although there may be occasional reddish blue discoloration. Thrills, bruits, compressibility, and pulsation are usually absent; however, pain can be present⁸. These features were also consistent with the present case.

Sonography is the first line imaging procedure for patients with soft tissue swellings. Color Doppler Sonography is especially useful to

demonstrate the vascular structure. in and around the masseter muscle and has the potential to evaluate the pathological changes. Hemangioma could be distinguished from other soft tissue lesions by the features of abundant vascularity and high blood flow velocity. When performing sonography on soft tissue masses in the head and neck, the presence of a color Doppler signal in a well defined hypoechoic mass with heterogeneous echotexture should raise the possibility of hemangioma⁶.

Intramuscular hemangiomas represent a challenge on diagnosis because they exhibit few signs on clinical examination. The extent of the lesion is not always clinically apparent on examination and imaging techniques frequently define more extensive lesions than suspected⁹. Definitive preoperative diagnosis has been reported in <8% of cases⁸.

Management of intramuscular haemangioma should be individualized according to

1. Its size
2. Growth rate
3. Anatomic accessibility of the tumor,
4. Age of the patient and
5. cosmetic and functional considerations.

Complete surgical resection is preferred as a treatment of choice, but local recurrence rates have been reported as 18% and 19% in two different studies⁶.

References:

1. Emanuele F, Ida P, Enrico A. Intramuscular cavernous hemangioma of the sternocleidomastoid muscle: An unusual neck mass. *Otolaryngology–Head and Neck Surgery* (2007) 137, 682-683.
2. Allan PW, Enzinger FM. Haemangioma of skeletal muscle, an analysis of 89 cases. *Cancer*. 1972;29:8–22.

3. Kanaya H, Saito Y, Gama N, Konno W, Hirabayashi H, Haruna S. Intramuscular hemangioma of the masseter muscle with prominent formation of phleboliths: A case report. *Auris Nasus Larynx*. 2007;35(4):587–591.
4. Demir Z, Oktem F, Celebiolu S. Rare case of intramasseteric cavernous hemangioma in a three-year-old boy: a diagnostic dilemma. *Ann Otol Rhinol Laryngol*. 2004;113:455–458.
5. Watson WL, McCarthy WD. Blood and lymph vessel tumors. A report of 1056 cases. *Surg Gynecol Obstet*. 1940; 71:569–588.
6. Afsar FS, Oziz E, Hamdioglu Y, Karasoy I, Uguz B. Intramuscular haemangioma of the masseter muscle in a 9-year-old girl. *Acta Angiol* 2007;13:42-6.
7. Kushraj T, Chatra L, Shenai P, Rao PK, Shetty SR. Cavernous hemangioma of the buccinator muscle-MRI features. *Pac J Med Sci* 2013;12:65-70.
8. Zengin AZ, Celenk P, Sumer AP. Intramuscular hemangioma presenting with multiple phleboliths: A case report. *Oral Surg Oral Med Oral Pathol Oral Radiol* 2013;115:e32-6.
9. Shafer W.G, Hine M.K, Levy B.M. *Shafer's Textbook of Oral Pathology*. 7th ed . New Delhi: Elsevier Publication; 2012.