

Original Article

Rhinoplasty: Experience in Combined Military Hospital, Dhaka

Md. Bashir Ahmed¹, Rehana Akter², Salahuddin Ahmed³

Abstract:

Background: Rhinoplasty, perhaps is the most complex and challenging cosmetic surgical procedure performed today. Hence, a thorough preoperative evaluation and the surgical skill in performing the operation is most important for final desired outcome. Establishing an accurate diagnosis through a comprehensive nasal analysis is obligatory.

Objective: To assess post-operative functional and aesthetic outcome and patient's satisfaction of all rhinoplasty operations.

Methods: Retrospective study carried out in combined military hospital, Dhaka. 50 patients with external nasal deformity who were operated for functional, aesthetic or for both reason were included. Patients' satisfaction levels from the procedures were routinely documented in the post op visits as completely satisfied, partially satisfied and not satisfied at all.

Results: A total of 50 cases underwent rhinoplasty and septorhinoplasty operations. The most common reason of disfigurement was traumatic injury during games (40%). Different surgical procedures were done without any major complications. Except few most of the patients were fully satisfied.

Conclusion: For better satisfaction of patients, adequate preoperative counseling and realistic expectations are warranted. Skillful surgical techniques reduce the chances of complications. ²

Keywords: Septoplasty, Rhinoplasty, Septorhinoplasty, External nasal deformity

Introduction:

Nose is the central and most prominent feature of the face. It is also the most vital part of facial contour and beauty. The term rhinoplasty has derived from Greek word

“Rhinos” which means Nose and “Plassein” means to shape. Commonly known as Nose job, Rhinoplasty or Nose plastic surgery which enhances facial appearance by correcting nasal deformities and improving aesthetic appearances of the nose. It was described in ancient Egypt in 2500-3000 BC. In ancient India it was first described by the ayurvedic physician Sushruta in his book “Sushrutasamhita (c.500 BC)”. Sushruta is considered as the father of rhinoplasty surgery in the world.¹ The first documented evidence of the available records regarding rhinoplasty comes from Edwin Smith papyrus.² In 1887- John Orlando Roe first performed “Intra nasal Rhinoplasty”. In India Rhinoplasty started to reconstruct nose for

-
1. Classified specialist in ENT and Head neck surgery, Combined military hospital, Dhaka
 2. Assistant professor, Jessore Medical College, Dhaka
 3. Classified specialist in ENT and Head neck surgery, BGB hospital, Dhaka

Address of Correspondence: Lt Col Md Bashir Ahmed, MBBS, DLO, MCPS, FCPS Classified specialist in ENT and Head neck surgery, Combined military hospital, Dhaka

those whose nose was destroyed by rhinectomy. Such a mutilation was inflicted as a criminal, religious, political, and military punishment in that time.

Rhinoplasty is the 2nd most common surgeries performed by facial plastic surgeons worldwide. Patient satisfaction is the principal outcome measure of success in facial cosmetic surgeries. Patient's satisfaction may be influenced by social environment, education, life experience and level of expectations, which may or may not be realistic. Complete photographic documentation is fundamental to both physician and patients for surgical planning and assessment of post-operative results. Photograph including right and left lateral and oblique views along with anterior, inferior (basal) and superior views for analyzing the target, outcomes and for discussing the surgical and aesthetic issues with the patient should be taken.^{3,4} After detailed anatomical and anthropometric analysis individualized surgical planning including precise need and amount of cartilage resection, suturing, osteotomies⁵ and dynamics of nasal airway should be considered.^{6,7}

Open rhinoplasty has certain advantages such as detailed and wide exposure of nasal shape defining structures, easy suturing and avoidance of distortion of anatomy for planning the reconstruction. There are certain definite disadvantages like trans-columellar scar, increased chances of post op edema in the tip and dorsum and need of fixation for graft placement which could be done without fixation in the closed technique.⁸

Methods:

Retrospective study carried out in Dhaka combined military hospital, from 1st March 2017 to 31st Dec 2018. 50 patients with external nasal deformity who were operated for functional, aesthetic or for both reason were included. We evaluated the high resolution CT images of the nose and PNS with 3D reconstruction of face in posttraumatic

cases along with analysis of photographs of all the patients in all 6 views were made.

All such patients under went detailed facial photography in frontal or anterior profile view, basal or inferior view, superior view, right and left oblique view and right and left lateral views as per protocol. All patients had undergone detailed facial analysis including objective measurement of facial angles, target oriented realistic psychological assessment and counseling prior to pre anesthetic checkup and surgical planning. Type of deformity, etiology, surgical procedures performed, grafts and splints used were analyzed and studied. Patients' satisfaction levels from the procedures were routinely documented in the post op visits as completely satisfied, partially satisfied and not satisfied at all.

Follow up was done initially at 2 weeks then 1 month, 3 months, 6 months, 12 months and 18 months period.

Limitations of the study

- A. This study may not reflect the real situation in our country as the study was carried out in military population who are more active in physical activities than general population.
- B. Duration of follow up is short. Not yet completed the time for 02 years for follow up.

Results:

Total 50 cases were operated in CMH Dhaka from 1st March 2017 to 31st Dec 2018. There were 38 males and 12 females; among the patients with a male to female ratio of 3.16:1 (Chart 1).

Number of male patients were higher than female because of injury during boxing, playing football, volleyball, hokey etc, as these are regular activities of military service. The age range was between 21 and 50 years among those who presented to us for rhinoplasty (Chart 2).

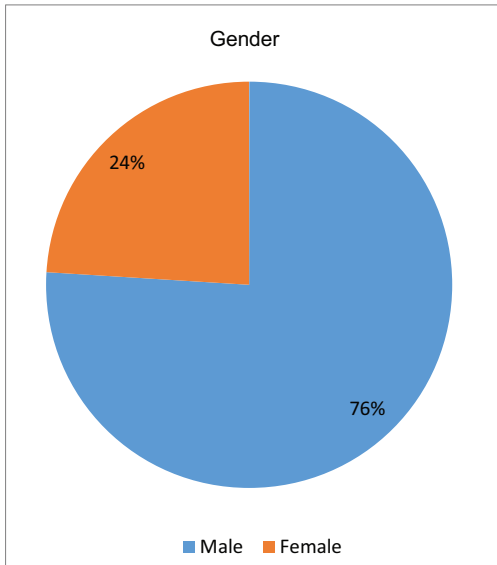


Chart 1

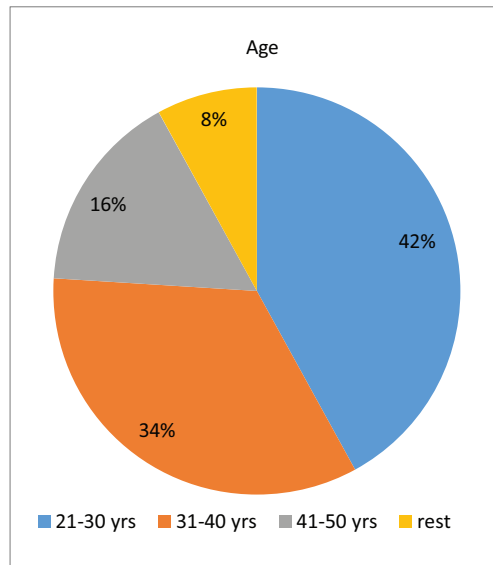


Chart 2

History and cause for which they underwent rhinoplasties were noted in patients. The most common reasons for which our patients attended the ENT OPD for rhinoplasty were results of sports injury 14 out of 50 (28%) and 13 out of 50 (26%) developmental deformity. Rest 9/50(18%) cases had post septoplasty and 6/50(12%) cases) had history of road traffic accident (Table 1).

Out of 50 cases, 18 persons (36%) had presented with saddle nose deformity and requested for the correction. Saddle nose deformity most commonly due to post submucosal resection. 10 patients had hump deformity and 15 patients had crooked nose with multiple deformities which made them to visit our outpatient department. Two patient who had a history of boxing injury had an open roof deformity (Table 2).

Table I :

Causes of deformity from history

Attributable causes from history	No. of patients	Percentage %
Road traffic accidents	6	12%
Sports injury	14	28%
Post septal abscess	8	16%
Post septoplasty	9	18%
Developmental	13	26%
Total patients	50	100%

Table II :

Types of deformity

Types of deformity	No. of patients
Crooked nose	15
Saddle nose deformity	18
Hump deformity	10
Associated deviated nasal septum	32
Deformities of tip	15
Open roof deformity	2

Table III :
Surgical procedures

Procedure	No. of patients	Procedure	No. of patients
Septoturbinoplasty	35	Dorsal augmentation	23
Humpectomy	10	Nasal base reduction	11
Tip plasty	15	Spreader graft	38
Supra tip plasty	12	Osteotomy	37
Collumelar strut	42	Alar rim graft	03

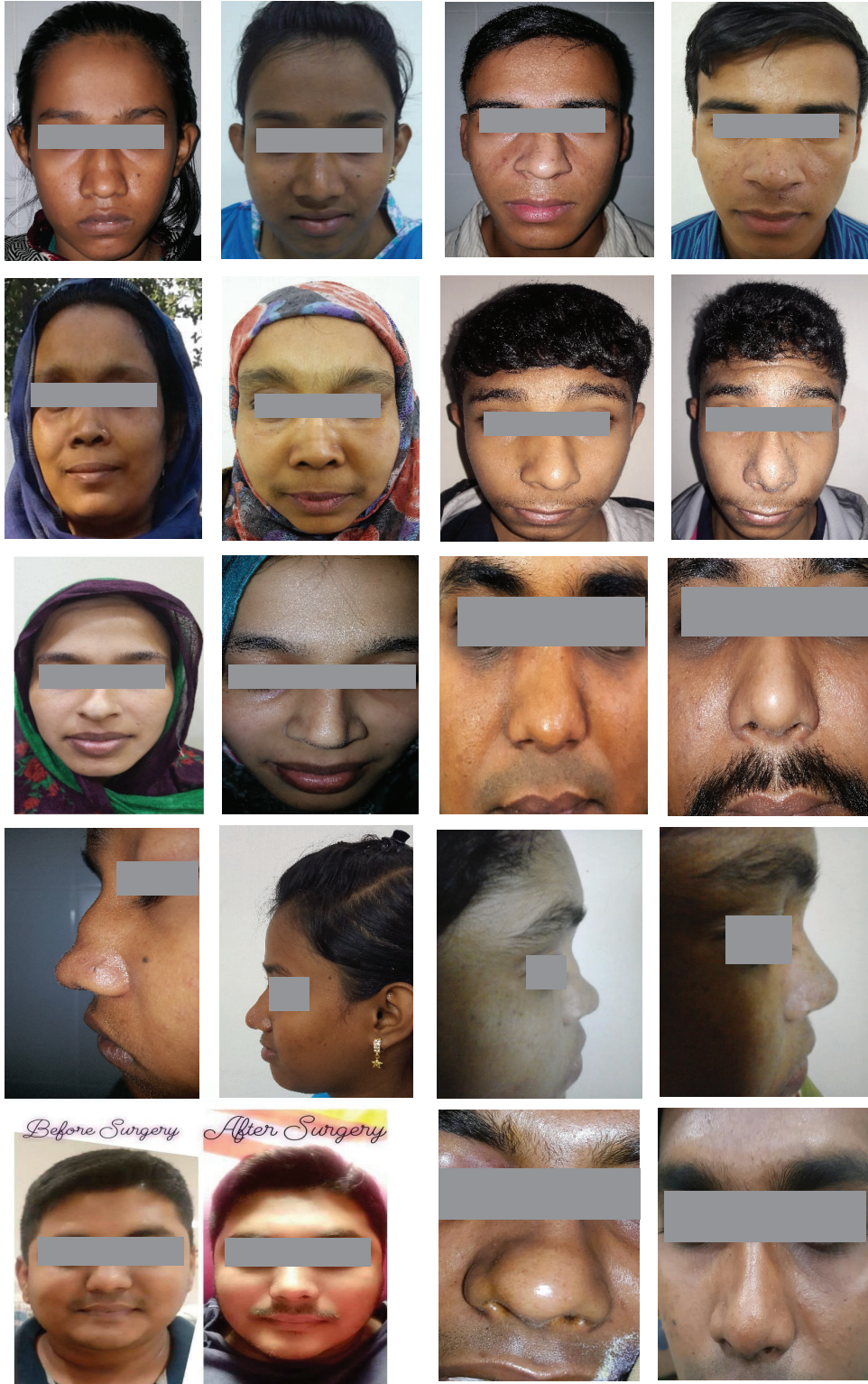Associated septal deviations necessitating corrections in 35 out of 50 patients along with other procedures and rest required other different nasal corrections. 38 patients required spreader graft, 37 required osteotomy, 23 required augmentation and 15 required tip plasty techniques during the surgery for adequate corrections to be achieved (Table III).

11 patients under went closed rhinoplasty surgeries using marginal and Intercartilaginous incisions and open rhinoplasty had to be performed in 39 cases. Septal, choncal and costal cartilage were used as graft in different procedures. Mean hospital stay was 07 days. Splints were used in all patients after surgery. Commercial external nasal splints were used in 37 patients and POP cast splints in 13 patients. There were no difference in the post-operative outcome between the patients in terms of types of splints were used, however patients' satisfaction concerned with splints and immediate post-operative aesthetic appearance as per patients comfort were poor with POP cast splints. There were some intraoperative and post-operative complications noticed among our cases that includes

haemorrhage, Periorbitalechymosis and oedema. However, short term anesthesia over nose was seen in 3 patients which resolved by 3–4 weeks in the post-operative period.

2 patients did present to us with persistent swelling and edema over nasal dorsum which persisted more than 12 weeks and took longer to resolve. All these patients got resolution of their persistent edema in due course of time. Patients' satisfaction levels from the procedures were routinely documented in the post op visits as completely satisfied, partially satisfied and not satisfied at all. 42 patients were satisfied with the results, 6 patients being partially satisfied and 2 were not satisfied at all. Patients who had shown no satisfaction with the results were advised for revision surgeries however none of those patients had consented for a revision surgery. Donor site morbidity was not reported among the cases.

Comparative study before and after rhinoplasty shows significant improvement and patients satisfaction in both external deformity with deviated nasal septum and external nasal deformity without deviated nasal septum.



Discussion:

Trauma accounted for most causes of nasal deformity⁹, with other causes being congenital, developmental, prior nasal surgery, infective etc. In our series the majority was traumatic patients including road traffic accident and sports injury (12%+28%= 40%). Due to military service pattern sports injury is more common than road traffic accident. Crooked nose and saddle nose deformity being found the commonest deformity. Crooked nose deformity was associated with developmental and sports injury also. Besides the obvious cosmetic defect, patients with crooked nose frequently have troublesome nasal obstruction due to the narrowed airway

Open rhinoplasty gives the possibility to assess anatomical deformities, asymmetries and structural alterations by direct inspection of the nasal framework. The structures of the nose can be manipulated in a more precise manner and sutures and grafts can be placed and fixed adequately.

Open surgical technique does produce increased supra tip edema than closed rhinoplasty¹⁰ but use of both hands for leads make the work easy and provides better results in the surgical process.¹¹ The scar of the skin incision is invisible in the majority of cases if the precise technique is performed.¹² In the view of this we followed open rhinoplasty rather than closed one in 78% cases without any major post-operative complications. Medial osteotomy combined with lateral osteotomy facilitates medialization of the lateral nasal wall, thus achieving open roof closure, as well as effective narrowing of the wide nasal base, even in the absence of a hump.^{5, 16}

To improve and maintain the nasal airway we used spreader graft in all open technique

because it helps to prevent narrowing of internal nasal valve, preserve the dorsal aesthetic lines, and stabilize the septum.^{13,14}

Foda¹⁵ documented his complication rates as follows: septal flap tear 2.8%, alar cartilage injury 1.8%, post-operative nasal trauma 1%, epistaxis 2%, infection 2.4%, prolonged edema 17%, nasal obstruction 0.8%, and unsightly transcolumellar scar 0.8%. We had Epistaxis 4(8%), periorbital oedema 10(20%), ecchymoses of eye 5(10%), Crusting 1(2%) and Synechiae 3(6%). No major life threatening complication was seen.

Foda¹⁵ documented patient's satisfaction 95.6% and in our series 84% were completely satisfied and 12% were partially satisfied which similar to Foda. Satisfaction is variable from person to person and depends on primary deformity, primary or revision surgery, mental state and realistic expectation. Next photographs shows few of our pre-operative and post-operative outcome.

Conclusion:

Rhinoplasty being a cosmetic surgery is of utmost importance, it has become an attractive and fascinating surgery for the otolaryngologists and plastic surgeons. It's a highly individualised problem specific operation that combines augmentation with reduction. The proportion of the so called ideal nasal shape and the operation to achieve this have been the subject of extensive training and surgical skill. Results differ with the each individual with their configuration, their healing properties and, psychological uptake. Preoperative counselling with the patient and close relatives or friends is most important to overcome the unrealistic expectations.

References:

1. Sorta-Bilajac I, Muzur A. The nose between ethics and aesthetics: sushruta's legacy. *Otolaryngology—head and neck surgery : official journal of American Academy of Otolaryngology- Head and Neck. Surgery* 2007; 137(5):707–710
2. Whitaker IS, Karoo RO, Spyrou G, Fenton OM. The birth of plastic surgery: the story of nasal reconstruction from the Edwin Smith Papyrus to the twenty-first century. *Plast Reconstr Surg* 2007; 120(1):327–336
3. Guyuron B. Precision rhinoplasty. Part I: the role of lifesize photographs and soft-tissue cephalometric analysis. *Plast Reconstr Surg* 1988; 81(4):489–499
4. Zijlker TD, Vuyk H, Adamson PA. Rhinoplasty: preoperative photographic analysis. *Clin Otolaryngol Allied Sci* 1992; 17(4):361–369
5. Ghanaatpisheh M, Sajjadian A, Daniel RK. Superior rhinoplasty outcomes with precise nasal osteotomy: an individualized approach for maintaining function and achieving aesthetic goals. *Aesthetic Surg J Am Soc Aesthetic Plast Surg* 2015; 35(1):28–39
6. Guyuron B. Dynamic interplays during rhinoplasty. *Clin Plast Surg* 1996; 23(2):223–231
7. Guyuron B. Dynamics in rhinoplasty. *Plast Reconstr Surg* 2000;105(6): 2257–2259
8. Sajjadian A, Guyuron B. Primary rhinoplasty. *Aesthetic Surg J Am Soc Aesthetic Plast Surg* 2010; 30(4):527–539 (quiz 540)
9. Hoffmann JF. Management of the twisted nose. *Operative techniques in otolaryngology—head and neck surgery*, 1999; 10: 232-37
10. Sporri S, Simmen D, Briner HR, Jones N. Objective assessment of tip projection and the nasolabial angle in rhinoplasty. *Arch Fac Plast Surg* 2004; 6(5):295–298 (discussion 299-300)
11. Petropoulos I, Karagiannidis K, Kontzoglou G. Our experience in open rhinoplasty. *Hippokratia* 2007; 11(1):35–38
12. Constantian MB. Differing characteristics in 100 consecutive secondary rhinoplasty patients following closed versus open surgical approaches. *Plast Reconstr Surg* 2002; 109(6):2097–2111
13. Sheen JH. Tip graft: a 20-year retrospective. *Plast Reconstr Surg* 91(1):48–63
14. Sajjadian A, Rubinstein R, Naghshineh N (2010) Current status of grafts and implants in rhinoplasty: part I Autologous grafts. *Plast Reconstr Surg* 1993; 125(2):40e–49e
15. Foda HMT. External rhinoplasty: A critical analysis of 500 cases. *J Laryngol Otol* 2003; 117: 473-77
16. Harris MO, Baker SR. Management of the wide nasal dorsum. *Arch Facial Plast Surg* 2004; 6:41–48.