

## Original Article

# Ultrasonographic Evaluation of Solitary Thyroid Nodule with Histopathological Comparison

Samia Quadir<sup>1</sup>, Sabiha Quadir<sup>2</sup>, Md. Momin Uddin<sup>3</sup>, Kazi Shameemus Salam<sup>4</sup>,  
Mohammad Sazzad Hossain<sup>5</sup>, Md. Rued Hossain<sup>6</sup>

### Abstract:

**Background:** Thyroid gland is the largest gland of the body which secretes thyroid hormones named  $T_3$  &  $T_4$ . Incidence of solitary thyroid nodule is common in Bangladesh.

**Objectives:** To validate the ultrasonography evaluation of solitary thyroid nodule comparing with histopathological diagnosis.

**Methodology:** This cross sectional study enrolled 75 patients of age range between 14 to 72 years during July 2016 to June 2018 and the study was carried out in the department of Radiology & Imaging of Ultrasonography evaluation was finally compared with histopathological diagnosis which was considered as gold standard.

**Results:** Among 75 patients are included in this study the age ranged between 14 to 72 years. Majority of the patients 37 (49.3%) were found between 31 to 40 years. 65 (86.3%) were female & 10 (13.3%) were male. All patients were presents with thyroid swelling. In USG findings Microcalcifications were present 9 (12%) in benign & 5(6.7%) in malignant cases. Presence of Halo were in all benign cases 14 (18.7%). Comet tail sign were in 5 (6.7%) in benign & 3 (4%) in malignant cases. Histological nodular goiter were 57 (76%), Follicular adenoma 8 (10.7%), Thyroiditis 5 (6.7%) and Papillary carcinoma 4 (5.3%), Follicular Carcinoma 1 (1.3%).

**Conclusion:** This cross sectional study was carried out with an aim to determine the usefulness of ultrasonogram diagnosis of solitary thyroid nodule compared with histopathology findings. As the validity test results are higher, it can be concluded that the ultrasonogram is a useful diagnostic modality in the evaluation of solitary thyroid nodule.

**Keywords:** Ultrasonography, Solitary thyroid nodule.

1. MD (Radiology & Imaging), SSMC & Mitford Hospital, Dhaka.
2. Assistant Professor, Dept. of Radiology & Imaging, Chattagram Medical College.
3. Classified ENT Specialist & Head-Neck Surgeon, CMH, Jashore Cantonment.
4. Associate Professor, Dept. of Otolaryngology-Head & Neck Surgery, BSMMU, Dhaka.
5. Assistant Professor, Dept. of Radiology & Imaging, SSMC & Mitford Hospital, Dhaka.
6. Prof. Dr. Md. Rued Hossain, Professor & Head, Dept. of Radiology & Imaging, SSMC & Mitford Hospital, Dhaka.

**Address of correspondence:** Dr. Samia Quadir, MD (Radiology & Imaging), SSMC & Mitford Hospital, Dhaka, Mobile: 01716-340726, E-mail : drsamiaquadir@gmail.com

### Introduction:

Thyroid is the largest endocrine gland of the body which secretes thyroid hormone named  $T_3$  and  $T_4$ . This hormone is one of the important hormones of the body and have an essential role in metabolism. Without proper functioning of this hormone, there is disruption of this rhythm and cause dysfunction of organs and organ systems.<sup>1</sup>

The gland is affected by pathological lesion of varied morphology, which can be divided into two types which shows the diffuse pattern and that produce nodules. Diffuse thyroid lesions are mostly associated with non-neoplastic lesions affecting the gland.

Nodular lesions comprise disorders that consist of non-neoplastic nodules as well as benign and malignant.<sup>2</sup>

Thyroid nodules (TN) are common in general population and one of the commonly encountered problem in day-to-day clinical practice though it is more commonly found in women.<sup>3</sup> According to the American Thyroid Association (ATA) Guidelines, a thyroid nodule (TN) is a discrete lesion within the thyroid gland that is radiologically distinct from the surrounding thyroid parenchyma. Nonpalpable nodules are often found when patients undergo diagnostic imaging such as ultrasonography and computed tomography of the chest and neck. For these incidentalomas, current guidelines recommend the same diagnostic strategy that is recommended for palpable nodules.<sup>4,5</sup> Although the risk of malignancy in any given solitary nodule (less than 1 cm) is small, thyroid cancer must be considered in the differential diagnosis. But despite benign in nature of this nodule it is stressful for the patients being diagnosed as a case of solitary thyroid nodule.<sup>6,7</sup>

Statistics evidence showed that palpable thyroid nodules occur in 4–8% of the population and in 13–67% nodules found incidentally during ultrasound (US).<sup>8</sup> And about 5% of the clinically apparent thyroid nodules are malignant, while nonpalpable nodules have the same risk of malignancy as palpable nodules of the same size.<sup>9</sup> In Whickham survey from England palpable thyroid nodule noted in 0.8% of male and 3% of female.<sup>10</sup> These figures present only tip iceberg, because when ultrasonography is done in patients with clinically apparent normal thyroid, nodule is detected 30–50% of adult gland. In the Framingham study, the lifetime risk of developing a thyroid nodule was estimated to be 5–10%. The author found that more than two thirds of the nodules are solitary.<sup>11</sup> Actually, the proportion

of malignant nodules becomes higher which reaches 5–15%.<sup>12,13</sup> Some of this increase may be due to advances in diagnostic tools, including high-resolution ultrasonography and computed tomography, allowing for greater detection of thyroid nodules, which may not have been detected before. However, important changes in the intrinsic characteristics of the general population are also assumed to be involved.<sup>14,15</sup>

Thyroid nodule is also common in Bangladesh. The retrospective study done among the thyroid patients attending the thyroid clinic running jointly by the Institute of Nuclear Medicine (INM) and Institute of Post-Graduate Medicine and Research (IPGM&R), shows that about 32.67% of thyroid patients present with solitary thyroid.<sup>16</sup> Solitary nodules consists of a heterogeneous group of disorders such as colloid nodules, adenomas, thyroiditis and simple cysts. More recent studies have indicated that majority of the thyroid nodules are truly tumors and of clonal origin.<sup>17</sup> Solitary Thyroid Nodules (STN) are common but malignancy is rare, only 5–6% of STN are malignant. However thyroid carcinoma is common malignancy of the endocrine system. Thyroid cancer accounts for 1.5% of all cancers, Malignancy may arise from follicular epithelial cells as papillary (70–80%), follicular (10%) and anaplastic carcinoma (5%), from parafollicular (C-cell) as medullary carcinoma of thyroid (5–10%) and others as lymphoma and secondary from kidneys, breast, lungs, upper gastro intestinal tract and larynx (5%). All are common in females, except medullary carcinoma which occur equally in both sexes.<sup>18</sup>

The critical issue is to determine whether it is benign or malignant. The presence of malignant nodule would necessitate primary surgical therapies whereas a benign nodule can be managed conservatively. For that, thyroid nodule always present diagnostic problems in all age groups as because when all palpable nodules are resected, cancers

are diagnosed only in 10% cases<sup>19</sup>. Although a significant amount of patients suffering from thyroid.

**Methods:**

This cross-sectional study was carried out in the department of Radiology and Imaging of Sir Salimullah Medical College and Mitford Hospital, Dhaka total 75 patients who were referred to Radiology and Imaging department by E.N.T department of Sir Salimullah Medical College and Mitford Hospital, Dhaka as a clinically suspected solitary thyroid nodule for USG of neck, during the period July 2016 to June 2018. Prior to the commencement of this study, the research protocol was approved by the Institutional Review Board of SSMC. Dhaka. It was assured that all information and records would be kept confidential and the procedure would be helpful for both the pathologist and the patients in the making rational approach of the case management.

**Results:**

Among 75 patients included in this study the age ranged between 14-72 years. Mean age was 37.02±10.67 (mean±SD) years. Majority of the patients (49.3%) were found between 31- 40 years. Six (8%) patients were found below 20 years of age. There were male 10 (13.3%) and female 65 (86.7%)

**Table I :**  
*Age distribution of the study participants (n=75)*

Age in years	Frequency	Percentage (%)	Mean±SD
<20	6	8.0	
21-30	10	13.33	
31-40	37	49.34	37.02±10.67
41-50	15	20	
51-60	6	8.0	
>60	1	1.33	
Total	75	100.0	

Maximum (49.3%) participants of this study belonged to age group 31 to 40 years followed by 20.0% belonged to 41 to 50 years, 13.3% within 21 to 30 years, 8% within 51 to 60 years and below 20 years. Only 1.3% of each was belonged to extreme age group that is more than 60 years. Mean (±SD) age of the participants was 37.02±10.67 and all participants were within 14 to 72 years age range.

**Table II :**  
*Sex distribution of study participants (n=75)*

Sex	Frequency	Percentage (%)
Male	10	13.3
Female	65	86.7
Total	75	100.0

Out of all participants, 13.3% were male and 86.7% were female. Male and female ratio was 1:6.5.

**Table III :**  
*Distribution of Presenting Complaints (n=75)*

Presenting Complaints	Frequency	Percent
Thyroid swelling	75	100
Pain*	09	12
Dysphagia*	06	08
Hoarseness of voice*	05	6.7

\*multiple response or features along with thyroid swelling

Table shows the different presenting complaints of the participants and all the participants had complaint of thyroid swelling

(100%) followed by in decreasing order by pain (12%), dysphagia (8%) and hoarseness of voice (6.7%).

**Table IV :**  
*Distribution of local examination findings of the participants (n=75)*

Local Examination	Frequency (n)	Percent (%)
Size of the thyroid gland		
• Enlarged	75	100.0
Consistency		
• Soft	22	29.3
• Firm	45	60.0
• Hard	8	10.7
Tenderness		
• Tender	09	12.0
• Non-tender	66	88.0
Move with deglutition	75	100.0
Any palpable cervical lymph nodes	8	10.7

**Table V :**  
*Distribution of the ultrasound findings of the thyroid gland (n=75)*

Ultrasound finding	Frequency	Percent
Position of the nodule		
• Right lobe	51	68.0
• Left lobe	24	32.0
Margins of nodule		
• Regular	68	90.7
• Irregular	07	9.3
Micro calcification	14	18.7
Presence of Halo	14	18.7
Comet tail sign	08	10.7
Ultrasound findings consistent with		
• Benign	68	90.7
• Malignant	07	9.3

**Table VI :**  
*USG findings of benign and malignant solitary thyroid nodule (n=75)*

Ultrasound findings	Benign (n=68) n (%)	Malignant (n=7) n (%)	Total (n=75) n (%)
Position of the nodule			
• Right lobe	46 (61.3)	5 (6.6)	51 (68.0)
• Left lobe	22 (29.3)	2 (2.6)	24 (32.0)
Margins of nodule			
• Regular	65 (86.7)	3 (4.0)	68 (90.7)
• Irregular	3 (4.0)	4 (5.3)	7 (9.3)
Micro calcification	9 (12.0)	5 (6.7)	14 (18.7)
Presence of Halo	14 (18.7)	0 (0)	14 (18.7)
Comet tail sign	5 (6.7)	3 (4.0)	8 (10.7)

**Table VII**  
*Distribution of the respondents by histopathological findings (n=75)*

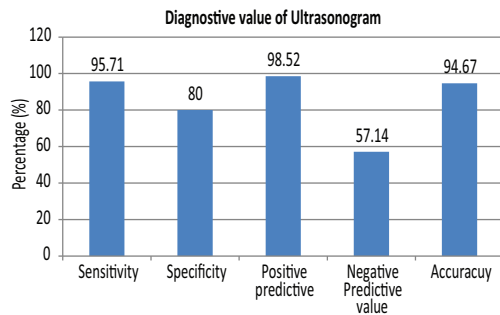
Histopathological findings	Frequency	Percent
Benign		
• Nodular goiter	57	76
• Thyroiditis	5	6.7
• Follicular adenoma	8	10.7
Malignant		
• Papillary	4	5.3
• Follicular	1	1.3

**Table VIII:**  
*Comparison of ultrasound evaluation with histopathological diagnosis of thyroid nodule (n=75)*

USG findings	Histopathological diagnosis		Total
	Benign	Malignant	
Benign	67 (TP)	1 (FP)	68
Malignant	3 (FN)	4 (TN)	7
Total	70	5	75

TP = True positive; FP = False positive; FN = False negative; TN = True negative

Among 67 cases, were diagnosed as having benign nodule by USG and confirmed by histopathological evaluation. They were true positive. One case was diagnosed as having benign by USG which came out to be malignant in histopathological examination. They were false positive. USG diagnosed 7 cases as malignant. Histopathology revealed 3 of them as benign and 4 of them as malignant. They were false negative and true negative respectively.



**Fig. 7:** Diagnostic value of ultrasonogram in the differentiation of thyroid nodule

Sensitivity of USG in differentiation of thyroid nodule was 95.71%, specificity 80%, positive predictive value (PPV) 98.52%, negative predictive value (NPV) 57.14% and accuracy 94.7%.

**Discussion:**

Total 75 patients of thyroid enlargement were included in the study. Mean age of the study participants was 37.02 ±10.67 years ranging from 14-72 years. Majority patients (49.34%) belonged to age group 31 – 40 years. This is concordant with the findings of other studies involving solitary thyroid nodule done in Bangladesh by Khan *et al.*<sup>20</sup> and Akhter *et al.*<sup>21</sup> Khan *et al.*<sup>20</sup> in their study found that out of 118 patients 54 were aged between 30 – 40 years. Akhtar *et al.*<sup>21</sup> and her team

found 42% patients belonging to age group 31 – 40 years.

Majority patients were female in this study constituting 86.7% of the study population. The ratio between male and female of the study group was 1: 6.5. Similarly, Akhter *et al.*<sup>21</sup> found a male-female ratio of 1:7.3 in their study and Khan *et al.*<sup>20</sup> found a male-female ratio of 1:3.15 in the 30 -40 year age group in their study. Other age group also had more than double females than males in the study by Khan *et al.*<sup>20</sup> and colleagues.

Local examination of 75 patients showed that all of the patients had thyroid swelling (100%) which moves with deglutition, 12% had pain, 8% had dysphagia and 6.7% had hoarseness of voice. Khan *et al.*<sup>20</sup> found swelling in the neck 100% cases, dysphagia in 1.69% cases and hoarseness of voice in 0.85% cases, which is similar to this study.

Consistency of the nodules was firm in majority cases (60%), soft 29.3% cases, and hard 10.7% cases. Similarly Rahimi *et al.*<sup>22</sup> found 63.8% benign nodules as soft and cystic and 36.2% of them being solid (hard).

In the present study 68% nodules were in the right lobe and 32% were in the left lobe. Khan *et al.*<sup>20</sup> also found right lobe to be the prominent site (55%) cases along with left lobe in 50% cases.

Margin of the nodules were regular in 90.7% cases and irregular in 9.3% cases. Rahimi *et al.*<sup>22</sup> enlisted a similar picture where 96.9% of the benign nodules were regular and 3.1% were irregular.

Ultrasound findings were consistent with benign nodule in 90.7% cases and with malignant nodule in 9.3% cases. In comparison Teja *et al.*<sup>23</sup> found 68.3% benign and 31.7% malignant nodule in ultrasonography of thyroid nodules.



Out of 75 cases of present study, 95.6% benign tumor had regular and 4.4% had irregular margin and 42.9% malignant nodule had regular and 57.1% had irregular margin. Thapa.<sup>24</sup> showed that 95% benign nodule had with well-defined margin and 90% of malignant nodule had poorly defined margin. Result of this study is lower than Thapa's<sup>24</sup> findings in case of malignancy but higher than Rahimi's<sup>22</sup> findings. Rahimi, *et al.*<sup>22</sup> found 57.1% malignant nodules having regular and 42.9% having irregular margin.

In this study revealed 12.0% benign and 6.7% malignant nodule had microcalcification. Cappelli *et al.*<sup>25</sup> In a study we found that the microcalcifications were significantly more frequent in malignant lesions than in benign nodules (72.2 vs 28.7%). This is similar to the findings of this study. Thapa.<sup>24</sup> showed that among the various sonographic features microcalcification had the highest accuracy (76.0%) for the diagnosis of malignant lesion. Out of 82 benign lesions, calcification was present in 20 cases in their study and among them 65.0% were microcalcification.

In the present study out of all, 93.3% had benign and 6.7% had malignant lesion on histopathologic evaluation. In. Martínek *et al.*<sup>26</sup> series 77.0% were benign and 23.0% were malignant in the histopathology of the resected thyroid nodules, which is comparable with findings of this study. Nggada *et al.*<sup>27</sup> also found 73.9% benign cases and 26.1% malignant cases in their series and Teja *et al.*<sup>23</sup> found 68.3% benign and 31.7% malignant cases. Compared to other studies the present study found more benign cases.

In the present study out of all benign nodule 10.7% were follicular adenoma, 6.7%

thyroiditis, and 76 nodular goiter in histopathology and among malignant lesions 6.7% were papillary carcinoma and 1.3% were follicular carcinoma. In comparison Akhtar *et al.*<sup>21</sup> Khan *et al.*<sup>20</sup> found 24% cases of follicular adenoma and 12% cases of papillary carcinoma. Khan *et al.*<sup>20</sup> found 44% colloid nodule, 2.54% thyroiditis and 12.71% papillary carcinoma.

Out of 75 patients halo sign was present in 18.7% cases and all of this nodules were benign. In Thapa,<sup>24</sup> series all found 25.8% of benign cases had thin peripheral halo.

In the present study the sensitivity of USG to diagnose benign thyroid nodule was 95.71%, specificity 80%, positive predictive value 98.2% negative predictive value 57.14% and accuracy 94.7%. In a study Stacul *et al.*<sup>28</sup> correlated the diagnosis of thyroid nodules with histopathological findings and found the similar results our study sensitivity, specificity and PPV, NPV and overall accuracy values of the grey scale ultrasound of their series were 46%, 73%, 34%, 82% and 67% respectively, for solitary thyroid nodules. One hundred twenty patients undergone thyroid surgery for thyroid nodules or goiter were examined by preoperative ultrasound and fine needle aspiration cytology by Watters *et al.*<sup>29</sup> In their study they found in the determination of type of lesion ultrasound had sensitivity, specificity, and PPV of 74%, 83% and 51% respectively, that is also consistent with our study.

### Conclusion:

This cross sectional study was carried out with an aim to determine the usefulness of ultrasonogram diagnosis of solitary thyroid nodule was compared with histopathology findings. As the validity test results are higher,

thus it is evident that the USG useful diagnostic modality in the evaluation of solitary thyroid nodule.

**References:**

1. Mullur R, Liu Y and Brent GA. Thyroid Hormone Regulation of Metabolism. *Physiol Rev* 2014; 94: 355-82.
2. LiVolsi V. Pathology of thyroid disease. 14th edition, Philadelphia PA 1997; Lipincott-Raven Publishers.
3. Durante C, Costante G, Lucisano G, Bruno R, Meringolo D, Paciaroni A, Puxeddu E, Torlontano M, Tumino S, Attard M, Lamartina L. The natural history of benign thyroid nodules. *JAMA* 2015 Mar 3;313(9): 926-35.
4. Gharib H, Papini E, Valcavi R, Baskin HJ, Crescenzi A, Dottorini ME, Duick DS, Guglielmi R, Hamilton JC, Zeiger MA, Zini M. American Association of Clinical Endocrinologists and Associazione Medici Endocrinologi medical guidelines for clinical practice for the diagnosis and management of thyroid nodules. *Endocrine practice: official journal of the American College of Endocrinology and the American Association of Clinical Endocrinologists*. 2006; 12(1):63-102.
5. Cooper DS, Doherty GM, Haugen BR, Kloos RT, Lee SL, Mandel SJ, Mazzaferri EL, McIver B, Pacini F, Schlumberger M, Sherman SI. Revised American Thyroid Association management guidelines for patients with thyroid nodules and differentiated thyroid cancer: the American Thyroid Association (ATA) guidelines taskforce on thyroid nodules and differentiated thyroid cancer. *Thyroid*. 2009 Nov 1; 19(11):1167-214.
6. Papini E, Guglielmi R, Bianchini A, Crescenzi A, Taccogna S, Nardi F, Panunzi C, Rinaldi R, Toscano V, Pacella CM. Risk of malignancy in nonpalpable thyroid nodules: predictive value of ultrasound and color-Doppler features. *The Journal of Clinical Endocrinology & Metabolism*. 2002 May; 87(5):1941-6.
7. Knox M. Thyroid Nodules. *Am Fam Physician* 2013; 88(3): 193–96.
8. Yeung MJ, Serpell JW. Management of the solitary thyroid nodule. *The oncologist* 2008 Feb;13(2):105-12.
9. Hagag P, Strauss S and Weiss M. Role of ultrasound-guided fine-needle aspiration biopsy in evaluation of nonpalpable thyroid nodules. *Thyroid* 1998; 8(11): 989–95.
10. Vanderpump MP. The epidemiology of thyroid disease. *British medical bulletin* 2011 Sep 1; 99(1).
11. Vander JB, Gaston EA, Dawber TR. The significance of nontoxic thyroid nodules: final report of a 15-year study of the incidence of thyroid malignancy. *Annals of internal medicine* 1968 Sep; 69(3):537-40.
12. Pacini F, Schlumberger M, Dralle H, Ilisea R, Smith Y, Viersinga V. European consensus on the management of patients with differentiated carcinoma of the thyroid from follicular epithelium. *Vestnik khirurgii imeni II Grekova* 2008;167(1):52.
13. Mendel SA. 64 Years Old Woman With a Thyroid Nodule. *JAMA* 2008; 293(9): 1107–14.

14. Davies L, Welch HG. Increasing incidence of thyroid cancer in the United States, 1973-2002. *JAMA*. 2006 May 10; 295 (18):2164-7.
15. Enewold L, Zhu K, Ron E, Marrogi AJ, Stojadinovic A, Peoples GE, Devesa SS. Rising thyroid cancer incidence in the United States by demographic and tumor characteristics, 1980-2005. *Cancer Epidemiology and Prevention Biomarkers*. 2009 Mar 1; 18(3):784-91.
16. Alam M, Haq S and Ansari M. Spectrum of thyroid disorders in IPGMR, *Bangladesh J Med*. 1996; 6: 53-58.
17. Fey MF, Peter HJ, Hinds HL, Zimmermann A, Liechti-Gallati S, Gerber H, Studer H, Tobler A. Clonal analysis of human tumors with M27 beta, a highly informative polymorphic X chromosomal probe. *The Journal of clinical investigation* 1992 May 1; 89(5):1438-44.
18. Melemgaard A, From G, Jorgense T, Johansen C, Olsen JH, Perril DH. Cancer risk in individuals with benign thyroid disorders. *Thyroid* 1998 Sep; 8(9):751-4.
19. James EM and Charboneau JM. Thyroid imaging, in C. Rumanck SW and Char JW, ed., *Imaging of thyroid disorders*. USA publishers 2000; 285-90.
20. Khan SA, Gafur MA, Khan MK, Karim MR, Mohiuddin M, Islam MS. Pattern of malignancy in clinically solitary thyroid nodule. *Mymensingh medical journal* 2012 Jan; 21(1):1-7.
21. Akhtar N, Buzdar MU and Khan MA. Frequency of malignancy in solitary thyroid nodule. *Pakistan Journal of Medical and Health Sciences* 2015; 9(3): 983-85.
22. Rahimi M, Farshchian N, Rezaee E, Shahebrahimi K, Madani H. To differentiate benign from malignant thyroid nodule comparison of sonography with FNAC findings. *Pakistan journal of medical sciences* 2013 Jan 1; 29(1):77.
23. Teja KR, Sakalecha AK, Hedge P, Suresh TN, Sreeramulu PN. Role of ultrasonography & color Doppler in the evaluation of thyroid nodules with histopathological correlation. *Journal of evolution of Medical and Dental Sciences* 2015 Feb 9;4(12):1970-85.
24. Thapa NB. Ultrasound in the diagnosis of neck masses. *Journal of Nepal Health Research Council* 2008; 30: 45-54
25. Cappelli C, Castellano M, Pirola I, Cumetti D, Agosti B, Gandossi E, Agabiti Rosei E. The predictive value of ultrasound findings in the management of thyroid nodules. *Journal of the Association of Physicians* 2007 Jan; 100(1):29-35.
26. Martinek A, Dvorackova J, Honka M, Horacek J, Klvana P. Importance of guided fine needle aspiration cytology (FNAC) for the diagnostics of thyroid nodules-own experience. *Biomed Pap Med Fac Univ Palacky Olomouc Czech Repub* 2004 Jul 1;148(1):45-50.
27. Nggada HA, Musa AB, Gali BM, Khalil MI. Fine needle aspiration cytology of thyroid nodules: A Nigerian tertiary hospital experience. *The internet journal of Cardiovascular Research* 2006.



- 28 Stacul F, Bertolotto M, De Gobbis F, Calderan L, Cioffi V, Romano A, Zanconati F, Cova MA. US, colour-Doppler US and fine-needle aspiration biopsy in the diagnosis of thyroid nodules. *La radiologia medica*. 2007 Aug 1;112(5):751-62.
- 29 Watters DA, Ahuja AT, Evans RM, Chick W, King WW, Li AK et al. Role of ultrasound in the management of thyroid nodules and thyroid cancer. *The American Journal of Surgery* 1999; 7(5): 654–57.