

Case Report

Complicated Paediatric Bronchial Foreign Body: A Novel Extraction Technique

Fathiyah Idris², Zaid Nailul Murad², Boon Chye Gan³, Khairul Bariah Noh⁴, Yeoh Xing Yi⁵, Ong Fei Ming⁶, Ng Siew Peng⁷, Zakaria Zahirrudin⁸, Goh Bee See⁹

Abstract:

A paediatric bronchoscopy procedure for foreign body inhalation is indeed a highly challenging procedure due to multiple risk factors such as lower physiological functional residual capacity and adverse pulmonary function effects by anaesthetic agents in addition to concurrent active lungs infection. Here we elucidate a novel technique of foreign body removal located at the distal airway in a paediatric patient and in a situation where a paediatric flexible bronchoscopy with built-in working channel is not available. A 1-year 7-months-old boy presented with acute respiratory distress syndrome following a one-week history of active respiratory infection. On examination, he was tachypnoeic with audible soft inspiratory stridor and intermittent barking cough despite being supplemented with 3 liters /minute oxygen mask. Chest x-ray showed right upper lobe collapse. He was referred to the otorhinolaryngology team after a suspicious history of foreign body aspiration obtained from his mother. Bedside flexible nasopharyngolaryngoscopy showed granulation tissue at the junction of laryngeal surface of epiglottis and anterior commissure. He underwent emergency direct laryngoscopy, tracheoscopy, bronchoscopy, excision of granulation tissue and removal of foreign body under general anaesthesia. Herein, some of complicated bronchoscopy demand critical thinking of alternative or modified techniques to achieve a successful and safe surgery.

Keywords: Foreign bodies; bronchoscopy; general anaesthesia; laryngoscopy

-
1. Department of Otorhinolaryngology-Head and Neck Surgery, University Kebangsaan Malaysia Medical Centre, Kuala Lumpur, Malaysia
 2. Department of Otorhinolaryngology-Head and Neck Surgery, Hospital Pulau Pinang, Jalan Residenci, 10990, Georgetown, Pulau Pinang, Malaysia.
 3. Department of Otorhinolaryngology-Head and Neck Surgery, Hospital Pulau Pinang, Jalan Residenci, 10990, Georgetown, Pulau Pinang, Malaysia.
 4. Department of Otorhinolaryngology-Head and Neck Surgery, Hospital Pulau Pinang, Jalan Residenci, 10990, Georgetown, Pulau Pinang, Malaysia.
 5. Department of Otorhinolaryngology-Head and Neck Surgery, Hospital Pulau Pinang, Jalan Residenci, 10990, Georgetown, Pulau Pinang, Malaysia.
 6. Department of Otorhinolaryngology-Head and Neck Surgery, Hospital Pulau Pinang, Jalan Residenci, 10990, Georgetown, Pulau Pinang, Malaysia.
 7. Department of Otorhinolaryngology-Head and Neck Surgery, Hospital Pulau Pinang, Jalan Residenci, 10990, Georgetown, Pulau Pinang, Malaysia.
 8. Department of Otorhinolaryngology-Head and Neck Surgery, Hospital Pulau Pinang, Jalan Residenci, 10990, Georgetown, Pulau Pinang, Malaysia.
 9. Department of Otorhinolaryngology-Head and Neck Surgery, Hospital Pulau Pinang, Jalan Residenci, 10990, Georgetown, Pulau Pinang, Malaysia.

Address of Correspondence: Dr. Fathiyah Idris, Department of Otorhinolaryngology-Head and Neck Surgery, University Kebangsaan Malaysia Medical Centre, Kuala Lumpur, Malaysia.
Cell: +60134711670, E-mail: fathiyah8289@gmail.com

Introduction:

Foreign body (FB) inhalation incidence was reported highest in 3 years old and younger children¹. This is attributed to their developmental achievements such as exploring their surrounding by mouthing, eating while playing and mature pincer grasp to collect even small objects. However, incomplete dentition and immature swallowing coordination predispose them to the risk of FB inhalation. In the cases of aspirated FB, 82% were witnessed by adults, 6% were associated with a suspicious history of ingesting a foreign body and 12 % were unwitnessed with no obvious ingestion history¹. Foods namely vegetables are the most common documented foreign bodies 83% and located predominantly in the right main bronchus 55%¹. This significant number of cases with predominant dislodgement in the lower airway reflecting the importance of conducting a risky yet successful and safe bronchoscopy procedure.

Case Report:

A 1-year 7-months-old boy with no previous medical illness presented with a one-day history of rapid and noisy breathing. It was associated with a week history of fever, prolonged cough and reduced oral intake. However, the mother only sought medical treatment after the child developed rapid and noisy breathing. He was referred to the otorhinolaryngology (ORL) team for airway evaluation after further history taking revealed a suspicious history of choking episode during eating banana one day before the admission. On examination, the child was feverish, mildly dehydrated, tachypnoeic with mild subcostal recession. He required 3 Liters/minute oxygen mask supplement as his oxygen saturation was only able to maintain about 85% under room air. He had barking coughs, hoarseness with audible soft inspiratory stridor. Lung

auscultation revealed intermittent ronchi. Cardiovascular and abdominal examination was unremarkable. Otherwise, the child was haemodynamically stable. He was given intravenous (IV) dexamethasone, adrenaline nebulization, budesonide nebulization, metered-dose inhaler (MDI) salbutamol. Chest X-ray (CXR) showed right upper lobe collapse. Bedside flexible nasopharyngolaryngoscopy was arranged in the Paediatric Intensive Care Unit (PICU) collaborated with the paediatric team. The endoscopy revealed granulation tissue located at the junction of the laryngeal surface of epiglottis and anterior commissure (Figure 1).

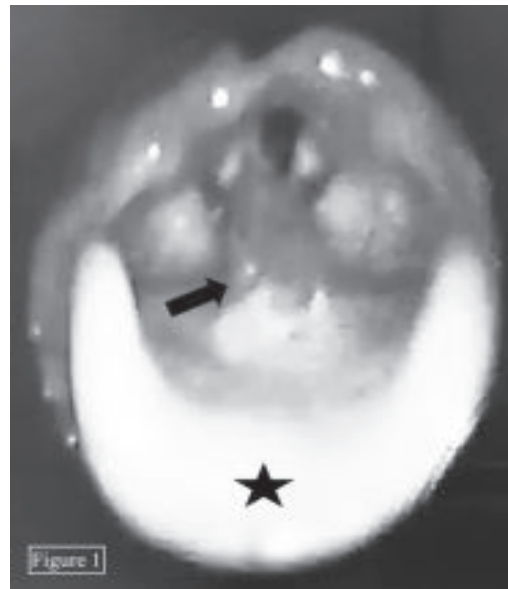


Figure 1: An endoscopic view of a granulation tissue (arrow) located at the junction of laryngeal surface of epiglottis (epiglottis marked by star shape) and anterior commissure during bedside flexible nasopharyngolaryngoscopy.

He underwent emergency direct laryngoscopy, tracheoscopy, bronchoscopy and excision of granulation tissue under general anaesthesia.

Anaesthesia was induced with an inhalational volatile agent (Sevoflurane). Vocal cords were sprayed with topical anaesthesia (2% lignocaine) under direct visualization with direct laryngoscopy before tracheoscopy with a rigid telescope. Unfortunately, the patient developed laryngospasm. Airway management was taken over by the anaesthetist and anaesthesia was deepened with IV Fentanyl, IV Propofol and IV Rocuronium. The patient was intubated with a non-cuffed endotracheal tube (ETT) size 4.0 to protect the airway and maintain the oxygenation. Then, suspension laryngoscopy was fitted. Subsequently, catheter mount was disconnected from the ETT and a 2.7mm 0° Hopkins rod telescope was introduced through the ETT and advanced distally until the level of the carina. Another granulation tissue was visualized situated at the right upper lobe secondary bronchus (Figure 2).

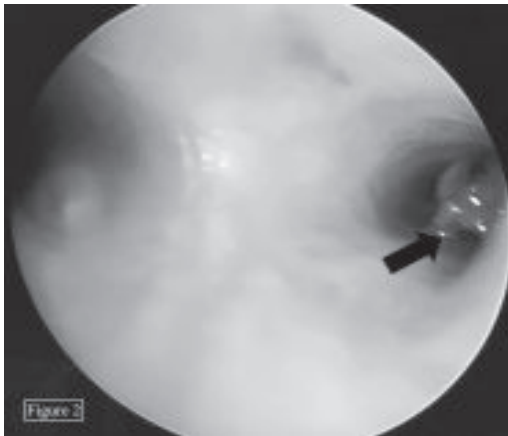


Figure 2: An endoscopic view of the foreign body (arrow) located in the right upper lobe secondary bronchus during flexible broncho-scopy.

The patient suddenly desaturated at this juncture. Therefore, the rigid telescope was withdrawn and the ETT was reconnected to the ventilation circuit. With the ETT in situ, the previously visualized supraglottic granulation tissue was excised. After achievement of good oxygen saturation, the catheter mount was disconnected from the ETT again and the rigid telescope was

reinserted into the ETT lumen. The rigid telescope was withdrawn along with the ETT to inspect the airway of the subglottic and proximal trachea which were not seen as planned previously due to the desaturation during initial direct laryngoscopy. There were no other sites of granulation tissue or abnormality noted during the tracheoscopy. The patient was then reintubated with an ETT size of 3.5mm. A 2.5 mm neonate flexible nasopharyngolaryngoscopy was employed along with flexible grasping forcep due to the unavailability of flexible bronchoscopy with a built-in working channel in our centre. With the aid of suspension laryngoscope, both instruments were first inserted sideways to the ETT and then advanced distally until the grasping forcep seen reached the granulation tissue. The flexible nasopharyngo-laryngoscope was pulled out while the grasping forcep was kept in situ. The flexible nasopharyngo-laryngoscope inserted into the ETT via the catheter mount opening then was advanced distally to optimize the view of the foreign body. With proper visualization, we noticed that the granulation tissue was partially surrounded a foreign body. The foreign body with the granulation tissue was completely extracted using the grasping forcep (Figure 3).

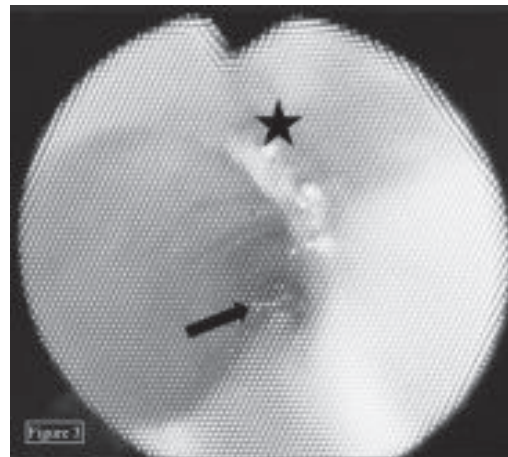


Figure 3: An endoscopic view showing the grasping forceps (arrow) was introduced sideways to the ETT. The tip of ETT indicated by the star shape.

The forcep was withdrawn together with the ETT under endoscopic visualization due to relatively large foreign body size. The foreign body was a piece of plastic toy with sharp ends measuring about 1.6 cm in length (Figure 4).

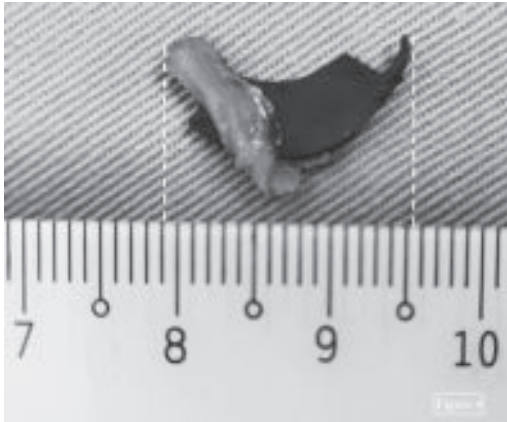


Figure 4: The foreign body (a plastic toy piece), partially enveloped by granulation tissue measuring about 1.6 cm in length completely removed.

Rigid tracheoscopy was reperformed looking for any post-operative complications. Finally, the patient was re-intubated with size 4 non-cuffed ETT under rigid endoscopic guidance. He was sent to PICU for post-operative care. He was kept intubated and covered with IV Cefepime 50mg/kg every 8 hourly, IV Dexamethasone 0.2mg/kg every 6 hourly and Budesonide nebulization. He responded well to the treatment given and stable during the weaning off process from the ventilator support. He was extubated 4 days after the procedure. He was discharged home 6 days post-operation with total resolution of his respiratory symptoms. A repeated CXR on the third-day post-operation showed expanded and clear bilateral lungs fields. Figure 5 shows the side view picture taken during simulation of the surgical procedure on a patient simulation mannequin to show the arrangement of the instruments.

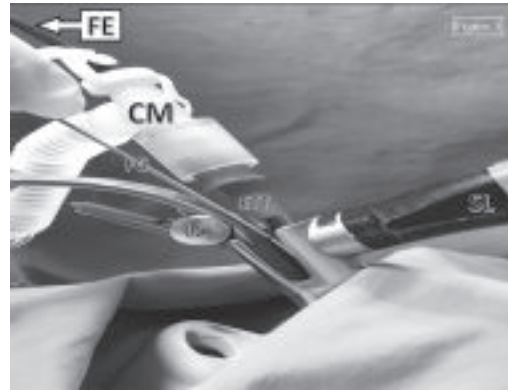


Figure 5: The flexible nasopharyngolaryngoscope (labelled as FE) inserted through the opening of the catheter mount (labelled as CM) which is readily connected to the ETT. The flexible grasping forceps (labelled as FG) introduced sideways to the endotracheal tube (labelled as ETT). A light clip (labelled as LC) was used for proximal illumination. The the suspension laryngoscopy system labelled as SL

Figure 6 shows The endoscopic view taken during simulation of the surgical procedure on a patient simulation mannequin at the level of laryngeal inlet to show the arrangement of the instruments.

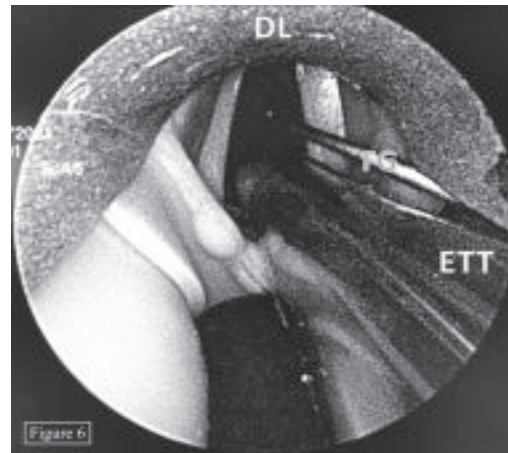


Figure 6: The direct laryngoscopy blade (labelled as DL) used to elevate the epiglottis. The flexible grasping forceps (labelled as FG) located sideways to the ETT were advanced to the distal airway. The endotracheal tube labelled as ETT

Discussion:

Extraction of inhaled FB in the paediatric group carries a significant risk of mortality². Children are prone to hypoxia due to their lower functional residual capacity (FRC), greater oxygen consumption, ineffective respiratory musculature, higher ventilation and perfusion (V/Q) mismatch and a highly compliant airway compared to the adult^{2,3}. In addition, general anaesthesia may adversely affect breathing control, bulbar function and patency of upper airway in a paediatric patient³. Undoubtedly it is a challenging procedure for both the ORL surgeon and the anaesthesiologist. Thus, a team approach is highly required between anaesthetist and ORL surgeon in the management of shared airway procedures.

Bronchoscopy is the cornerstone procedure for diagnosis and removal of inhaled foreign body^{4,6}. Rigid bronchoscopy is the standard choice as it allows better visualization, airway control, multiple instrumentations and simultaneous ventilation⁴. On the other hand, flexible bronchoscopy has the advantage of reaching a foreign body in the distal and smaller airway due to the smaller scope calibre^{5,6}. The higher flexibility of the scope allows good retrograde access such as in upper lobe bronchi⁶. Both instruments demonstrated high success rate in foreign body removal which are 97% and 91.3% in rigid bronchoscopy and flexible bronchoscopy respectively^{5,6}.

A few cases of modified extraction of foreign body techniques using both rigid and flexible bronchoscopy were reported. Mohd Nazir Othman et al described an extraction technique of an aspirated tooth in right lower bronchus using the rigid bronchoscope in a tracheostomized patient with limited neck extension due to cervical vertebra fracture.

The rigid bronchoscope was inserted through the tracheostomy stoma and the foreign body was successfully removed using rigid optical forcep⁷. Noh KB et al reported an extraction technique of a metallic hair pin from the left tertiary bronchus using angiocatheter and flexible optical forceps guided by flexible bronchoscopy⁸.

In our case, we used a flexible endoscope due to the location of the foreign body in the distal and smaller airway which required a smaller and longer endoscope insertion shaft. The inverted location of the upper lobe secondary bronchus needs slight retrograde flexion of a flexible scope. It also was chosen as it was able to fit into the opening of the catheter mount without significant gas leakage. Due to the unavailability of flexible bronchoscopy with a built-in working channel, the 2.5mm neonate flexible nasopharyngolaryngoscope was used as it still able to serve an almost similar function as flexible bronchoscopy. However, we had to insert the flexible grasping forcep separately from the endoscope due to the limitation of space via the catheter mount.

We selected smaller ETT size (3.5 mm) in second intubation after considering the narrowed airway caused by the laryngospasm and to provide some space to place the instruments sideway to the ETT. Smaller size ETT has the advantage of allowing clear visualization of both vocal cords and enable the passage of flexible forcep outside the ETT without injuring the vocal cords and trachea.

By maintaining the suspension laryngoscopy throughout the procedure, we were able to interchange the ventilation method between apnoeic ETT sheath and CMV techniques. We were also able to conduct the necessary procedures without compromising the airway.

Figures 5 and 6 illustrate the arrangement of the instruments that were used.

Maintaining oxygenation is the major challenge as hypoxia is a common complication during bronchoscopy. Rigid bronchoscopy has the advantage of simultaneous ventilation during the procedure. However, instrumentation during the procedure may lead to suboptimal oxygenation⁹. Endotracheal intubation is recommended if profound hypoxia occurs during a complicated bronchoscopy⁹. In our case, the decision to intubate the patient was made due to several factors such as airway protection in laryngospasm and for optimum oxygenation in a readily compromised pulmonary function due to ongoing lungs infection.

We report this novel technique of foreign body removal located at the distal airway in a paediatric patient and in a situation where a paediatric flexible bronchoscopy with built-in working channel is not available. This technique was proven to be successful in retrieving the foreign body with no intraoperative or postoperative complication.

Conclusion:

Any child with a suspicious history of foreign body aspiration with corresponding clinical conditions is justified for a bronchoscopy procedure. Profound understanding of paediatric respiratory physiology, judicious anticipation of anaesthetic or surgical effects on paediatric airway with sound anatomical knowledge and competent surgical skills are crucial in conducting a safe and successful paediatric bronchoscopy. Dynamic airway changes during this procedure require a re-evaluation of the surgical plan or modification of surgical techniques.

References:

1. Monika Mahajan, Som, Raj Mahajan, Preethy J. Mathew, Usha K Chaudhary, Rajesh Chaudhary. Anaesthetic management during removal of airway foreign body in children: A prospective observational study. *IOSR Journal of Dental and Medical Sciences (IOSR-JDMS)*. 2017; 16:87-95. URL: <http://www.iosrjournals.org/iosr-jdms/papers/Vol16-issue6/Version-9/T1606098795.pdf> DOI: 10.9790/0853-1606098795
2. Saikia D, Mahanta B. Cardiovascular and respiratory physiology in children. *Indian Journal of Anaesthesia*. 2019; 63:690-697. DOI : 10.4103/ija.IJA_490_19
3. D. Trachsel, J. Svendsen, T. O. Erb, B. S. von Ungern-Sternberg. Effects of anaesthesia on paediatric lung function. *BJA: British Journal of Anaesthesia*. 2016;117: 151–163. DOI: 10.1093/bja/aew173
4. Shostak, E. Foreign body removal in children and adults: Review of available techniques and emerging technologies. *AME Medical Journal* 3. 2018; 75. DOI : 10.21037/amj.2018.07.02
5. Boufersaoui A, Smati L, Benhalla KN, R. Boukari, S. Smail, K. Anik, R. Aouameur, H. Chaouche, M. Baghriche. Foreign body aspiration in children: Experience from 2624 patients. *International Journal of Paediatric Otorhinolaryngology*. 2013; 77:1683-1688. DOI: 10.1016/j.ijporl.2013.07.026
6. Tang, L.F., Lan-Fang Tang, Ying-Chun Xu, Ying-Shuo Wang, Cai-Fu Wang, Guo-Hong Zhu, Xing-Er Bao, Mei-Ping Lu, Lian-Xiang Chen & Zhi-Min Chen. Airway foreign body removal by flexible bronchoscope experience with 1,027

- children during 2000–2008. *World Journal of Pediatric*. 2009; 5:191–195. DOI: 10.1007/s12519-009-0036-z
7. Mohd Nazir Othman, Sivakumar Kumarasamy, Valuyeetham Kamaru Ambu, Goh Bee See. Foreign body in bronchus: A rare method of removal. *Rawal Medical Journal*. 2013; 38:204-205. URL : <http://www.rmj.org.pk/fulltext/27-1354726528.pdf>
 8. Noh KB, Salim R, Abdullah MS, Mohamad I. Metallic hair pin aspiration into the left tertiary bronchus. *Malaysian Family Physician*. 2018; 13:36-38. URL:https://www.researchgate.net/publication/328075390_Metallic_hair_pin_aspiration_into_the_left_tertiary_bronchus
 9. Roberts, S., &Thornington, R. E. Paediatric bronchoscopy. *Continuing Education in Anaesthesia Critical Care & Pain*.2005; 5: 41–44. DOI : <https://doi.org/10.1093/bjaceaccp/mki015>