

Original Article

Outcome of Limited Attic Cholesteatoma Surgery: Endoscopic vs Microscopic

Md. Sha Sakender¹, Md. Monjurul Alam², Md. Lutfur Rahaman³, Sabyasachi Talukdar⁴, Murshedur Rahaman⁵, Mohammad Nazrul Islam⁶

Abstract:

Background: Endoscope and microscope are exclusively used in different middle ear pathologies as well as patients with attic cholesteatoma. However, straightforward information regarding surgical advances, postoperative results, and information about in which patients and how this surgical technique should be exclusively used is debatable.

Aim: To compare the outcome of primary exclusive endoscopic ear surgery with those of the microscopic ear surgery in two groups of patients with cholesteatoma limited to the attic region.

Methods: This prospective observational study was conducted in the Department of Otolaryngology-Head and Neck Surgery, BSMMU, Dhaka, from July 2018 to December 2019, with 26 patients having cholesteatoma limited to the attic region. Patients were divided into two groups. One group of patients were submitted to atticotomy with tympanoplasty via microscopic ear surgery (MES) and a second group to exclusive trans-canal endoscopic ear surgery (EES). All the patients were followed up post-operatively up to 3 months with PTA.

Results: Mean bone conduction threshold, air conduction threshold, and ABG has been reduced considerably in both groups (endoscopic and microscopic) at the end of three months postoperatively. There was no significant statistical difference between the two groups in terms of graft uptake success rate and the audiological success rate (p -value >0.05). Postoperatively, pain requiring analgesics was significantly lower ($p < 0.033$) in the endoscopic group (23.1%) than in the microscopic group (69.2%).

Conclusion: Audiological outcome and graft uptake success rates achieved by the endoscopic ear surgery were similar to the results obtained by the microscopic ear surgery in limited attic cholesteatoma.

Keywords: Limited attic cholesteatoma, Endoscopic ear surgery, Microscopic ear surgery, Atticotomy, Ossiculoplasty;

-
1. Registrar, Dept. of ENT & HNS, Shaheed Suhrawardy Medical College Hospital, Dhaka
 2. Professor, Dept. of Otolaryngology-Head & Neck Surgery, Bangabandhu Sheikh Mujib Medical University, Shahbag, Dhaka
 3. Registrar, Dept. of ENT & HNS, Shaheed Suhrawardy Medical College Hospital, Dhaka
 4. Assistant Registrar, Dept. of ENT & Head-Neck Surgery, Shaheed Suhrawardy Medical College Hospital, Dhaka
 5. Registrar, Dept. of ENT & HNS, Shaheed Suhrawardy Medical College Hospital, Dhaka
 6. Junior Consultant (ENT), 250 Bedded General Hospital, Tangail.

Address of Correspondence: Dr. Md. Sha Sakender, Registrar, Dept. of ENT & Head-Neck Surgery, Shaheed Suhrawardy Medical College Hospital, Dhaka. Cell: 01717144401, e-mail: drtuhin35@gmail.com

Introduction:

Cholesteatoma can be defined as a mass lesion found within middle ear cleft formed by an abnormal collection of the keratinizing squamous epithelium; keratin debris rests on a stroma, the perimatrix with varying degree of thickness¹. Which was earlier termed as skin in the wrong place².

Cholesteatoma can be classified as two distinct types; congenital and acquired. A congenital cholesteatoma usually forms earlier to birth behind an intact tympanic membrane without any history of previous otitis media or any otologic disease process. An acquired cholesteatoma usually formed as a consequence of retraction in the tympanic membrane due to eustachian tube dysfunction or chronic middle ear disease³. Though cholesteatoma is a benign lesion, it has the capability of expansion and bone destruction within the temporal bone⁴.

Tos and Lau introduced a topological classification of cholesteatoma based on site of origin, which considers it an essential factor for the surgical procedure and the prognosis. This taxonomy presents three categories as attic cholesteatoma, sinus cholesteatoma and tensa cholesteatoma^{2,3,5}.

Cholesteatoma limited to the attic region tends to grow medially with varying degrees of bone destruction⁶. In 2016, the European Academy of Otolaryngology and Neurotology and the Japan Otological Society in a joint consensus on the definition, classification and staging of cholesteatoma, classified pars flaccida cholesteatoma (attic cholesteatoma) as stage I: Cholesteatoma localized in the attic; stage II: Cholesteatoma involving two or more sites; stage III: Cholesteatoma with extracranial complications and stage IV: Cholesteatoma with intracranial complications⁷.

Due to the multifactorial and advancing nature of the disease process, an extremely varying

pathophysiological condition found from case to case. Therefore, the surgeon needs to make an individual customized decision for every case regarding the most appropriate surgical approach to achieve the best surgical outcomes, including postoperative hearing gain, eradication of disease and disease-free survival⁸.

The microscope has been the conventional instrument exercised in otologic surgery, especially for cholesteatoma. Despite the illumination and magnification offered by the operating microscope, it has got some distinct constraints such as limited exposure of hidden areas like epitympanic space, sinus tympani through the narrowest segment of the ear canal while using the ear canal as the primary conduit to the operative field. In contrast, transcanal endoscopic ear surgery bypasses the narrowest portion of the ear canal, provides a comprehensive view to see around every corner of the tympanic cavity including attic after scooping of the scutum^{9,10}.

Endoscopic ear surgery has many advantages over traditional microscopic ear surgery such as better visualization, wider and clear view of the operative field, angled view for visualization of the hidden area of middle ear cleft and less trauma to healthy structures. However, endoscope doesn't allow proper manipulation of instruments because of single-handed surgery along with thermal damage to surrounding healthy structure and involuntary movement. Although advanced endoscopic system allowed two-handed surgery^{6,10}.

Nowadays, in the field of otology and neurotology, endoscopic surgery has actively been performed due to the rapid development of endoscopic surgical tools with high enthusiasm in minimally invasive surgery^{10,11}. The use of a surgical endoscope makes it more accessible to expose the hidden lesions

in the middle ear and provides a better close-up view of the surgical field in comparison with an operative microscope^{11,12}. Therefore, a complete disease clearance from attic, and preserving the healthy anatomical structures such as ossicles, middle ear mucosal folds, as well as ventilation mechanism is possible using the endoscope. Hence, the most fundamental approach to limited attic cholesteatoma is the transcanal endoscopic ear surgery¹¹.

The evolution of endoscopic ear surgery techniques encourages surgeons to change the ear surgery method. Now endoscope is more often used in middle ear surgery such as chronic otitis media (mucosal disease), malformations of the auditory ossicles, traumatic damage to the ossicles, chronic otitis media with cholesteatoma, otosclerosis, and other diseases. Despite some constraints, the use of the endoscope in middle ear surgery is increasing day by day across the world^{11,13}.

Endoscopic ear surgery started in 2005 at the Department of Otolaryngology-Head and Neck Surgery of BSMMU¹⁴. Nowadays primary exclusive endoscopic ear surgeries are being performed for various ear pathologies in the department of Otolaryngology-Head and Neck surgery of Bangabandhu Sheikh Mujib Medical University. But less published data are available in our country. Therefore, based on this background, the present study has been designed to compare the outcomes of primary exclusive endoscopic ear surgery with those of the microscopic ear surgery in a group of patients having limited attic cholesteatoma.

Materials and Methods:

This Prospective Observational Study was carried out at the Department of Otolaryngology-Head & Neck Surgery of BSMMU, Shahbag, Dhaka, from July 2018

to December 2019, with 26 patients having cholesteatoma limited to attic region. Following the inclusion and exclusion criteria, the patients were included in this study. After the selection of the patient, the nature, purpose and benefit of the study were explained to each subject in detail. They were encouraged for voluntary participation. They were allowed to withdraw from the study whenever they feel like it. Informed written consent was taken from the patients. Ethical clearance was obtained from the Institutional Review Board (IRB) of BSMMU. All patients were assessed pre-operatively by detailed history and clinical examination, preoperative otomicroscopic and otoendoscopic evaluation, and a HRCT scan of the temporal bone. The hearing assessment was initially performed clinically by tuning fork tests and then by Pure tone audiometry. Patients were treated by two distinct surgical procedures. One group of patients were submitted to atticotomy with tympanoplasty by microscopic ear surgery (MES) and a second group to exclusive trans-canal endoscopic ear surgery (EES). Karl Storz 4 millimeter 0°, 30° and 70° Hopkins rod telescope (rigid endoscope) and Leica and Zeiss operating microscope were used.

The steps of EES:

Posterosuperior tympanomeatal flap was elevated. Entrance into the middle ear with preservation of the chorda tympani nerve. Scooping off the posterosuperior meatal wall for visualization of the ossicles, the oval and round windows, the tympanic segment of the Fallopian canal, the cochleariform process and horizontal semicircular canal. Confirmation of diagnosis and status of ossicular chain was assessed. Eroded ossicles were removed. The cholesteatoma matrix was completely removed. Temporalis fascia graft and tragal cartilage graft was harvested. Ossiculoplasty done by autologous

cartilage (If needed). Tragal cartilage were used for reconstruction of the attic wall. Temporalis fascia graft placed by underlay technique. The tympanomeatal flap was repositioned. The external auditory canal was packed with Gelfoam.

The steps of atticotomy with tympanoplasty in microscopic ear surgery (MES):

A postauricular incision was given in all cases. Temporalis fascia graft and conchal cartilage graft was harvested. Tympanomeatal flap was elevated. Entrance into the middle ear with preservation of the chorda tympani nerve. Drilling off the posterosuperior meatal wall for visualization of the ossicles, the oval and round windows, the tympanic segment of the Fallopian canal, the cochleariform process and horizontal semicircular canal. Confirmation of diagnosis and status of ossicular chain was assessed. Eroded ossicles were removed. The cholesteatoma matrix was completely removed. Ossiculoplasty done by autologous cartilage (If needed). Conchal cartilage used for reconstruction of the attic wall. Temporalis fascia graft placed by underlay technique. The tympanomeatal flap was repositioned. The external auditory canal was packed with Gelfoam. Postauricular wound was closed in layers.

Surgery was done by regular ear surgeon with a minimum of ten years of experience or associate professor and above faculty of the Department of Otolaryngology-Head and Neck Surgery of BSMMU. Among these 26 patients, 13 patients were operated by endoscopic surgeons categorized as EES group and the other 13 patients were treated by regular faculty members of this department by microscope and classified as MES group. The clinical records of patients were analyzed to collect data about preoperative and postoperative clinical manifestations

(otorrhoea, facial palsy, vertigo/dizziness, hypo/anacusis and taste abnormality). The hearing was assessed preoperatively and at three months after surgery by PTA in both groups. All patients of the study were asked to evaluate the severity of postoperative pain at 1st postoperative day. The pain was classified using three grades: almost no pain, mild pain requiring no analgesics drugs, and pain requiring analgesics drugs¹⁰. All the patients were given paracetamol 500mg orally three times a day postoperatively for a week. In case of pain requiring analgesics, drugs were prescribed by us and in each case, the same non-steroidal anti-inflammatory drug. Each patient was asked not spontaneously to take analgesics without asking us. Taste abnormalities were investigated as presence or absence of a subjective abnormal taste sensation. Otomicroscopic and otoendoscopic follow-up was performed approximately after three months. An intact graft at the end of the three months postoperatively was considered as graft uptake success and minimum hearing improvement of 10 dB in three consecutive speech frequencies was regarded as an audiological success after surgery at three months. All the information was recorded in a prefixed questionnaire (Appendix III).

The data were calculated in an excel spreadsheet, which was then exported to the Statistical Package for Social Sciences (SPSS 26.0) for statistical analysis. The statistical significance was set to $p < 0.05$. Demographic characteristics and study variables were analyzed using descriptive statistics. The results of the study were expressed as mean, standard deviation (\pm SD), frequency and percentages. Results were tabulated and statistically analyzed using Chi-square, Unpaired, and Paired student t-test.

Results:

Total 26 patients (13 in each group) were operated during our study period. Postoperatively maximum duration of follow up was 3 months. There were two patients who missed the follow-up, and the Hot-deck imputation technique was applied for missed follow up.

In this study age of the patients ranged from 18-60 years with a mean age \pm standard deviation (SD) of 33.6 ± 12.2 years in endoscopic group and 31.0 ± 14.5 years in microscopic group. No significant difference of age distribution between two groups ($p > 0.05$). Majority of the patients were male 8 (61.5%) in endoscopic group whereas female 7 (53.8%) in microscopic group. Right ear was operated more in both groups. Retraction pocket in attic region found more in both groups than attic perforation.

Ossicular chain was found intact in 11 cases and eroded in 15 cases (7 in the endoscopic and 8 in the microscopic group). The Incus was eroded in 9 cases. The Incus and Malleus head was eroded in 6 cases. The Malleus head only was eroded in 4 cases. Stapes was intact in all cases. Primary ossiculoplasty (53.8% in the endoscopic group and 61.5% in the microscopic group) was done using autologous cartilage in all cases of Incus only erosion and

Incus plus Malleus head erosion. Only malleus head erosion did not need ossiculoplasty.

In the endoscopic group, mean \pm SD pre and postoperative air conduction were 40.92 ± 6.79 dB and 31.02 ± 6.15 dB. Mean \pm SD pre and postoperative bone conduction were 14.33 ± 1.84 dB and 13.84 ± 1.82 dB. Mean \pm SD ABG in pre and postoperative was 27.21 ± 4.63 dB and 17.18 ± 5.39 dB respectively. In the microscopic group, mean \pm SD pre and postoperative air conduction were 41.41 ± 6.95 dB and 29.86 ± 8.65 dB. Mean \pm SD pre and postoperative bone conduction were 15.62 ± 2.30 dB and 14.23 ± 2.40 dB. Mean \pm SD ABG in pre and postoperative was 25.78 ± 5.97 dB and 15.65 ± 7.37 dB respectively. Mean \pm SD air conduction, bone conduction, and ABG were significantly decreased at postoperative from preoperative in each group. The postoperative ABG closure was 10.08 ± 1.43 dB in the endoscopic group and 10.08 ± 1.69 dB in the microscopic group. In the endoscopic group, audiological success achieved in 9 (69.2%) cases and in the microscopic group 8 (61.5%) cases. Postoperative graft uptake success rate at three months were 84.6% and 76.9% in the endoscopic and microscopic groups, respectively. There was no statistically significant difference in audiological outcome comparison between both groups (p -value > 0.05).

Table I :

Comparison of pre and postoperative audiological findings between the two groups (n=26)

Variables		Group		p-value
		Endoscopic (n=13) (dB) Mean \pm SD	Microscopic (n=13) (dB) Mean \pm SD	
Preoperative	Bone conduction (dB)	14.33 ± 1.84	15.62 ± 2.30	0.129 ^{ns}
	Air conduction (dB)	40.92 ± 6.79	41.41 ± 6.95	0.859 ^{ns}
	ABG (dB)	27.21 ± 4.63	25.78 ± 5.97	0.501 ^{ns}
Postoperative	Bone conduction (dB)	13.84 ± 1.82	14.23 ± 2.40	0.643 ^{ns}
	Air conduction (dB)	31.02 ± 6.15	29.86 ± 8.65	0.697 ^{ns}
	ABG (dB)	17.18 ± 5.39	15.65 ± 7.37	0.551 ^{ns}

Table II :
Comparison of postoperative ABG closure between the two groups (n=26)

Variables	Group		p-value
	Endoscopic (n=13) Mean±SD	Microscopic (n=13) Mean±SD	
ABG closure (dB)	10.08±1.43	10.08±1.69	0.921 ^{ns}

During this study period transient taste abnormality found 2 cases in the endoscopic group and 1 case in the microscopic group, which was successfully recovered within our follow-up period. Postoperative dizziness reported 2 cases in the endoscopic group and 3 cases in the microscopic group, relieved by conservative measures within three to five days postoperatively. There was no postoperative iatrogenic facial palsy, anacsis and wound infection in any group.

Almost no pain observed in 3(23.1%) of the endoscopic group and 0(0%) in the microscopic group. Mild pain (requiring no analgesic) was found 7(53.8%) in the endoscopic group and 4(30.8%) in the microscopic group. Pain requiring analgesics was 3(23.1%) in the endoscopic group and 9(69.2%) in the microscopic group. Pain (requiring analgesics) was significantly lower in the endoscopic group compare to the microscopic group (p<0.033).

Table III :
Comparison of postoperative complications between the two study groups (n=26)

Complications	Group	
	Endoscope (n=13) No. (%)	Microscope (n=13) No. (%)
Iatrogenic facial palsy	0	0
Transient taste abnormality	2 (15.4%)	1 (7.7%)
Postoperative dizziness	2 (15.4%)	3 (23.1%)
Anacsis	0	0
Wound infection	0	0

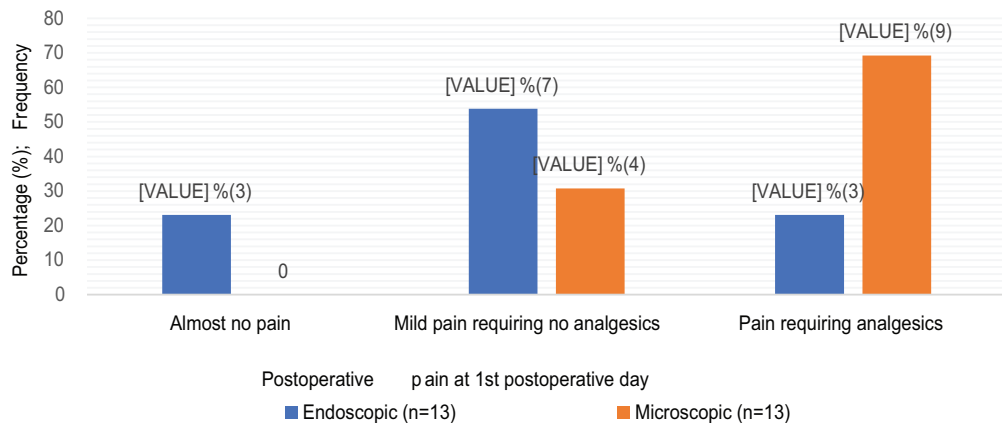


Fig.-1: Bar diagram showing comparison of postoperative pain at 1st POD between the two groups (n=26)

Discussion:

This is a Prospective Observational Study in which patients were treated by two distinct surgical procedures, namely microscopic ear surgery (MES) and exclusive trans-canal endoscopic ear surgery (EES). A comparison of the outcomes of the two techniques has endeavored in our study.

In our study, we included 26 patients between the ages of 18 to 60 years with a mean age \pm standard deviation (SD) of 33.6 ± 12.2 years in the endoscopic group and 31.0 ± 14.5 years in the microscopic group. In the microscopic group, 46.2% of patients were male, and 53.8% were female. In a related study, Magliulo and Iannella (2018) reported similar demographic findings¹⁰. No difference in the parameters analyzed (patient's age, sex, disease duration, intraoperative cholesteatoma features) was observed between the endoscopic and microscopic groups, indicating a uniform adoption of patients that presented a good comparison of the results among the two groups.

In the present study, findings of pars flaccida were retraction pocket in 53.8% and perforation in 46.2% of the endoscopic group and in the microscopic group retraction pocket in 61.5% and perforation in 38.5%. Frequency of retraction or perforation in two groups were not statistically significant.

In this study, the ossicular chain was found intact in 11 cases and eroded in 15 cases. The Incus was eroded in 9 cases. The Incus and Malleus head was eroded in 6 cases. Stapes was intact in all cases. Primary ossiculoplasty was done using autologous cartilage in all cases of Incus only erosion and Incus plus Malleus head erosion. Ossiculoplasty distribution was statistically insignificant between the two groups (p -value > 0.05). In consistent with this study, Bae et al. (2019) stated similar findings regarding

ossicular erosion and requirements of ossiculoplasty which was statistically insignificant⁶. In a similar study, Tarabichistated that the incus or its remnant was removed in 49 ears and the head of malleus was removed in 43 ears for ossicular erosion and did primary ossiculoplasty¹⁵.

In this study, there was no postoperative iatrogenic facial palsy, anacusis and wound infection in any group. Transient taste abnormality found 2 (15.4%) cases in the endoscopic group and 1 (7.7%) case in the microscopic group, which was successfully recovered within our follow up period. Postoperative dizziness reported 2 (15.4%) cases in the endoscopic group and 3 (23.1%) cases in the microscopic group, relieved by conservative measures within three to five days postoperatively. Our results were consistent with the findings of a similar study conducted by Magliulo and Iannella¹⁰.

In the present study, mild postoperative pain (requiring no analgesic) observed 53.8% of patients in the endoscopic group and 30.8% in the microscopic group. Pain requiring analgesics found 23.1% of patients in the endoscopic group and 69.2% in the microscopic group. Pain (requiring analgesics) was lesser in the endoscopic group compared to microscopic, which was statistically significant ($p < 0.033$). In a consistency with the present study Das et al. and Magliulo and Iannella reported similar result of postoperative pain^{10,16}.

In the endoscopic group, pre and postoperative mean bone conduction were 14.33 ± 1.84 dB and 13.84 ± 1.82 dB, pre and postoperative mean air conduction were 40.92 ± 6.79 dB and 31.02 ± 6.15 dB, pre and postoperative mean ABG were 27.21 ± 4.63 dB and 17.18 ± 5.39 dB. In the microscopic group, pre and postoperative mean bone conduction were 14.23 ± 2.40 dB, pre and postoperative

mean air conduction were 41.41 ± 6.95 dB and 29.86 ± 8.65 dB, pre and postoperative mean ABG were 25.78 ± 5.97 dB and 15.65 ± 7.37 dB. A comparison of audiological changes at preoperative from postoperative between the endoscopic and microscopic groups was statistically insignificant. In a similar study Bae et al. compare pre and postoperative BC, AC, ABG and ABG closure between the endoscopic and the microscopic group and found no significant statistical difference between the study groups⁶. In another study, Das et al. used to analyze pre and postoperative ABG closure between the endoscopic and the microscopic group, findings were statistically insignificant¹⁶. Magliulo and Iannella reported similar result in another comparative study¹⁰.

In the present study, postoperative follow up at three months found similar outcomes from both the endoscopic and the microscopic attic cholesteatoma surgery, in terms of graft uptake rates of 84.6% and 76.9% respectively ($p = 0.619$). Bae et al. stated no recurrent or residual disease after 19.75 and 41.05 months of mean follow up in the endoscopic and microscopic group, respectively⁶. Magliulo and Iannella reported 100% of patients had a graft success rate and healthy otomicroscopic appearance in both the endoscopic and microscopic groups after a mean follow up of 12.3 months¹⁰.

Tympanic graft success rates and hearing outcomes from EES and MES are quite similar, as stated in the systemic review by Tseng et al¹⁷. Our study confirms these results, as the endoscopic and microscopic groups did not differ in terms of postoperative hearing outcome and graft success rates. However, the analysis of postoperative pain showed less pain in the endoscopic group.

Conclusion:

Audiological outcome and graft uptake success rates achieved by the endoscopic

ear surgery were similar to the results obtained by the microscopic ear surgery in limited attic cholesteatoma. Therefore, the endoscopic approach for management of limited attic cholesteatoma is as useful as the microscopic approach.

References:

1. Semaan MT, Megerian CA. The pathophysiology of cholesteatoma. *Otolaryngologic Clinics of North America*. 2006 Dec 1;39(6):1143-59.
2. Kuo CL, Shiao AS, Yung M, Sakagami M, Sudhoff H, Wang CH, Hsu CH, Lien CF. Updates and knowledge gaps in cholesteatoma research. *BioMed research international*. 2015 Mar 18;2015.
3. Dornelles C, da Costa SS, Meurer L, Schweiger C. Some considerations about acquired adult and pediatric cholesteatomas. *Brazilian journal of otorhinolaryngology*. 2005 Jul 1;71 (4): 536-45.
4. Isaacson G. Diagnosis of pediatric cholesteatoma. *Pediatrics*. 2007 Sep 1;120(3):603-8.
5. Olszewska, E., Wagner, M., Bernal-Sprekelsen, M., Ebmeyer, J., Dazert, S., Hildmann, H. and Sudhoff, H. Etiopathogenesis of cholesteatoma. *European Archives of Oto-Rhino-Laryngology and Head & Neck*. 2004 Feb 1;261(1):6-24.
6. Bae MR, Kang WS, Chung JW. Comparison of the clinical results of attic cholesteatoma treatment: endoscopic versus microscopic ear surgery. *Clinical and experimental otorhinolaryngology*. 2019 May; 12(2):156.
7. Yung M, Tono T, Olszewska E, Yamamoto Y, Sudhoff H, Sakagami M, Mulder J, Kojima H, Yncesulu A,

- Trabalzini F, Özgirgin N. EAONO/JOS joint consensus statements on the definitions, classification and staging of middle ear cholesteatoma. *J Int Adv Otol.* 2017 Apr 1;13(1):1-8.
8. Tono T, Sakagami M, Kojima H, Yamamoto Y, Matsuda K, Komori M, Hato N, Morita Y, Hashimoto S. Staging and classification criteria for middle ear cholesteatoma proposed by the Japan Otological Society. *Auris Nasus Larynx.* 2017 Apr 1;44(2):135-40.
 9. Marchioni D, Villari D, Mattioli F, Alicandri-Ciufelli M, Piccinini A, Presutti L. Endoscopic management of attic cholesteatoma: a single-institution experience. *Otolaryngologic Clinics of North America.* 2013 Apr 1;46(2):201-9.
 10. Magliulo G, Iannella G. Endoscopic versus microscopic approach in attic cholesteatoma surgery. *American journal of otolaryngology.* 2018 Jan 1;39(1):25-30.
 11. Tarabichi M. Transcanal endoscopic management of cholesteatoma. *Otology & Neurotology.* 2010 Jun 1;31(4):580-8.
 12. Alicandri-Ciufelli M, Marchioni D, Kakehata S, Presutti L, Villari D. Endoscopic management of attic cholesteatoma: long-term results. *Otolaryngologic Clinics of North America.* 2016 Oct 1;49(5):1265-70.
 13. Pollak N. Endoscopic and minimally-invasive ear surgery: a path to better outcomes. *World journal of otorhinolaryngology-head and neck surgery.* 2017 Sep 1;3(3):129-35.
 14. Alam, M.M. The Evolution of Endoscopic Ear Surgery. *Bangladesh J Otorhinolaryngol.* Oct 2016;22(2):58-59.
 15. Tarabichi, M., 2004. Endoscopic management of limited attic cholesteatoma. *The laryngoscope,* 114(7), pp.1157-1162.
 16. Das, A., Mitra, S., Ghosh, D. and Sengupta, A., 2020. Endoscopic versus microscopic management of attic cholesteatoma: a randomized controlled trial. *The Laryngoscope,* 130(10), pp.2461-2466.
 17. Tseng, C.C., Lai, M.T., Wu, C.C., Yuan, S.P. and Ding, Y.F., 2017. Comparison of the efficacy of endoscopic tympanoplasty and microscopic tympanoplasty: A systematic review and meta analysis. *The Laryngoscope,* 127(8), pp.1890-6.