

Case Report

Impacted porcelain foreign body in the nasopharynx: a clinical enigma

Mainak Dutta¹, Soumya Ghatak², Indranil Sen³, Jayanta Saha², Gautam Biswas⁴, Ramanuj Sinha⁵, Bibhas Adhikary⁴

Abstract:

Nasopharynx is an exceptionally rare anatomical location for foreign body impaction. We present a unique case of foreign body made of porcelain lodged in the nasopharynx of a one and a half year old child for more than a month. The foreign body had been introduced perorally and had subsequently got impacted in the nasopharynx following amateur digital manipulation. Presence of porcelain foreign body in the nasopharynx has never been reported before. Removal of the foreign body was performed under general anesthesia. This rare situation is potentially dangerous, since its dislodgment may cause fatal airway obstruction. Therefore, in all cases with missing foreign bodies in the aerodigestive system, nasopharyngeal impaction should be kept in mind and examination of the region should be considered.

Key Words: Impacted foreign body; nasopharynx; porcelain

1. Junior Resident in MS course, Otorhinolaryngology-Head & Neck Surgery, R. G. Kar Medical College and Hospital, 1, Khudiram Bose Sarani, Kolkata-700004, West Bengal, India
2. RMO-cum-Clinical Tutor, Otorhinolaryngology - Head & Neck Surgery, R. G. Kar Medical College and Hospital, 1, Khudiram Bose Sarani, Kolkata-700004, West Bengal, India
3. Associate Professor, Otorhinolaryngology – Head & Neck Surgery, R. G. Kar Medical College and Hospital, 1, Khudiram Bose Sarani, Kolkata-700004, West Bengal, India
4. Assistant Professor, Otorhinolaryngology – Head & Neck Surgery, R. G. Kar Medical College and Hospital, 1, Khudiram Bose Sarani, Kolkata-700004, West Bengal, India
5. Professor, Otorhinolaryngology – Head & Neck Surgery, R. G. Kar Medical College and Hospital, 1, Khudiram Bose Sarani, Kolkata – 700004, West Bengal, India

Address for Correspondence: Dr. Mainak Dutta, C/o Dr. Soumya Ghatak, B-24/3, Kalindi Housing Estate, Kolkata – 700089, West Bengal, India, Phone: +91-9830737587, Email: duttamainak@yahoo.com

Introduction:

A foreign body in the nasopharynx is a rare entity and has been seldom reported in world literature. They remain mostly asymptomatic, but may have variable presentations, enough to mislead an otorhinolaryngologist for an apparently innocuous local pathology, thereby further delaying the diagnosis. The management of these cases varies greatly according to the object's composition, location, and depth of penetration. Embedded foreign bodies that are made of inert material such as porcelain can remain asymptomatic for a long period of time. Their removal can be challenging, especially when they are embedded in soft tissues.

Case report:

A one and a half year old male child came to the Otorhinolaryngology clinic of a tertiary referral hospital complaining of bilateral serosanguinous, foul smelling nasal discharge mixed with blood for the last 4-5 days. There was neither any history of trauma, nor any history suggestive of previous episode

of rhinosinusitis suffered by the child. On examination, apart from the nasal discharge, he had no fever, or any localized signs of inflammation. The child was calm, and there was no respiratory distress. His mouth was opened but nothing abnormal came into view. However, the soft palate was mildly edematous, appeared blanched and indented, but without any mucosal injury.

To get a clue to the etiology of the nasal discharge, radiological investigation in the form of digital X-ray nasopharynx lateral view [Figure 1] was done which revealed a triangular radio-opaque shadow behind the choana.

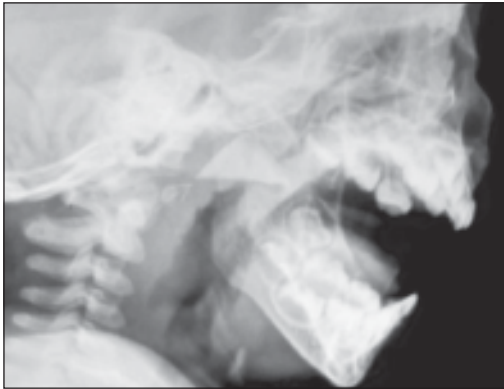


Figure 1: *The X-ray of soft tissue pharynx and neck lateral view of the child showing the triangular radio-opaque foreign body lodged in the nasopharynx.*

On detailed history taking, the parents remembered him inserting of a piece of porcelain container into his mouth one and a half month back, which accidentally broke while playing with it. Attempts by them to take it out were not fruitful. As the child did not develop any symptoms, they felt assured and became oblivious of the incident. It was only after the child developed the blood-stained nasal discharge that they brought him for medical help.

After the preoperative investigations, the child was put for surgical removal of the foreign body from his nasopharynx under general anesthesia. A hypopharyngeal pack was given

to prevent aspiration. A pediatric nasendoscope was used for direct visual inspection of the nasopharynx. A triangular piece of porcelain was seen lodged in the postnasal space with its two edges almost impinging on the two tubal openings. It was covered by granulation tissue and there was significant bleeding on attempts at removal. However the space was too narrow for the purpose of removal of the foreign body itself via the nasal route. With digital examination, the foreign body was felt grossly impacted in the edematous nasopharyngeal mucosa, including the adenoids. Two narrow and soft rubber catheters were passed through the nasal cavity and taken out from the mouth with a gentle upward traction, thereby lifting the soft palate. The foreign body was finally dislodged with digital manipulations but only after several attempts, as granulation tissue covered the material entirely and manipulations in a very small space, further reduced by edema, resulted in bleeding. Suction of the oral cavity and oropharynx was done whenever required. After dislodging, it was taken out with Negus' forceps through the mouth. The porcelain piece measured approximately 2.1 cm x 2 cm x 1.8 cm [Figure 2]. Hemostasis was ensured.



Figure 2: *The triangular shaped porcelain piece after removal.*

As anticipated, postoperative facial edema ensued; this was managed with recurrent applications of cold compress. Otherwise, the postoperative period was uneventful.

Discussion:

Foreign bodies in the aerodigestive tract are common presentations in the Otorhinolaryngology emergency and outpatients' departments, and require prompt removal following diagnosis. Estimates show that about 1,500 deaths occur in the United States annually due to foreign body impaction in the upper aerodigestive tract, most of them being children.¹ In fact, the most common age group is under 15 years.² with the peak at 2-4 years, and 73% of them being below.³ This can be attributed to several causes – the in-coordination in the process of swallowing and immature laryngeal elevation and glottic closure; absence of molars resulting in improper grinding of food; fidgeting around during playing; the natural inquisitiveness of a child about its surroundings and the natural orifices of the body, are only to mention a few.^{2, 4} Thus, bronchus becomes the most common site of airway foreign body impaction, while larynx, trachea, pyriform fossa, nasal cavities are also involved in varying proportions. However, a foreign body in the nasopharynx is an exceptionally rare entity.^{5, 6} While introduction of foreign body in the nasal cavity by children is very common, the same in the nasopharynx is quite unusual as majority of the inhaled foreign bodies pass either in the esophagus, or through the glottis into the trachea. And introduction through the mouth by the child himself and subsequent lodgment and impaction for months, as has been in our case, is furthermore rare.⁷ The probable cause of the ingested foreign body getting lodged in the nasopharynx in our case could be the emergency maneuver used by the attendants at home. Most of the foreign bodies

in the nasopharynx are the results of surgical negligence, like retained swabs following adenoidectomy.⁸ Though few queer unwanted objects have been retrieved from the nasopharynx, like metals (coin, thimble, ring), live fish, leech, whistle, wood piece, marble etc., such reported cases are far and few in world literature. According to our knowledge, presence of a porcelain foreign body in the nasopharynx has never been reported before.

How a foreign body enters into the nasopharynx is really a mystery and is subject to a good amount of imagination and conjecture, as the normal anatomy of the nasopharynx and the nasopharyngeal sphincter prevent such entry. Some documentation propose recurrent cough and hiccups that push an aspirated foreign body cranially towards the nasopharynx.⁹ Trauma, including road traffic accidents, is also responsible occasionally. In others, amateurish attempts to get hold of the foreign body and in turn causing further impaction, as happened in our case, are also implicated.

What also makes this case unique is that, instead of fish or chicken bones that are most commonly found to lodge in the upper aerodigestive tract,¹⁰ we had a porcelain piece impacted deep into the nasopharynx for more than a month, without causing any complication for most of the period. Though a long-term stay in the nasopharynx has been reported previously, because a lost foreign body is seldom suspected to be harbored in such a space, it is expected to produce complications like bleeding, respiratory difficulty, halitosis, localized infections mimicking chronic sinusitis, acute otitis media and nasopharyngeal stenosis.^{9, 11 - 14} It may even be fatal if it dislodges.^{5, 9}

Hence a low threshold of suspicion should be maintained. In fact, in every case of swallowed and missing object, the

nasopharynx should be kept in mind and searched for,^{5, 15} first with a Roentgenogram, which is diagnostic in case of a radio-opaque foreign body, followed by flexible nasopharyngoscopy and rigid nasendoscopy. Peroperatively, the individuality and rarity of such cases demand on-table manipulations and maneuvers that challenge a surgeon's innovative skills. Visualization often becomes difficult due to the small space and localized edema. In an uncomplicated case, removal of the foreign body under endoscopic visualization is possible. In most, as in our patient, where the need for manipulations is anticipated, it should be done under general anesthesia,¹⁴ with or without using an endoscope.

To conclude, in cases of foreign body aspiration, the lower respiratory tract is usually examined in its entirety. However, the possibilities of the nasopharynx harboring a missing object, presumably swallowed, should not be overlooked in a child. Therefore, if there is any suspicion at all of a foreign body aspiration, care should be taken to examine the upper as well as the lower respiratory tract. In this regard, the role of caregivers, including the parents, and their awareness about the risk of foreign body insertion, ways of insertion, places of health care availability, avoidance of self-treatment, and delay in formal care-seeking should be emphasized.¹⁶ A high degree of suspicion and proper investigations should reduce chances of morbidity and mortality in a potentially life-threatening case of nasopharyngeal foreign body, similar to the one we encountered and described above.

References:

1. Postma GN. Foreign Bodies. In: Expert Guide to Otolaryngology. Calhoun KH (Ed.). American Academy of Otolaryngology-Head and Neck Surgery; American College of Physicians, Philadelphia, Pennsylvania. P - 567.
2. Barretto RL, Holinger LD. In: Foreign Bodies of the Airway and Esophagus (Ch. 194); Pediatric Otolaryngology; Cummings: Otolaryngology: Head & Neck Surgery, 4th ed. 2005. Cummings CW, Flint PW, Haughey BH, Robbins KT, Thomas JR, Harker LA, Richardson MA, Schuller DE (Eds.). Mosby Inc.
3. Darrin DH, Holinger LD. Foreign body of the larynx, trachea and bronchi. In: Pediatric otolaryngology. 3rd ed. 1995. P - 1390. Bluestone CD, Stool S, Kenna MA (Eds.). Philadelphia: WB Saunders.
4. Carney AS, Patel N, Clarke R. Foreign bodies in the ear and the aerodigestive tract in children (Ch. 92); In: Scott-Brown's Otorhinolaryngology, Head and Neck Surgery; Gleeson M *et al* (Eds.). 7th ed, vol. 1. P - 1184. Hodder Arnold.
5. Singh RK, Varshney S, Bist SS, Gupta N. A rare nasopharyngeal foreign body. Online Journal of Health and Allied Sciences 2008; 7 (1): 42 – 44.
6. Middleton WG, Lawson VG. Fishing for foreign bodies. Otolaryngol 1986; 15: 124-6.
7. Sengupta A, Saha P, Chakrabarty S. Foreign body in the nasopharynx of a child. Indian J Otolaryngol Head Neck Surg 2005; 57 (3): 248 – 9.
8. Robb PJ. The adenoid and adenoidectomy (Ch. 84); In: Scott-Brown's Otorhinolaryngology, Head and Neck Surgery; Gleeson M *et al* (Eds.). 7th ed, vol. 1. p1098. Hodder Arnold.
9. Ogut F, Bereketoglu M, Bilgeric C, Totan S. A metal ring that had been lodged in a child's nasopharynx for 4 years. Ear Nose Throat J 2000; 80: 520 – 2.

10. Braverman I, Garfunkel AA, Rosenmann E, *et al.* A metal ring embedded in the hypopharynx. *J Otolaryngol* 1997; 26: 201-2.
11. Gulia JS, Kumar R, Sachdeva OP. Unusual foreign bodies in nasopharynx and bronchus. *Indian J Pediatr* 2002; 69: 273-74.
12. Gendeh BS, Gibb AG. An unusual foreign body presenting in nasopharynx. *J Laryngol Otol* 1988; 102: 641-2.
13. Rajesh, Pallavi, Singh R, Bakshi P. Nasopharyngeal foreign body: A rare entity with unique symptoms of AOM. *The Internet Journal of Otorhinolaryngology*. 2007; 6(2):112-117.
14. Muntz H. Foreign Body Management. In: *Pediatric Otolaryngology for the Clinician*, Mitchell RB, Pereira KD (Eds). Humana Press, Springer.
15. Parker AJ, Bingham BJ, Osborne JE. Swallowed foreign body: Is it in the Nasopharynx? *Postgrad Med J* 1988; 64: 201 - 3.
16. Mukherjee A, Haldar D, Dutta S, Dutta M, Saha J, Sinha R. Ear, nose and throat foreign bodies in children: A search for socio-demographic correlates. *Inter J Pediatr Otorhinolaryngol* 2011; 75(4): 510 – 12.