

Treatment of a Class II Division 2 malocclusion with Cover Bite and Severe Crowding in an Adult patient

Anwar N¹ BDS, Hassan S G² BDS, PhD; Ghosh R³ BDS, FCPS and Sajedeen M⁴ BDS,FCPS

ABSTRACT

This case report describes the orthodontic treatment of an adult patient, who presented an Angle Class II division 2 malocclusion, with deep traumatic overbite, retroclined incisors with proclined left maxillary lateral incisor and mild gingival recessions. Treatment of an adult Class II patient requires careful diagnosis and a treatment plan involving esthetic, occlusal, and functional considerations. The patient was treated with extraction of four first premolars to relieve crowding, with simultaneous correction of the deep bite by intrusion of the upper and/or lower incisors using fixed appliance mechanotherapy.

Key words: Angles Class II malocclusion, Deep traumatic overbite. (Bangladesh Journal of Orthodontics and Dentofacial Orthopedics, April 2013; Vol-3, No. 2, p 29-31)

INTRODUCTION

Class II malocclusions are frequently observed in orthodontic practice. Angle's designation of the Class II division 2 malocclusion presents a unique combination of overbite, incisor retroclination, and sagittal discrepancy. A severe form of this malocclusion with extremely deep overbite covering at least one mandibular incisor in occlusion has been called coverbite or Deckbiss in its early German descriptions.¹ Class II division 2 malocclusion is a clinical entity which shows considerable difficulty to achieve a stable treatment result.²

HISTORY AND DIAGNOSIS

This case report describes a 24 year old female patient came to the Orthodontic Department at BSMMU with the complaint of pain felt due to impingement of the palatal gingiva by lower incisors and labial gingival tissue with upper incisors.

Extraorally, she had broad face with straight profile, competent lips and deep mentolabial sulcus. The patient presented with Angles Class II division 2 malocclusion with retroclined incisors and proclined left maxillary lateral incisor, deep traumatic overbite. Both arches exhibited moderate to severe crowding. In addition the lower arch had a pronounced curve of spee (Figs 1 and 2).

Cephalometric tracing showed: It is a Class II skeletal pattern, ANB angle = 5°, (SNA = 84° and SNB = 79°) and normal mandibular growth (FMA = 24° and Y-axis =65 °). Figure 4 and Table 1.

TREATMENT OBJECTIVE

The treatment objectives include the chief complaint of the patient, and the treatment mechanics should be planned

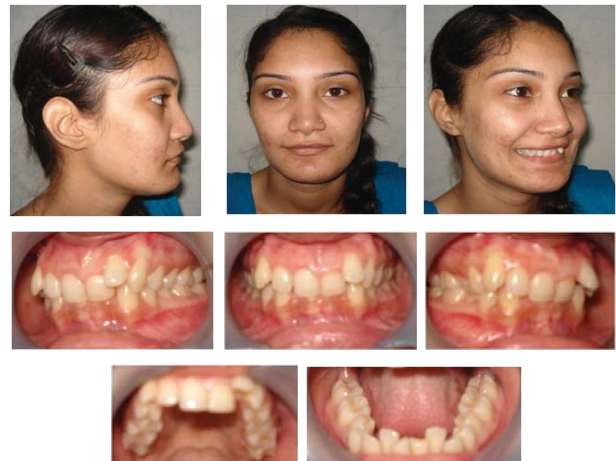

FIGURE 1: Initial facial and intraoral photographs

based on the specific treatment goals.³ The main objectives of treatment for this patient were to procline the maxillary incisors and to intrude the incisors to avoid impingement of gingival tissues. Alignment and levelling of the teeth on both jaws aimed to alleviate crowding. In addition, the esthetic appearance would be improved.

TREATMENT PROTOCOL

Considering that as she was an adult patient with a harmonious facial profile, we attempted to maintain the vertical, transverse and anteroposterior position of the bone bases. To achieve the proposed goals the patient was informed that the treatment plan involved the extraction of the first premolars in both jaws.

The treatment began with extraction of upper 1st premolars. As the lateral incisor (left side) overlapped the central

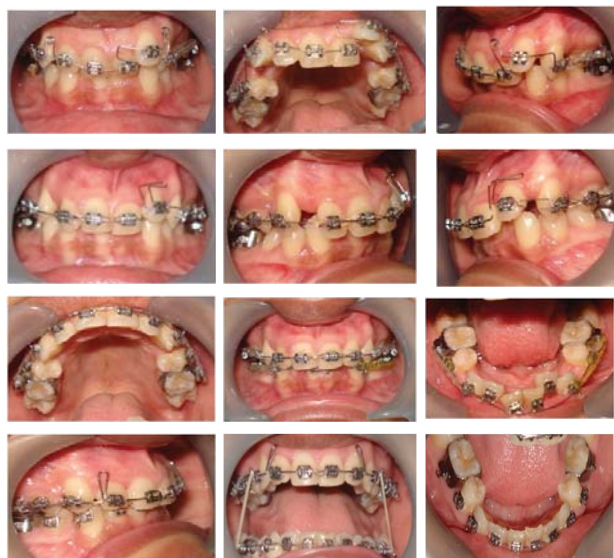

FIGURE 2: During different treatment stages

incisor, so the canines were first distally retracted. The anterior segment was flared simultaneously using multiloop 0.014 stainless steel arch wire containing helical and with an omega loop in front of molars. Canine retraction continued and subsequently 0.014 round stainless steel archwire with “L loop” was introduced to further align the lateral incisor.

After all the teeth were aligned properly in the arch with sufficient overjet and canine retraction then proceeded using power chain on 0.016 round stainless steel archwire.

Once sufficient overjet was achieved, brackets were bonded on the lower arch and the treatment in the lower jaw also began with extraction of 1st premolars followed by canine retraction. Leveling and alignment of anterior segment using round 0.014 stainless steel archwire to alleviate crowding. Upon achieving Class I canine relation, reverse curve of spee was used to correct deepbite.

For retraction of upper incisors, 0.017 x 0.025 rectangular stainless steel with loops between lateral incisors and canines were given and Class II intermaxillary elastics were prescribed to improve anchorage.⁴⁻⁶

Upon completion of space closure, final leveling was done using 0.017 x 0.025-in stainless steel archwire on the upper arch and 0.018 round stainless steel wire on the lower arch and the use of Class II elastics continued till the end of treatment. Impacted third molar extraction was prescribed at the beginning of the treatment.

The patient’s final records showed that the basal bones were unchanged with small anteroposterior change reflected in

slight movement of point A in maxilla probably due to correction of incisor inclination. This resulted in changing ANB from 5° to 4°, as seen in Table 1.

In the mandible there was no change in the position in the bone base. However, there was an increase in incisor inclination (IMPA angle from 85° to 99°). The inter incisal angle revealed a significant change from 155° to 129° (Table 1).

After ensuring that all the intended goals had been achieved the orthodontic appliance was removed and the retention phase began.

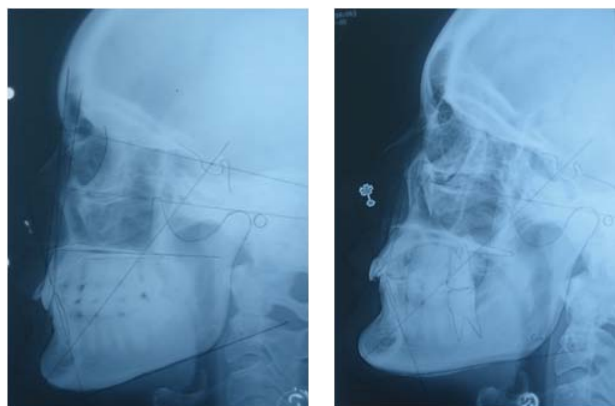


FIGURE 3: Pretreatment and post treatment cephalogram

TABLE 1: Summary of Cephalometric measurements

Measurements	Normal	Pre treatment	Post treatment
SNA (Steiner)	82°	84°	82°
SNB (Steiner)	80°	79°	78°
ANB (Steiner)	4°	5°	4°
Interincisal angle (Downs)	130°	155°	129°
Y-axis (Downs)	59°	68°	68°
FMA (Tweed)	25°	24°	26°
IMPA (Tweed)	91°	85°	99°

DISCUSSION

Deep traumatic overbite is mostly associated with a Class II incisor relationship, with an associated skeletal Class II and sometimes in skeletal Class III occlusion with reverse overjet. Anterior traumatic bite is very injurious to the dental and periodontal health and it results in attrition, crowding, mobility and inability to maintain oral hygiene, gingival

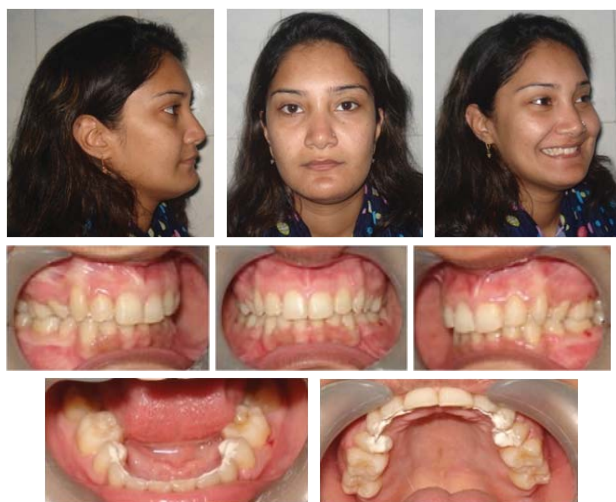

FIGURE 4: Final facial and intra oral photographs

recession and alveolar defects.⁷ Class II malocclusion can be corrected in different ways depending on the age and severity. Correction of class II deep bite can be by orthodontic treatment alone or by combination of orthodontic and orthognathic surgery. Orthognathic surgery is indicated when dental discrepancy cannot be corrected by the use of orthodontic mechanotherapy alone or when facial aesthetics are compromised.⁸ Deep bite correction can be achieved during periods of active growth and this found to be more stable. In most cases, it requires prolong retention with a removable appliance and a bite plane incorporated to it. Usually treatment protocol of skeletal class II and anterior deep bite cases depend on the age and stage of skeletal growth. Functional growth modulators have shown promising results at the early or late stages of puberty.

In the present case, because our patient was an adult with class II deepbite, fixed mechanotherapy was our sole

treatment choice. Treatment was focused to relieve crowding and to avoid traumatic occlusion. The dental occlusion showed an improved intercuspation on both sides and treatment was finished with a class II molar relation and class I canine relation as well as an adequate overjet and overbite. During upper incisor retraction as well as during the finishing phase it became necessary to use Class II⁹ elastic mechanics to facilitate anchorage control in view of some initial difficulties. The gingival trauma which had been noted initially was quite improved after treatment.

CONCLUSION

Treatment of class II division 2 malocclusion is always challenging. Each technique of deep bite correction has its advantages and disadvantages and must be carefully selected considering the specific etiology of the individual's malocclusion and the desired treatment outcome.

REFERENCES

1. Andrews LF. The six keys to normal occlusion. *Am. J. Orthod.* 1972 sep; 62(3); 296-309.
2. Kuhlberg, A. and Glynn, E.: Treatment planning considerations for adult patients, *Dent. Clin. N. Am.* 41:17-28, 1997.
3. Cleall JF, BeGole EA. Diagnosis and treatment of Class II, Division 2 malocclusion. *Angle Orthod* 1982;52:38-60.
4. Ricketts RM. Bioprogressive therapy as an answer to orthodontic needs. Part I. *Am J Orthod.* 1976 Sep;70(3):241-68.
5. Ricketts RM. Bioprogressive therapy as an answer to orthodontic needs. Part II. *Am J Orthod.* 1976 Oct;70(4):359-97.
6. Nanda R. Biomechanics in clinical Orthodontics. 9th ed. Philadelphia: W. B. Saunders;1997.
7. Ustun K, Sari Z, Orucoglu H, Duran I, Hakki SS. Severe gingival recession caused by traumatic occlusion and mucogingival stress, *Euro J Dent*, 2008,2; 127-133.
8. Wong RW. Combined orthodontic dentofacial orthopaedic treatment of a class II division 2 patient with severe deep bite, *J Orthod*, 2002; 29; 181-188.
9. Tweed CH. *Clinical Orthodontics*. St. Louis: C. V. Mosby; 1966.

Correspondence

Dr. Nabila Anwar BDS
FCPS (Part II Trainee)
Dept. Of Orthodontics and Dentofacial Orthopaedics
Bangabandhu Sheikh Mujib Medical University (BSMMU)
Shahbag, Dhaka
Cell- 01819153000, Email- nabila_h2000@yahoo.com