

## *Orthodontic Management Of A Girl With Class II Div-2 Malocclusion With Deep Bite & Crowding: A Case Report*

Nargish S<sup>1</sup> BDS, Hossain MZ<sup>2</sup> BDS, PhD

### ABSTRACT

We describe the treatment of a girl, age 18 years with Class II div-2 malocclusion with deep bite and crowding. Treatment consisted mainly of bite opening, 1st premolars extractions, canine retraction, arch co-ordination, leveling and alignment with Edgewise fixed appliances by multiloop technique. However the treatment resulted in Class I incisor relation with proper alignment of upper and lower anterior segment, an ideal overjet, overbite and incisor angulations.

Key words : **Class II div-2 malocclusion, deep bite, class II skeletal base, sectional archwire, edgewise orthodontic therapy.**

### INTRODUCTION

At the beginning of the 20th century, Edward H. Angle<sup>1-3</sup> differentiated between the first and second divisions of his Class II type of malocclusion. In Class II division 2 the molar relationship is Class II. Upper central incisors are retroclined and overlapped by the lateral incisors. Common clinical features of Class II division 2 malocclusion are:

1. Squarish face.
2. Straight to mildly convex profile.
3. Upper lip is invariably short and positioned high.
4. Lower lip is thick flabby covering the upper incisors.
5. Shallow mento-labial sulcus.<sup>4</sup>

### HISTORY AND DIAGNOSIS

An 18 year Female came to the department of Orthodontics and Dentofacial Orthopedics, Dhaka Dental College and Hospital with the chief complaint of upper and lower jaw crowding with retroclined upper central incisors and proclined lateral incisors. Patient's major reason for seeking treatment was to improve her dental esthetics and function. She complained of his odd look during smile and difficulties to bite with her teeth.

The patient was in the permanent dentition. She had no relevant dental, medical or family history and had no history of previous orthodontic treatment.

On extraoral examination we found that she had a symmetric face with a convex profile. Lips are competent. Her TMJ was alright and had a normal path of closure. [Fig: 1]

Intraoral examination showed that severe crowding of teeth was present in the anterior region of both upper and lower arch. In occlusion she had a 4mm over jet and 6mm overbite. There was Class II molar and canine relation and there was no premature contact or any other pathology. [fig:2]

On model analysis, the arch length deficiencies were (-8.5)mm in the maxillary arch and (-12.5)mm in the mandibular arch.

Panoramic radiographs revealed that all the permanent teeth were present except all the third molars whereas right sided third molar was impacted. [Fig: 4A]

Cephalometric evaluation showed that she had a skeletal Class II relationship. [Fig: 5A]

### TREATMENT OBJECTIVES

Considering the above findings the objectives of orthodontic treatment of this patient were to:

1. Relief of crowding in upper and lower arch.
2. Establish normal overjet and overbite.
3. Establish normal interincisal angle.
4. Maintain occlusal harmony and interdigitation.
5. Improvement of aesthetics and function.

### TREATMENT PLAN AND PROGRESS

As the arch length discrepancies were large in both the jaws, all 4 first premolars were extracted and treatment started with fixed appliance. Due to severe crowding in upper and lower arch, first canine retraction was done by using segmental arch wire with 0.016 inch stainless steel arch wires. After canine retraction, initial leveling of upper and lower jaw was done with the use of 0.014 multiloop arch wires over 3 months.

The remaining extraction space on both arches was closed by using 0.016 × 0.022 inch rectangular arch wires with tear drop contraction loops. Arch co-ordination and interdigitation was achieved by using updown elastics. Finally, after satisfactory interdigitation was achieved, the fixed appliances were removed. Then maxillary and mandibular removable retainers were placed. The active orthodontic treatment time was 18 months.

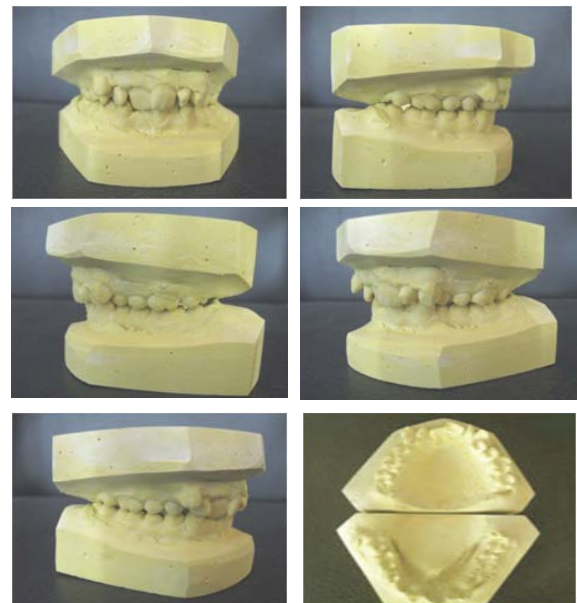


Fig2: Pretreatment intraoral model photographs

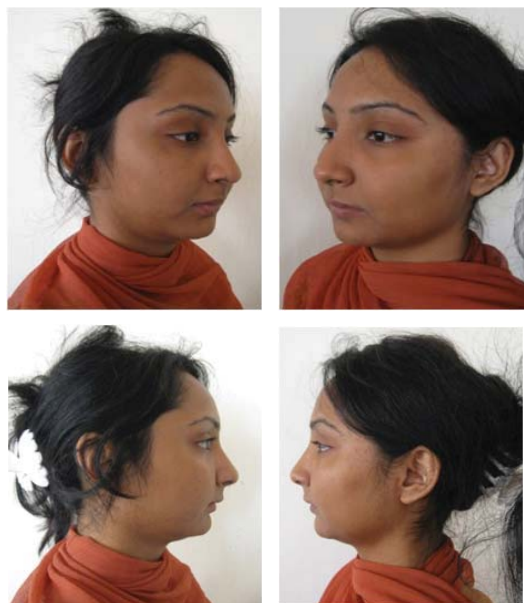

Fig1: Extraoral photograph (before treatment)

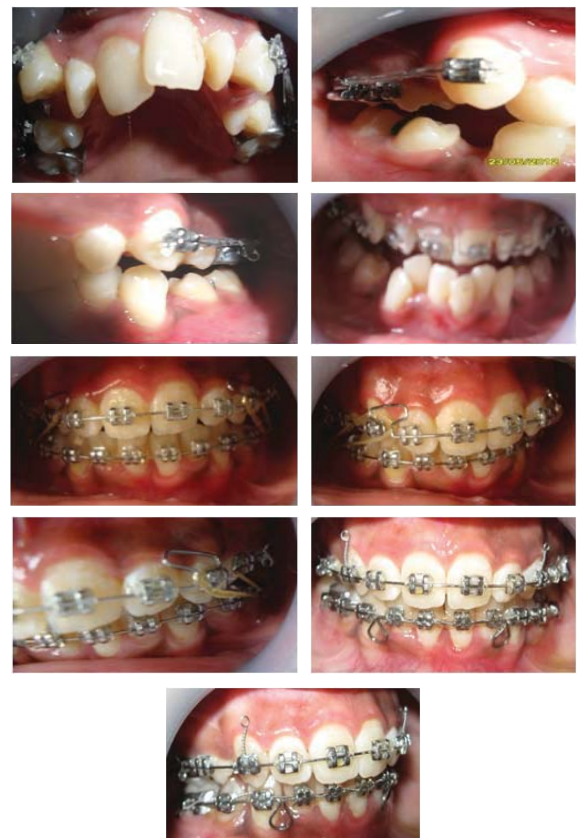

Fig3: Progress intraoral photograph

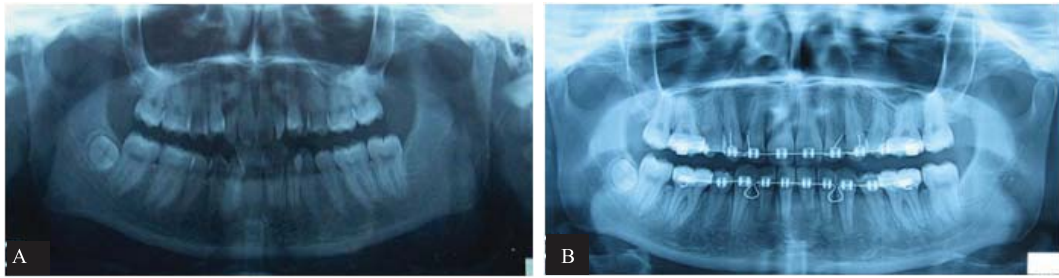


Fig4: Panoramic Radiograph before (A) and after treatment (B)

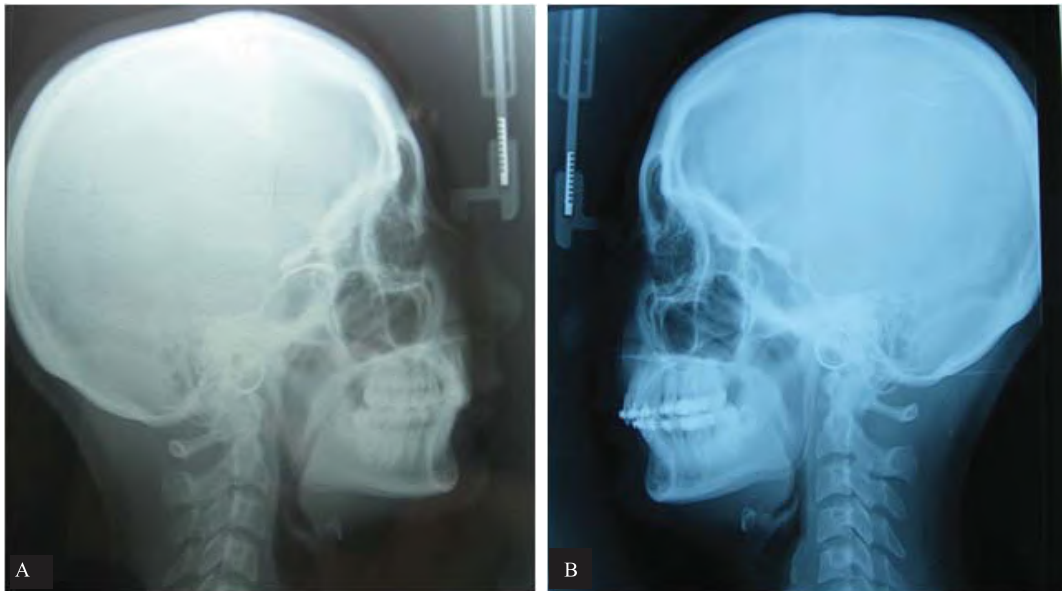

Fig5: Cephalogram before (A) and after treatment (B)

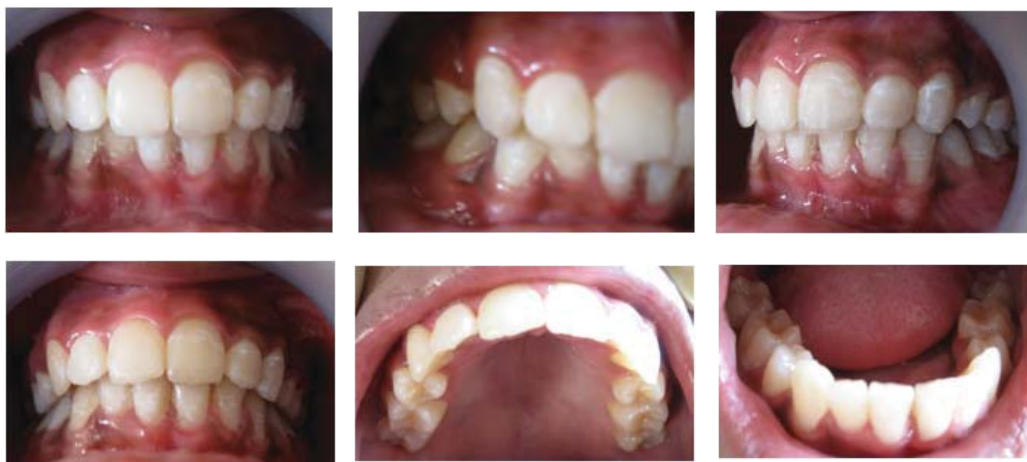

Fig6: Intraoral photograph after treatment

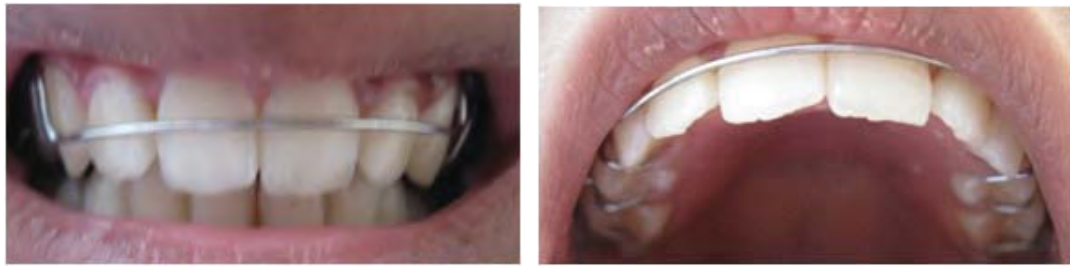

Fig7: With Hawley retainer

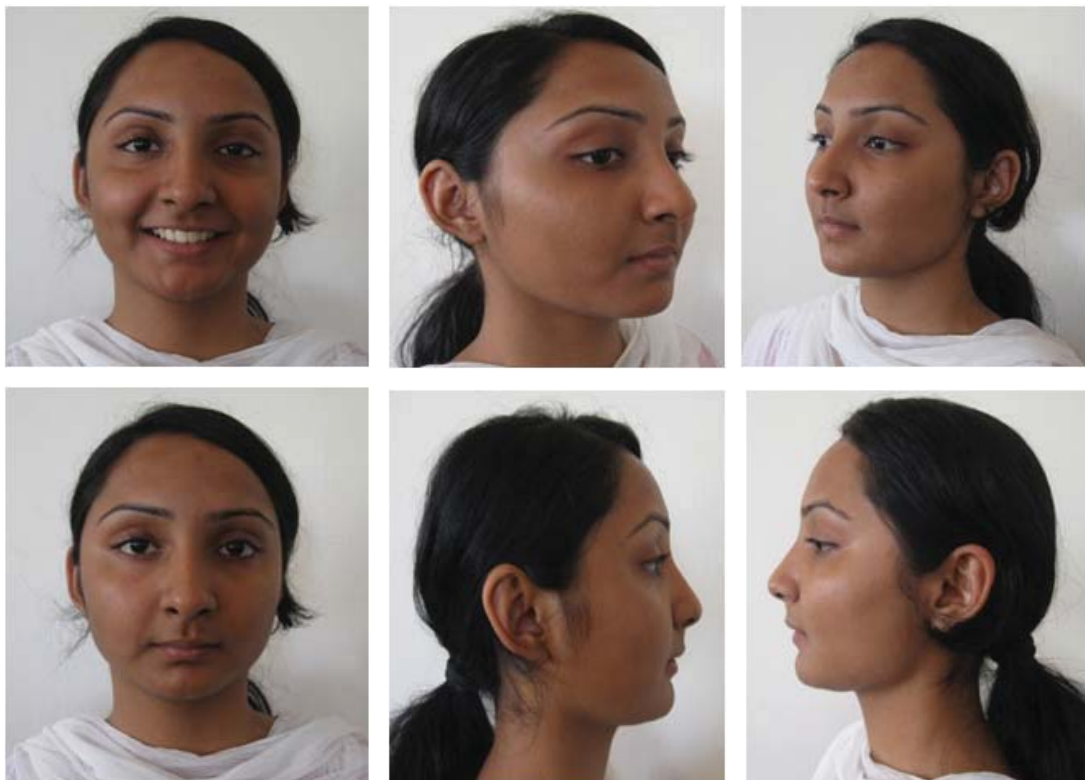

Fig8: Extraoral photograph after treatment

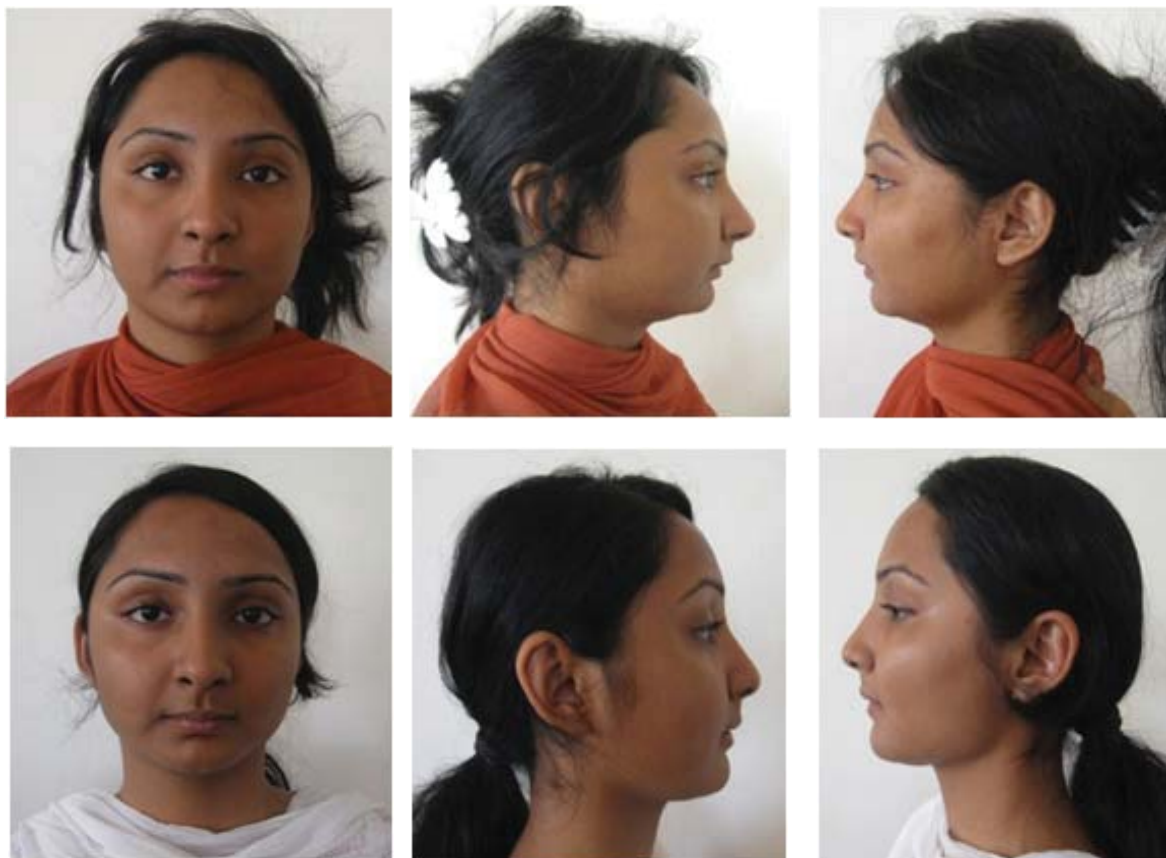

Fig9: Before and After treatment extra oral photograph

LATERAL CEPHALOGRAM: Steiner's analysis

| Parameters | Reference value<br>(Caucasians)<br>Ref: Om P Kharbanda.<br>Orthodontics Diagnosis and<br>Management of<br>Malocclusion and<br>Dentofacial Deformities,;<br>Elsevier 2009 edition. | Reference Value<br>(Bangladeshi)<br>Ref: Rizvi HM, Hossain MZ.<br>Cephalometric norms of young<br>adults of Bangladesh ( Steiner's<br>analysis )- APOS Trends in<br>Orthodontics January<br>2013 vol-3 issue 1. | Pt's measurement    |                    |
|------------|---|---|---------------------|--------------------|
|            |   |   | Before<br>treatment | After<br>treatment |
| SNA°       | 82°   | 83.8°   | 790                 | 800                |
| SNB°       | 80°   | 81.5°   | 700                 | 730                |
| ANB°       | 2°  | 2.3°  | 90                  | 70                 |
| IIA°       | 131°  | 117.7°  | 1540                | 1340               |
| MPA°       | 32°   | 25.8°   | 300                 | 280                |

#### **RESULTS AND DISCUSSION:**

The Class I molar and canine relationship were established and maintained with satisfactory interdigitation. The overjet and the overbite were improved. The lips were competent and the dentition and the periodontal tissues remained healthy.

Post treatment panoramic radiograph (fig:4) shows good parallelism of roots and normal structure of periodontium. No sign of root resorption was seen. The post treatment cephalometric radiograph (fig:5) shows a balanced facial profile. Before and after treatment cephalometric analysis showed the ANB angle and interincisal angle decreased compared with before treatment. Dental measurements did not changes significantly. A functional and good looking occlusal result was achieved. The patient was satisfied with her teeth and profile.

#### **REFERENCES:**

1. Angle EH. Classification of malocclusion. Dent Cosmos 1899; 41:248-64, 350-7.
2. Angle EH. Treatment of malocclusion the teeth and fractures of the maxillae. 6th ed. Philadelphia: S. S. White Dental Manufacturing CO; 1900.p. 37-40.
3. Angle EH. Treatment of malocclusion the teeth. Angle's system. 6th ed. Philadelphia: S. S. White Dental Manufacturing CO; 1907.p. 50-1.
4. Singh G. Etiology and management of Class II malocclusion: Textbook of Orthodontics. 2nd ed.570-574, 2007.

#### **CORRESPONDENCE:**

---

Dr. Shamima Nargish, BDS  
FCPS-II Trainee  
Dept. of Orthodontics and Dentofacial Orthopedic  
Dhaka dental College and Hospital  
Mirpur-14, Dhaka-1206  
Mobile: +8801720189717, E-mail: dr.ivey34@gmail.com