

The effects of orthodontic tooth movement in endodontically treated teeth

Haque S¹, Zakir M²

ABSTRACT

There are no relevant contraindications to orthodontic treatment of previously endodontically treated teeth, considering the quality of the obturated teeth, the health of the periodontal membrane, along with careful application of orthodontic force. Although, there is usually some degree of reversible or transient pulpal inflammation even in healthy teeth during orthodontic treatment, application of light and intermittent orthodontic force will reduce the risks provided sufficient time is given to allow proper repair of the dental tissue. However, there may be a few hazards associated with the treatment of endodontically involved teeth, some of which mainly include root resorption and ankylosis. This article will show some cases of teeth which had undergone root canal treatment prior to orthodontic management and further observed whether orthodontic tooth movement had caused any resorption in the root filled teeth. Root canal treated teeth can be moved orthodontically to the same extent as vital teeth, providing, a controlled force application to avoid risk of inflammatory root resorption.

Keywords: Orthodontic tooth movement; root canal treatment; root resorption

INTRODUCTION

Microscopic root resorption is a distinct feature in all permanent teeth during orthodontic treatment. It is clinically insignificant and radiologically invisible. Orthodontic tooth movement would not be possible without this resorption.¹ If there is evidence of pulp necrosis and bacterial infection, endodontic management is required prior to orthodontic treatment. Endodontically treated teeth that are well cleaned, shaped, and properly obturated may exhibit minimal resorptive and remodeling changes apically when moved orthodontically. If a previously traumatized tooth exhibits resorption before orthodontic treatment, there is a greater chance that orthodontic treatment will enhance the resorptive process. If a tooth has been severely traumatized (intrusive, luxation or avulsion) there may be a greater incidence of resorption with tooth movement. This can occur with or without previous endodontic treatment.² Pulpals in teeth with incomplete apical foramen, whilst not immune to adverse sequelae during tooth movement, have a reduced risk for those responses.²

Likewise, little is known about the potential risk or sequelae in moving teeth that have had previous surgical intervention especially about the long term prognosis of this type of treatment.²

Moreover, there is no such clinical study that has been published in Bangladesh. The aim is to document some case reports that have been treated orthodontically after endodontic treatment.

CASE SUMMARY

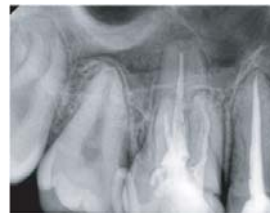

Fig: 1.1

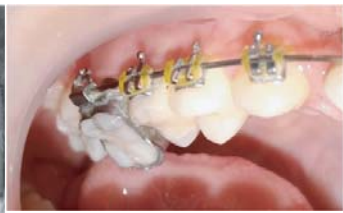

Fig: 1.2

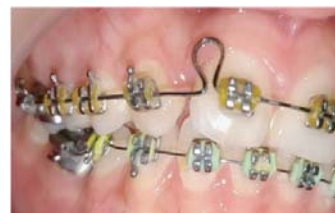

Fig: 1.3

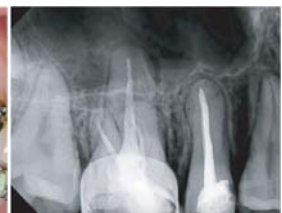

Fig: 1.4

Fig 1.1 showing a 15 year old female patient's post obturation radiograph on tooth number 15 and 16 before commencing orthodontic treatment around eighteen months ago. Current treatment photo (Fig 1.2 and 1.3) showing fixed orthodontic appliance along with no evidence of root resorption. (Fig 1.4)

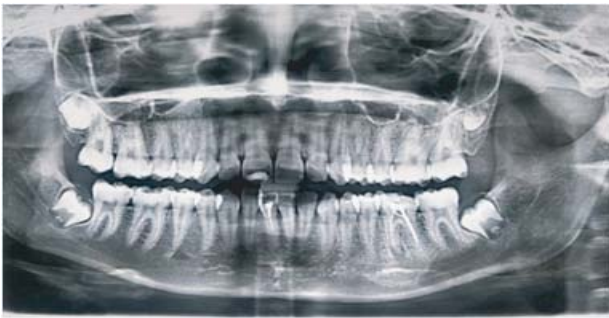

Fig: 2.1

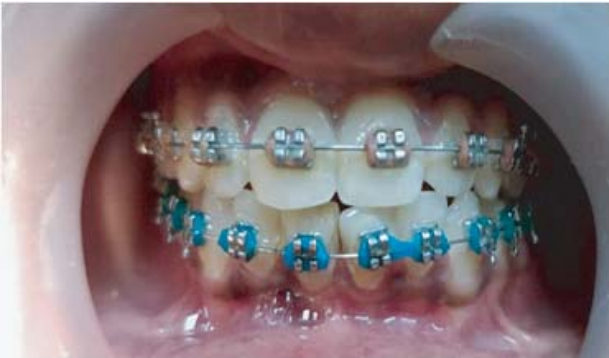

Fig: 2.2

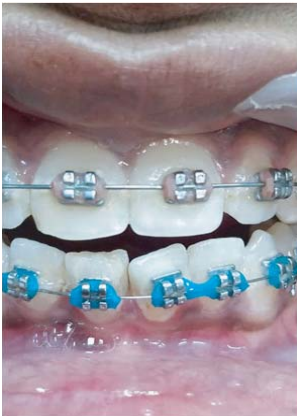

Fig: 2.3

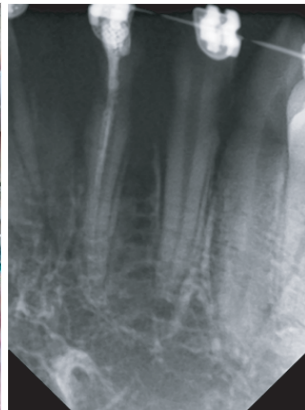


Fig: 2.4

This fifteen year old female patient already had a root filled tooth number 41 which was done three years ago (Fig 2.1). Orthodontic treatment was started about a year ago. Most recent photographs (Fig 2.2 and 2.3) and radiograph (Fig 2.4) of 41 showing no visible sign of resorption despite the tooth being under-filled.

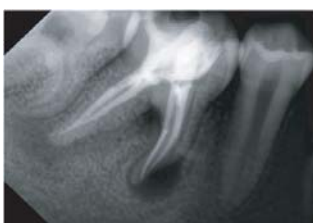

Fig: 3.1

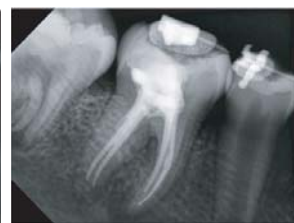

Fig: 3.2

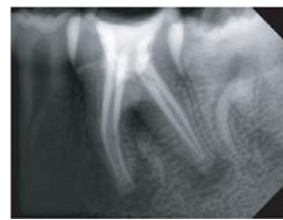


Fig: 4.1

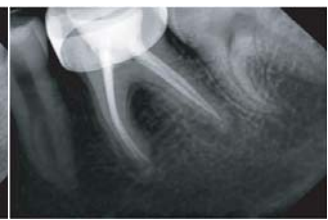

Fig: 4.2

Fig 3.1 and 3.2 shows a comparison of radiographs of tooth 46 before and during orthodontic treatment on a fourteen year old patient. There has been a significant improvement in the radiolouency which was present during the root canal treatment. Fig 4.1 and 4.2 showing tooth 36 with similar changes. No resorptive changes noted in both the anchor teeth.

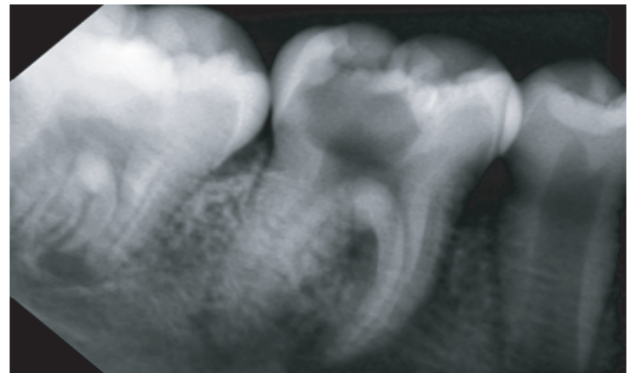


Fig: 5.1

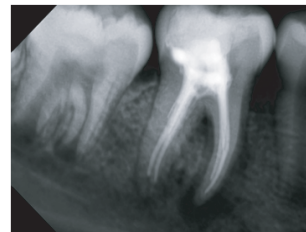


Fig: 5.2

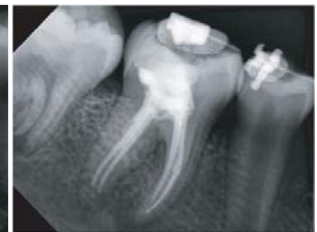

Fig: 5.3

Thirteen years old patient had to undergo root canal treatment due to grossly carious 36. (Fig 5.1 and 5.2) followed by bonding of the lower arch using fixed orthodontic appliance. Six months later, radiograph (Fig 5.3) showing sound teeth with no changes in the root after application of mild orthodontic forces.

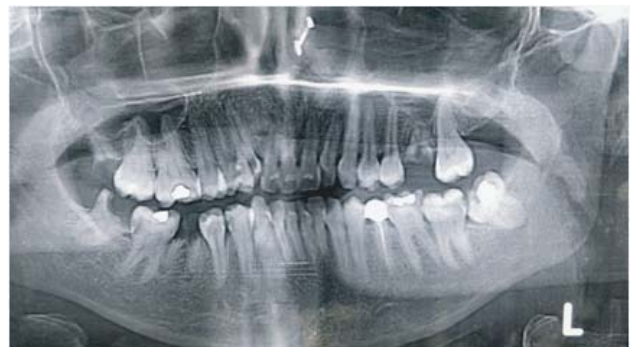

Fig: 6.1

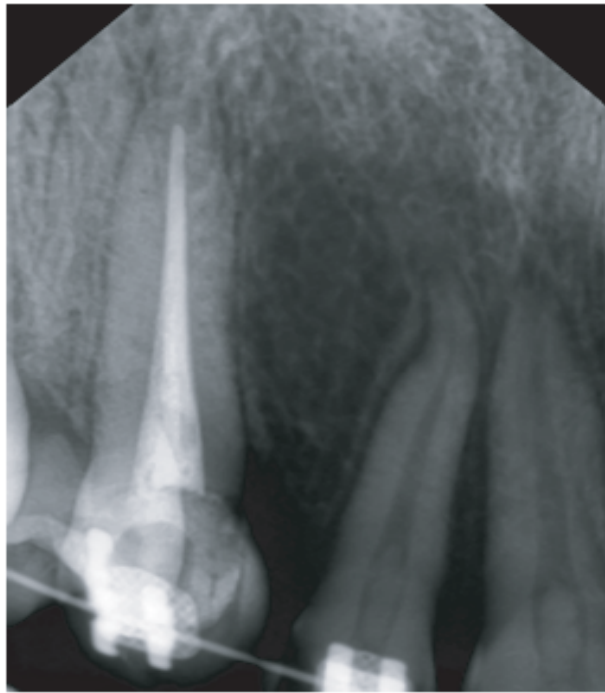

Fig: 6.2

Orthopantomogram of a twenty one years old female patient showing grossly carious 13 (Fig 6.1). Root canal treatment of the patient was done two years ago prior to orthodontic treatment. Most recent radiograph (Fig 6.2) showing the tooth with no remarkable changes.

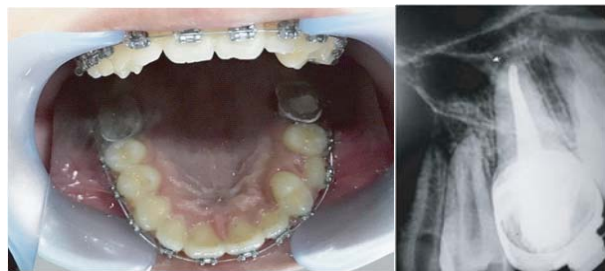


Fig: 7.1

Fig: 7.2

This patient had started her root canal treatment on 36 before bonding of the lower arch with fixed appliance, around a year ago. Fig. 7.1 and 7.2 shows the most recent finding where the tooth is both clinically and radiographically sound.

DISCUSSION:

Orthodontic tooth movement is based on application of force to the teeth for a certain period of time which may vary between months or years. This movement inevitably causes biological reactions in the periodontal ligament and the pulp. The clinical importance of pulpal alteration after orthodontic force depends on whether or not it will endanger the long term viability of the teeth. Orthodontic treatment prognosis of endodontically treated teeth depends on the type, the

severity and the timing of the trauma as well as the management of the case by the dental professional.³

Although the orthodontic movement of teeth without pulp is possible, there are some questions associated with this movement. Some authors believe that teeth that have undergone root canal therapy are more susceptible to root resorption,⁴ whereas other authors found no significant difference.^{5,6,7} Wickwire et al.⁴ examined the effect of pulpectomy on tooth movement and showed that teeth without pulp are subject to a greater degree of resorption when compared to teeth with vitality. Bender et al.⁸ observed greater resorption for vital teeth compared with endodontically treated teeth. Similarly, the endodontically treated teeth resorbed less frequently and with less severity than homologous teeth with vitality; however, there was no statistically significant difference between the degrees of root resorption.⁹⁻¹²

The long term consequences of the tooth roots that have undergone moderate to severe resorption is still questionable. Researchers have re-evaluated patients with moderate to severe root resorption many years after orthodontic treatment^{12, 13, 14} and have found that root resorption stops after orthodontic treatment has been discontinued. Although there may be some remodeling of the irregular resorbed edges of the root with time due to reparative deposition of cellular cementum, this type of remodeling merely produces a smoother surface in the long term. However the length of the root does not continue to shorten after removal of orthodontic appliance.³

Another relevant detail to endodontically treated teeth is ankylosis. According to Biederman, 15 ankylosis is caused by a disturbance in the local metabolism of the periodontal ligament, resulting in the fusion of the alveolar bone with the cement. Ankylosis can be caused by disturbance of the alveolar bone and/or the periodontal ligament, originated in the orthodontic movement.

Limitations

- Even though the present study described a few case reports with minimal or no resorption, further clinical reports with mass volume is required to make a decisive conclusion.

- Root resorption of the teeth was only studied using digital radiography.

CONCLUSION:

Understanding the endo-ortho relationship is essential for a successful treatment outcome. The prognosis of any compromised treatment depends mainly on the quality of the root canal treatment and the health of the periodontal membrane. From the evidence available, it is clear that root canal treated teeth can be moved orthodontically to the same extent as vital teeth, providing, a controlled force application to avoid risk of inflammatory root resorption. Good clinical and radiographic assessment is important prior to planning to ensure the best treatment outcome.

REFERENCES:

1. Kristina Lopatiene, Aiste Dumbraivaite. Risk factors of root resorption after orthodontic treatment. *Stomatologija, Baltic Dental and Maxillofacial Journal*, 2008; 10: 89-95.
2. Aydin H, Er K. The effect of orthodontic tooth movement on endodontically treated teeth. *J Res Dent* 2016;4:31-41
3. Kokich VG. Orthodontic and nonorthodontic root resorption: their impact on clinical dental practice. *J Dent Educ*. 2008;72:895–902.
4. Wickwire NA, Mc Neil MH, Norton LA, Duell RC. The effects of tooth movement upon endodontically treated teeth. *Angle Orthod* 1974;44:235-42.
5. Huettner RI, Shore B, Young RW. The movability of vital and devitalized teeth in the Macacus rhesus monkey. *Am J Orthod* 1955;41:594.
6. Mah R, Holland GR, Pehowich E. Periapical changes after orthodontic movement of root-filled ferret canines. *J Endod* 1996;22:298-303.
7. Odenrick L, Brattström V. Nailbiting: Frequency and association with root resorption during orthodontic treatment. *Br J Orthod* 1985;12:78-81.
8. Bender IB, Byers MR, Mori K. Periapical replacement resorption of permanent, vital, endodontically treated incisors after orthodontic movement: Report of two cases. *J Endod* 1997;23:768-73.
9. Kreia TB, Tanaka O, Lara F, Souza ES, Maruo H, Westphalen VP. Evaluation resorption after orthodontic treatment in endodontically treated teeth. *J Dent Sci* 2005;20:50.
10. Mattison GD, Delivanis HP, Delivanis PD, Johns PI. Orthodontic root resorption of vital and endodontically treated teeth. *J Endod* 1984;10:354-8.
11. Brezniak N, Wasserstein A. Root resorption after orthodontic treatment: Part 2. Literature review. *Am J Orthod Dentofacial Orthop* 1993;103:138-46.
12. Remington DN, Joondeph DR, Artun J, Riedel RA, Chapko MK. Long-term evaluation of root resorption occurring during orthodontic treatment. *Am J Orthod Dentofacial Orthop* 1989;96:43-6.
13. Levander E, Malmgren O. Long-term follow-up of maxillary incisors with severe apical root resorption. *Eur J Orthod* 2000; 22:85–92.
14. Becker A, Chaushu S. Long-term follow-up of severely resorbed maxillary incisors after resolution of an etiologically associated impacted canine. *Am J Orthod Dentofacial Orthop* 2005; 127:650–4.
15. Biederman W. The incidence and etiology of tooth ankylosis. *Am J Orthod* 1956;42:921.

Correspondence:

Dr. Sabrina Haque

BDS, MS (Conservative Dentistry and Endodontics)
Associate Professor
Department of Conservative Dentistry and Endodontics
Dhaka Dental College
Mirpur, Dhaka.