

## *Orthodontic Management of Class-I Crowding in an Adult Male: A Case Report*

Nargish S<sup>1</sup>, Hossain MZ<sup>2</sup>

### **ABSTRACT**

A 20 years old male presented with class-I malocclusion with crowding and lock bite on upper right and left lateral incisors. Treatment involved extraction of all first premolars. The alignment of teeth of both arch was achieved by edgewise orthodontic therapy.

**Key Words:** Class I malocclusion, crowding, edgewise orthodontic therapy

### **INTRODUCTION**

Crowding of the teeth is the most common type of malocclusion at present. Undoubtedly it is related in part to the continuing reduction in jaw and tooth size in human evolutionary development. Jaw dimensions do seem to have a strong genetic control. Environmental factors must have played some role in the recent increase in crowding of the dental arches.<sup>1</sup>

### **HISTORY AND DIAGNOSIS**

A 20 year old male came to the department of Orthodontics and Dentofacial Orthopedics, Dhaka Dental College and Hospital with the chief complaint of crowding on upper and lower jaw with lock bite on upper right and left lateral incisors.

The patient was in the permanent dentition. He had no relevant dental, medical or family history and had no history of previous orthodontic treatment.

On extraoral examination (Fig:1) he had a symmetric face with a straight profile. Lips are competent. His TMJ was alright and had a normal path of closure.

Clinical examination (Fig:2) showed crowding in both upper and lower arch and upper right and left lateral incisors were in crossbite. There was total of 10 mm crowding in maxilla and 5.5mm crowding in the mandibular arch. He had Class II molar relationship with 3mm overjet and 4mm overbite. There was no premature contact or any other pathology.

Radiographic examination (Fig:3) showed a full permanent dentition and a Class I skeletal pattern(Fig:4).

### **TREATMENT OBJECTIVES**

Considering the above findings the objectives of orthodontic treatment of this patient were to:

1. Eliminate the crowding present in the upper and lower arch.
2. Correct the crossbite.

3. Establish and maintain a Class I molar and canine relation ship.
4. Establish normal overjet and overbite.
5. Establish and maintain occlusal harmony and interdigitation for improved aesthetics and proper function.

### **TREATMENT PLAN AND PROGRESS**

Due to the severity of crowding, the first option of treatment plan was to extract all the first premolars to provide space for alignment. Standard edgewise 0.018-inch slot bracket was bonded, Anchorage was enforced with a anchorage plate. Initial leveling was done with the use of 0.014-inch stainless steel arch wire with multiloop over 3 months. Then upper canines are retracted by using segments of elastomeric chain on 0.016-inch stainless steel archwires with a nickel-titanium coil spring. After closing the extraction space, 0.014 inch stainless steel with 'L' loops was placed to correct the cross bite of upper lateral incisors. In this stage bite opened by using posterior bite plane to free the lock.

In the lower arch, our approach was by sectional arch wire. As the lower canines were out of the arch, first canine retraction was done by sectional arch wire. Then leveling and alignment was done by 0.014 multiloop arch wires. The remaining extraction space on both arches was closed with tear drop contraction loops on 0.016x 0.022 inch rectangular stainless steel arch wires.

Finally arch coordination and interdigitation was done by updown elastics. The total treatment procedure required 24 months.



Fig1: Extraoral photograph (before treatment)

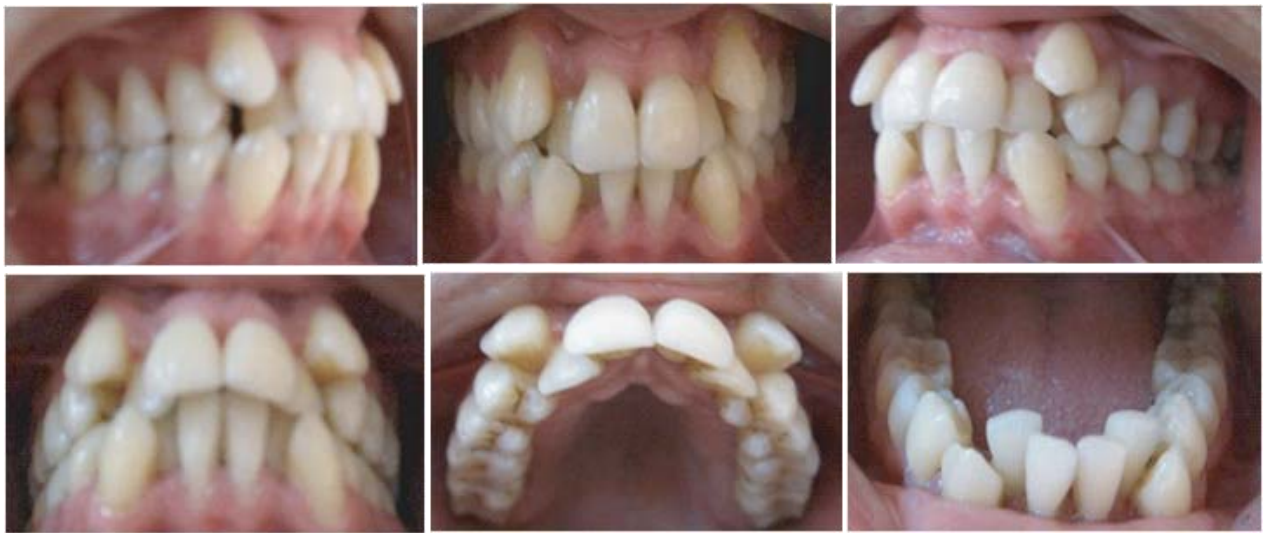

Fig2: Pretreatment intraoral photographs

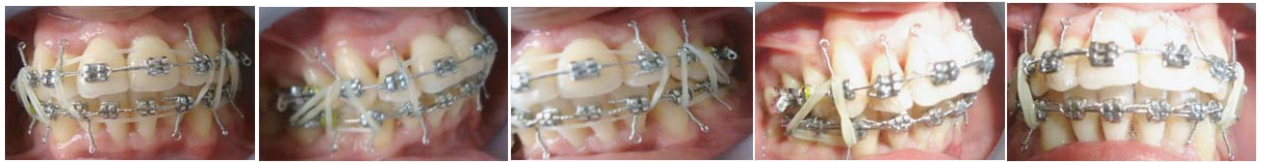

Fig3: Progress intraoral photograph

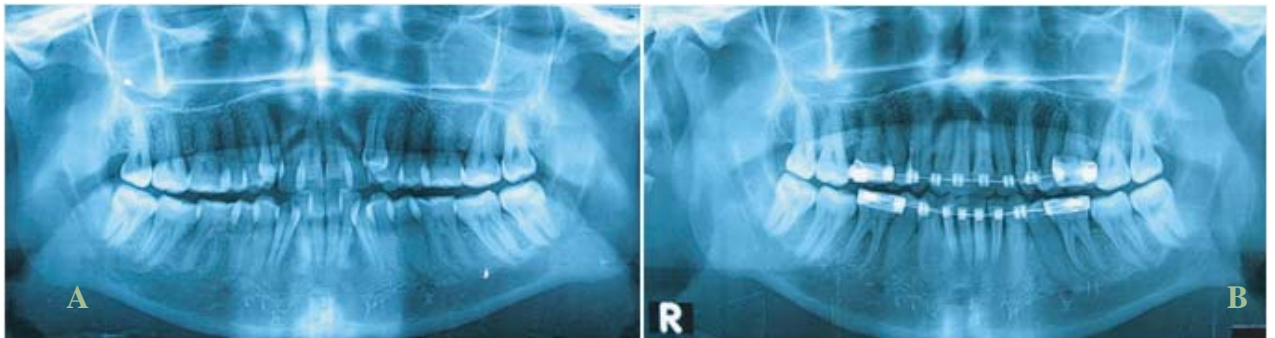

Fig4: Panoramic Radiograph before (A) and after treatment (B)

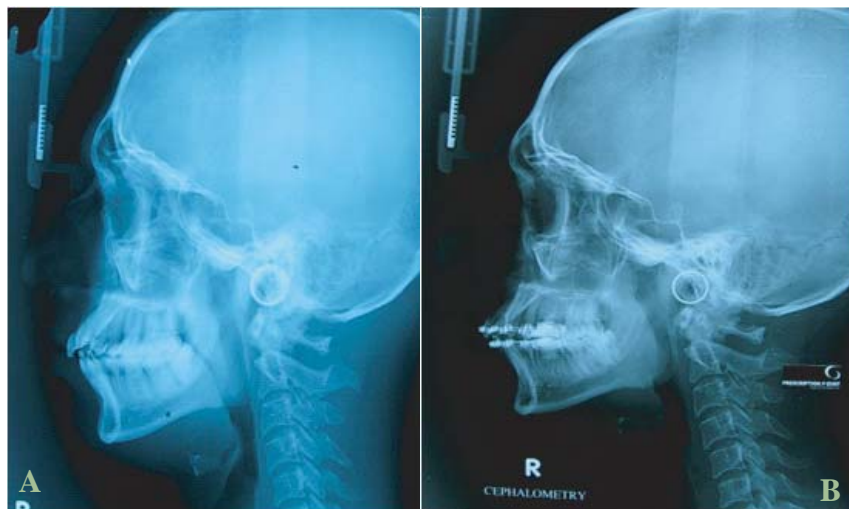


Fig5: Cephalogram before (A) and after treatment (B)

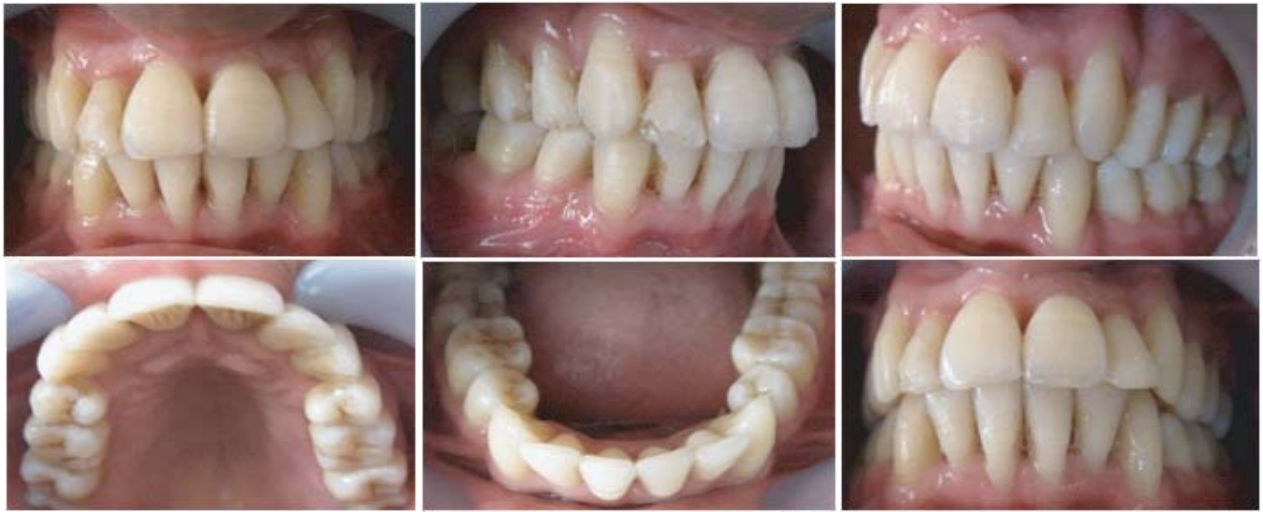

Fig6: Intraoral photograph after treatment



A

Fig7: Extraoral photograph after treatment

B



A

Fig 8 : Before and After treatment extra oral photograph

B

LATERAL CEPHALOGRAM: Steiner's Analysis

| Parameters  | Reference value<br>(Caucasians) <sup>2</sup> | Reference Value<br>(Bangladeshi) <sup>3</sup> | Patient's measurement |                 |
|-------------|--|---|-----------------------|-----------------|
|             |  |   | Before treatment      | After treatment |
| SNA°        | 82°  | 83.8°   | 82°                   | 83°             |
| SNB°        | 80°  | 81.5°   | 73°                   | 77°             |
| ANB°        | 2°   | 2.3°  | 9°                    | 6°              |
| IIA°        | 131°   | 117.7°  | 108°                  | 107°            |
| MPA°        | 32°  | 25.8°   | 35°                   | 33°             |
| U1 to NA°   | 22°  | 29.8°   | 30°                   | 30°             |
| U1 to NA mm | 4mm  | 8mm   | 5mm                   | 6mm             |
| L1 to NB°   | 25°  | 30.6°   | 35°                   | 39°             |
| L1 to NB mm | 4mm  | 8mm   | 9mm                   | 10mm            |

**RESULTS AND DISCUSSION**

Total treatment time was 24 month, this is partly related to the long treatment time required to totally retract the canines. Post treatment records shows that the treatment objectives were achieved. Facial photographs (Fig:8) shows an improved profile and an attractive smile. Class I canine (Class II canine relation on left side) and molar relationships were established with canine-protected occlusion. Ideal overjet and overbite were achieved. Proper alignment and nice gingival contour were attained (Fig:6).

Post treatment panoramic radiographs (Fig:4B) shows good parallelism of roots and normal structure of the periodontium. No sign of root resorption was seen.

The post-treatment lateral cephalometric radiograph (fig:5B) shows a balanced facial profile. Cephalometric analysis

showed a Class I skeletal relationship, the ANB angle decreased slightly. Dental measurements did not change significantly. A functional and good-looking occlusal result was achieved. The patient was satisfied with his teeth and profile.

**REFERENCES**

1. Proffit WR, Fields HW. Contemporary Orthodontics. 4th ed. St Louis; Mosby; 2001;P-159.
2. : Om P Kharbanda. Orthodontics Diagnosis and Management of Malocclusion and Dentofacial Deformities: Elsevier 2009 edition
3. Rizvi HM, Hossain MZ. Cephalometric norms of young adults of Bangladesh (Steiner's analysis)- APOS Trends in Orthodontics| January 2013|vol-3|issue 1

**CORRESPONDENCE:**

---

**Dr. Shamima Nargish, BDS**  
 FCPS-II Trainee  
 Dept. of Orthodontics and Dentofacial Orthopedic  
 Dhaka Dental College and Hospital  
 Mirpur-14, Dhaka-1206  
 Mobile: +8801720189717, E-mail: dr.ivey34@gmail.com