

Original Articles

Management of Postmenopausal Women with Simple Cyst

SK ZINNAT ARA NASREEN

Abstract:

Objective(s): Aim of the study was to explore the outcome of conservative treatment for the postmenopausal women having small cysts.

Materials Methods: This prospective cross sectional study was carried out in ZH Sikder Women Medical College & Hospital, Medinova and Popular hospital between January 2011 to June 2016. Five hundred (500) postmenopausal women with simple cysts were enrolled after counseling and taking written consent. Inclusion criteria were- cysts size should not be more than 5cm, they should be unilocular, without having any solid component or any debris. Exclusion criteria were, she or her family should not have any cancer of ovary, breast, or colon. Also women with HRT were excluded from the study. Thorough history taking, clinical examination, and some investigation like CA125, and TVS with colour Doppler was carried out for all women. CT Scan, MRI, and PET Scan were reserved for cases where colour Doppler ultrasonogram was suspicious. All the patients were followed up every 3 months for 3 to 5 years. Surgery was done if the patient developed any symptoms, or if there was any increment of sizes of cysts or there was any sonographic changes were evident. MRI1 (malignancy risk index) was calculated for each patient. Data were analyzed by SPSS where all calculation rate of less than 0.05 was considered significant.

Results: Among 500 cysts, 285 cysts resolved spontaneously, which is highly significant ($p < 0.05$), 165 cysts needed surgery and 50 cysts regressed very slowly and did not regress completely. Histopathology of surgical specimen revealed all were benign except 4 cysts, which became malignant or malignant potential.

Conclusion: Postmenopausal women with simple cysts not more than 5cm, which are unilocular, unilateral, without having any solid component and with normal Doppler study are rarely malignant. So if MRI 1 is below 200 we may avoid unnecessary surgery and assure the postmenopausal women for the conservative treatment with regular follow up.

Introduction:

Ovarian cysts in postmenopausal women are now known to be very common and maximum are not malignant. The exact prevalence is unknown given the limited amount of published data and the lack of established screening programs for ovarian cancer. However, studies have estimated the incidence to be anywhere between 5% and 17%¹⁻⁴ and 60-70% of unilocular cyst resolved spontaneously⁵⁻⁸. In Bangladesh we do not have exact data for the incidence but postmenopausal women with cysts are diagnosed as routine USG or in a woman who complains of slight discomfort in lower abdomen for

any reason. Ovarian cancer remains the leading cause of death due to gynecological malignancy in many countries. Owing to very high mortality and severe morbidities, any postmenopausal woman is scared even with simple cyst. Before the era of USG if pelvic examination revealed palpable ovaries, those ovaries were removed. Now USG is able to detect cysts far before it becomes palpable and most of them are benign. Many women honor the ovaries and not happy to remove it. On the other hand once cysts are found in post menopausal women many women get frightened and request for the removal of cysts. So the gynecologist often faces the real challenge to treat

such cysts. But the issue is whether surgery for the simple cysts in postmenopausal women is justified or not? Or is there any risk of conservative management of such cysts? So our study aims to see, how safe these cysts are and what is the natural history of these simple cysts in postmenopausal women, can we go for the conservative management without doing surgery?

Materials and methods:

This prospective cross sectional multi-centered study was conducted in ZH Sikder Women Medical College & Hospital (ZHSWMCH), Popular Hospital and Medinova Consultation Centre between January 2012 and January 2016. Five hundred post menopausal women with ovarian cysts aged 50-60 years were enrolled for this study. The cysts were apparently simple in nature by ultrasonogram, not more than 5cm, unilateral, unilocular with regular border, without any solid component, without any papilla, debris and with normal in color Doppler ultrasonogram. The women didn't have any previous history of malignancy or family history of ovarian cancer and they were not using any hormone. Thorough history was taken, medical history was taken from the women, with specific attention to risk factors and family history of bowel, breast and ovarian cancer. Clinical examination and laboratory investigations were carried out. Primarily transvaginal sonogram (TVS) with Doppler study and CA125 were done. MRI, CT scan and PET scan were reserved for the cases where ultrasonogram findings were suspicious. Risk of malignancy index (RMI) were assessed for all the cases. Though 4 types of RMI exists, RMI 1 is the most effective for women with suspected ovarian malignancy⁹.

Calculation of RMI-1

It is done by combining three pre-surgical features.

CA-125 (CA-125), Ultrasonogram score (U) and menopausal status (M)

$$RMI = U \times M \times CA-125$$

- Ultrasound score: It is done by assessing the following characteristics of the tumour—multilocular, solid areas, metastases, ascites and bilateral lesion. 1 point for each characteristic. U= 0 for an ultrasound score 0. U= 1 for an ultrasound score 1 and U=3 for an ultrasound score 2-5.
- Menopausal status: Score is 1 for premenopausal women and 3 for postmenopausal (Absence of menstruation for > 1year or age 50 years or more

who have hysterectomy) women.

- Serum CA -125: Score will be more when level will be higher. Measure in IU/ml and can vary between zero to thousands of units.

RMI 1 score 200 or more has 78% sensitivity and 87% specificity for detection of malignancy¹⁰⁻¹².

Women were re-evaluated at 3 months intervals for three years. The indication for surgery was based on patient's signs symptoms, patient's desire and suspicious sonographic changes of the cysts. During follow up detail history was taken and clinical examination was done. TVS and CA125 were done. CA125 is well established, being raised in over 80% of epithelial ovarian cancer cases, but not in most primary mucinous ovarian cancers. If a cut-off of 30 iu/ml is used, the test has a sensitivity of 81% and specificity of 75%. If RMI 1 was <200 other tumor markers such as human epididymis protein 4 (HE4), carcinoembryonic antigen (CEA), CDX2, cancer antigen 72-4(CA72-4), cancer antigen 19-9 (CA19-9) were not done.

During follow up when patient's cyst increased in size or RMI 1 index was suspicious or patient was anxious for not being resolved at follow up period or patient had complaints of pain and discomfort, the woman was selected for surgery. Surgery was done in the form of simple hysterectomy and bilateral salpingo-oophorectomy either laparoscopically or by abdominal route. All specimens were sent for histopathological tests.

Informed written consent was taken from all the cases. The analysis was performed using statistical package for social science (SPSS), data were presented as frequencies and in percentages. Z test was done for comparing percentage. A p value of < 0.05 was considered as significant.

Results:

A total 500 postmenopausal women with cysts were analyzed. Two hundred and eighty five (285) cysts resolved spontaneously completely and rapidly and 50 cysts were regressing very slowly and did not regress completely and remained as tiny cyst. Surgery was performed in 172 cases. Table 1 and Table 2 shown the fate and natural course of cysts. Most surgeries (70) were done in 1st year, 60 were done in 2nd year and 35 were done in last year. Indications and timing of surgery during follow up is shown in table 3. In most of the cases (53.33%) surgery were done due

to patient’s desire and 29.70% due to minor complaints of the patient. Only 16.77% cases it was done due to sonographic changes like increment of size, septation and presence of debris. Histopathology report of specimens of operated cysts showed 94 (56.97%) cases were simple cyst and 71 (40.03%) had neoplastic changes. Among them 67 (94.37%) were benign cysts and 4 (5.63%) had malignant changes (Table 3). But when it calculates among total cases neoplasia found in 14.2% cases, benign in 1.34% cases and malignancy in 0.8% cases. Among malignant- only one was frank cystadenocarcinoma, 2 were borderline serous cystadenoma and 1 was granulosa cell tumour (Table 4). Regarding benign tumours 46 were serous cystadenoma, 14 were mucinous cystadenoma and 7 were endometrioid cystadenoma. Fig 2. During follow up ultrasonogram 16 cysts showed increment of size, 9 became multiloculated and 3 had internal debris.

Table-I
Characteristics of cysts

| Characteristics | Mean±SD | Range |
|-----------------|------------|---------|
| Cysts size (cm) | 4.66±5.40 | 3.8—5.0 |
| RMI 1 | 85.66±9.74 | 60—99 |

Table-II
Natural fate of cysts

| Fate | Number | Percentages | P value |
|-------------------------------------|--------|-------------|---------|
| Complete resolution | 285 | 57% | <0.05 |
| Surgery needed for different causes | 165 | 33% | NS |
| Slowly regressing | 50 | 10% | NS |

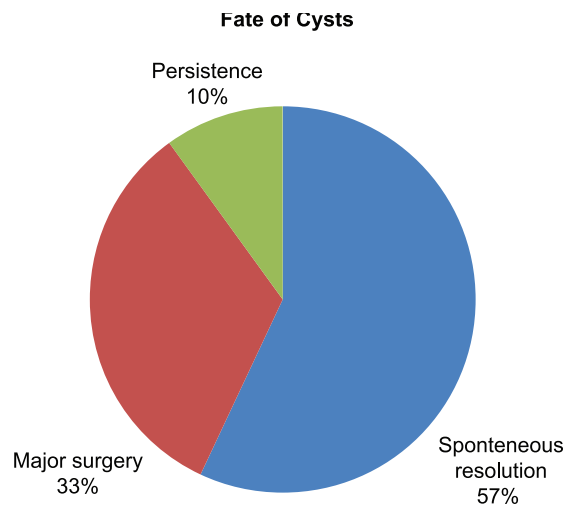


Fig.-1: Fate of cysts

Table-III
Natural course of cysts during the time period of the studies

| Fate of cyst | Total | 1 st year | 2 nd year | 3 rd year |
|--------------------------------------|-------|----------------------|----------------------|----------------------|
| Fast and complete resolution | 285 | 185 | 85 | 15 |
| Slowly regressing and persistent | 50 | 35 | 35 | 50 |
| Surgery done due to different causes | 165 | 70 | 60 | 35 |

Additional details for the 'Slowly regressing and persistent' row:
 1st year: Shown slight regression others not
 2nd year: Further reduction, others slightly reduced
 3rd year: Significant reduction but did not resolve completely.

Table-IV
Indications and time of surgery

| Surgery done | No. of patient (n=165) | | For patient's complaints | | Due to USG change | | For patients' request | |
|----------------------|---------------------------|-------|-----------------------------|-------|----------------------|-------|--------------------------|-------|
| | N | % | N | % | N | % | N | % |
| 1 st year | 70 | 42.42 | 24 | 48.97 | 13 | 46.43 | 33 | 37.50 |
| 2 nd year | 60 | 36.36 | 15 | 30.61 | 10 | 35.71 | 35 | 39.77 |
| 3 rd year | 35 | 21.21 | 10 | 20.41 | 5 | 17.86 | 20 | 22.73 |
| Total | 165 | 100 | 49 | 29.70 | 28 | 16.97 | 88 | 53.33 |

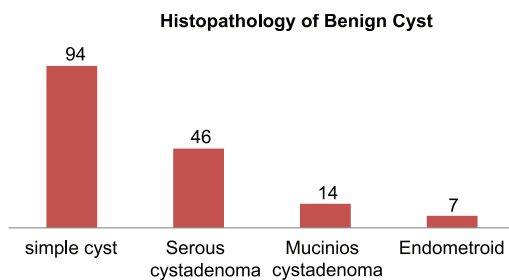


Fig.-2: Histopathology of benign cysts

Table-V
Histopathology of malignant cysts

| Types of malignancies | N | % |
|---------------------------|---|----|
| Serous cystadenocarcinoma | 1 | 25 |
| Borderline cystadenoma | 2 | 50 |
| Granulosa cell tumour | 1 | 25 |

Discussion:

Benign cysts are routinely produced by the ovaries during the menstrual cycle in women who are premenopausal and frequently by women who are menopausal. Ovarian cysts in post-menopausal women are usually benign functional cysts and known to be very common and most are not cancerous. In general, all post-menopausal women with ovarian cysts should be evaluated by pelvic sonography.

Numerous studies have looked at malignancy in ovarian cysts, comparing USG morphology with either histology at subsequent surgery or by close follow up of those women managed conservatively. We also followed the same ways. The tool of investigations we used TVS with Doppler study and serum CA-125 with cut off point of 30u/ml for all women. The test has sensitivity of 81% and specificity of 75%¹³. Efficacy

of USG is well established, achieving sensitivity of 89% and of specificity of 73%¹⁴. TVS is very effective method of imaging (A Recommendation). CT scan, MRI or PET should be reserved only for suspicious cases. The role of these imaging techniques in the diagnosis of ovarian cancer is yet to be established. One study indicates that MRI may be superior to CT scan and ultrasound scan, in diagnosing ovarian mass but there is no difference in its' ability to distinguish between benign and malignant diseases¹⁵. Another study found that TVS has greater sensitivity than CT or MRI in this regard¹⁶. CT scan is choice of option in suspicious cases. But in our low resource country we should be more careful about the choice of imaging modalities and TVS could be applied for routine cases. However, there are no current available tests, which are perfect and offering 100% specificity and sensitivity. We did Doppler study of the cysts for all the cases. The use of three-dimensional power Doppler may contribute to the differentiation between benign and malignant masses because it improves detection of central blood vessels in papillary projections or solid areas.

In our study we tried to show clearly that chance of malignancy of cysts that are less than 5cm, unilateral, unilocular, without solid parts is <1% (0.8%). Similar studies showed that chance of malignancy in such cysts are very low about < 1%¹⁷⁻²¹.

As the chance of malignancy is very low, it is reasonable to manage these cysts conservatively and it is not justified to do surgery for all postmenopausal women with simple cysts. The issue of duration of follow up of persistent cysts is not yet been recommended. Most studies were done for one year. We followed the subjects of our study for about three years, which is the longest among all the studies. Also we followed these cysts at interval of 3 months,

we found that 57 % of them disappeared spontaneously. A large study by Levin et al also had shown that more than 50% of these cysts resolved spontaneously within 3 months⁸. Though Royal College recommended and many studies had follow up program at 4 months interval, we wanted to be more vigilant and did follow up at 3 months interval. But patients of our study were happy to attend every 3 months and interestingly there was no drop out of subject from the study. Christine Conway et al meta-analyzed 76 articles and cited that no malignant condition was identified from those studies where the cysts were followed up, so simple cysts are common in postmenopausal women than previously thought and this can be managed conservatively²².

Our study showed 57% cysts had spontaneous resolution, 10% persisted without any significant changes and 33% underwent surgery. A 2-year follow-up study of asymptomatic postmenopausal women with simple cysts smaller than 5 cm shown that most of the cysts disappeared (53%), remain static (28%), enlarge (11%), decrease (3%) or fluctuate in size (6%). Evidence from larger screening studies found a higher rate of resolution of unilocular cysts at 70%, with only complex cysts having an increased risk of malignancy². Adnexal cysts 5 cm or smaller in postmenopausal women are rarely malignant⁵⁻⁸.

In our study we had 165 cases, who needed surgery. Twenty-eight (16.97%) cysts showed changes in sonography, which was suspicious, 88 (53.33%) women did not like to be observed anymore and opted for surgery and 49 (29.70%) women developed pain and increased pressure in lower abdomen. All women underwent total abdominal hysterectomy (TAH) with bilateral salpingo-oophorectomy (BLSO) either laparoscopically or by laparotomy. We did not adopt aspiration procedure before the surgery as, cytological examination of cyst fluid, is poor in determining malignancy^{23,24}. In addition there is risk of cyst rupture and, if the cyst is malignant, there is some evidence that cyst rupture during surgery has an unfavorable impact on disease free survival²⁵. So aspiration has no role in the management of asymptomatic ovarian cysts in postmenopausal women (RCOG 2016). Evidence level 4 recommended that laparoscopic management of ovarian cysts in postmenopausal women is suitable for conservative management, as during oophorectomy, with removal of the intact cyst in a bag, may prevent cyst rupture

into peritoneal cavity. But women who are at risk of malignancy, as calculated using malignancy risk index, (MRI 1 >200) needs laparotomy and full staging procedure must be done. An experienced surgeon should operate these cases. In our study all the women who went for surgery, they opted for total abdominal hysterectomy and bilateral salpingo-oophorectomy after the informed consent. In suspicious cases, the surgeries were done by the whole team dedicated for oncosurgery and only 4 out of 500 cyst of postmenopausal women became malignant or malignant potential. Therefore, our study showed clearly that simple cysts of menopausal women are almost benign. Simple small cysts may have conservative management. Levine reported that simple cysts <5cm can be treated conservatively with appropriate follow up⁸. So from now we may move forward with conservative management for cysts of menopausal women and say along with Y. Oyelese who cited from 36 articles and commented that traditional oophorectomy may be replaced by conservative approach in the management of postmenopausal women with simple cysts²⁶. We emphasized TVS as routine imaging modalities and CT scan was done if RMI was > 200²⁷. Similarly RCOG Guideline recommended TVS for routine use.

The findings of our study is supported by the most recent guide line of RCOG²⁸. According to recommendation of RCOG asymptomatic, simple, unilateral, unilocular ovarian cysts, less than 5 cm in diameter, have a low risk of malignancy. In the presence of normal serum CA125 levels, these cysts can be managed conservatively, with a repeat evaluation in 4–6 months¹⁸. It is reasonable to discharge these women from follow-up after 1 year if the cyst remains unchanged or reduces in size, with normal CA125, taking into consideration a woman's wishes and surgical fitness.

Conclusion:

Postmenopausal women with simple cysts, which are unilateral, unilocular, 5cm or less, without any solid component can be managed conservatively. RMI 1 for all of them need to be evaluated. If RMI 1 is below 200, we may avoid unnecessary surgery and can assure the women with optimum counseling. Also we believe that this study might contribute to a better understanding of the management of postmenopausal women with simple cysts and may improve the quality care of our postmenopausal women.

References:

1. Dørum A, Blom GP, Ekerhovd E, Granberg S. Prevalence and histologic diagnosis of adnexal cysts in postmenopausal women: an autopsy study. *Am J Obstet Gynecol* 2005;192: 48–54.
2. Greenlee RT, Kessel B, Williams CR, Riley TL, Ragard LR, Hartge P, et al. Prevalence, incidence, and natural history of simple ovarian cysts among women >55 years old in a large cancer screening trial. *Am J Obstet Gynecol* 2010;202: 373.e1–9.
3. Zalud I, Busse R, Kurjak BF. Asymptomatic simple ovarian cyst in postmenopausal women: syndrome of 'visible ovary'. *Donald School J Ultrasound Obstet Gynecol* 2013;7:182–6.
4. Healy DL, Bell R, Robertson DM, Jobling T, Oehler MK, Edwards A, et al. Ovarian status in healthy postmenopausal women. *Menopause* 2008;15:1109–14.
5. Levine D, Brown DL, Andreotti RF, Benacerraf B, Benson CB, Brewster WR, et al.; Society of Radiologists in Ultrasound. Management of asymptomatic ovarian and other adnexal cysts imaged at US: Society of Radiologists in Ultrasound consensus conference statement. *Ultrasound Q* 2010;26: 121–31.
6. Modesitt SC, Pavlik EJ, Ueland FR, DePriest PD, Kryscio RJ, van Nagell JR Jr. Risk of malignancy in unilocular ovarian cystic tumors less than 10 centimeters in diameter. *Obstet Gynecol* 2003;102:594–9.
7. Stany MP, Maxwell GL, Rose GS. Clinical decision making using ovarian cancer risk assessment. *AJR Am J Roentgenol* 2010;194:337–42.
8. Levine D, Gosink BB, Wolf SI, Feldesman MR, Pretorius DH. Simple adnexal cysts: the natural history in postmenopausal women. *Radiology* 1992;184:653–9.
9. Geomini P, Kruitwagen R, Bremer GL, Cnossen J, Mol BW. The accuracy of risk scores in predicting ovarian malignancy: a systematic review. *Obstet Gynecol* 2009;113:384–94.
10. Bourne TH, Cambell S, Reynolds KM, Whitehead MI, Hampson J, Royston P, et al. Screening for early familial ovarian cancer with trans vaginal ultrasonography and colour blood flow imaging. *BMJ* 1993;306:1025-9.
11. Morgante G, La marca A, Ditto A, De Leo V. Comparison of two malignancy risk indices based on serum CA125, ultrasound score and menopausal status in the diagnosis of ovarian masses. *Br J Obset Gynaecol* 1999;106:524-7.
12. Ma S, Shen K, Lang J. A risk of malignancy index in preoperative diagnosis of ovarian cancer. *Chin Med J (Engl)* 2003;116:396-9.
13. Jacobs I, Oram D, Fairbanks J, Turner J, Frost C, Grudzinskas JG. A risk of malignancy index incorporating CA125, ultrasound and menopausal status for the accurate preoperative diagnosis of ovarian cancer. *Br J Obstet Gynaecol* 1990;97:922–9.
14. DePriest PD, Varner E, Powell J, Fried A, Puls L, Higgins R, et al. The efficacy of a sonographic morphology index in identifying ovarian cancer: a multi-institutional investigation. *Gynecol Oncol* 1994;55:174–8.
15. Kurtz AB, Tsimikas JV, Tempany CM, Hamper UM, Arger PH, Bree RL. Diagnosis and staging of ovarian cancer: comparative values of Doppler and conventional US, CT, and MR imaging correlated with surgery and histopathologic analysis: report of the Radiology Diagnostic Oncology Group. *Radiology* 1999;212:19–27.
16. Grab D, Flock F, Stohr I, Nussle K, Rieber A, Fenchel S, et al. Classification of asymptomatic adnexal masses by ultrasound, magnetic resonance imaging, and positron emission tomography. *Gynecol Oncol* 2000;77:454–9.
17. Roman LD, Munderspach LI, Stein SM, Laifer-Narin S, Groshen S, Morrow CP. Pelvic examination, tumor marker level, and gray-scale and Doppler sonography in the prediction of pelvic cancer. *Obstet Gynecol* 1997;89:493–500.
18. Kurtz AB, Tsimikas JV, Tempany CM, Hamper UM, Arger PH, Bree RL. Diagnosis and staging of ovarian cancer: comparative values of Doppler and conventional US, CT, and MR imaging correlated with surgery and histopathologic analysis: report of the Radio logy Diagnostic Oncology Group. *Radiology* 1999;212:19–27.
19. Tingulstad S, Hagen B, Skjeldestad FE, Onsrud M, Kiserud T, Halvorsen T. Evaluation of a risk of

- malignancy index based on serum CA125, ultrasound findings and menopausal status in the pre-operative diagnosis of pelvic masses. *Br J Obstet Gynaecol* 1996;103:826–31.
20. Tingulstad S, Hagen B, Skjeldestad FE, Halvorsen T, Nustad K, Onsrud M. The risk-of-malignancy index to evaluate potential ovarian cancer in local hospitals. *Obstet Gynecol* 1999;93:448–52.
 21. Junor EJ, Hole DJ, McNulty L, Mason M, Young J. Specialist gynaecologists and survival outcome in ovarian cancer: a Scottish national study of 1866 patients. *Br J Obstet Gynaecol* 1999;106:1130–6.
 22. Chery Horlen. Simple cyst in Postmenopausal women, *Us Pharmacist* 2010;35(7) 1-4.
 23. Higgins RV, Matkins JF, Marroum MC. Comparison of fine-needle aspiration cytologic findings of ovarian cysts with ovarian histologic findings. *Am J Obstet Gynecol* 1999;180: 550–3.
 24. Moran O, Menczer J, Ben-Baruch G, Lipitz S, Goor E. Cytologic examination of ovarian cyst fluid for the distinction between benign and malignant tumors. *Obstet Gynecol* 1993;82: 444–6.
 25. Kindermann G, Maassen V, Kuhn W. Laparoscopic preliminary surgery of ovarian malignancies. Experiences from 127 German women gynecologic clinics. *Geburtshilfe Frauenheilkd* 1995;55:687–94.
 26. Y. Oyelese et al Asymptomatic postmenopausal simple ovarian cysts-NCBI *Obstet Gynecol Survey* -2002 ;57(12): 803-9.
 27. Solnik MJ, Alexander C. Ovarian incidentaloma. *Best Pract Res. Clin Endocrinol Metab* 2012;26:105–16.
 28. The Management of Ovarian Cysts in Postmenopausal Women. .Green-top Guideline No. 34 (RCOG). July 2016