

## Case Reports

# Malignant Mixed Mesodermal Tumour (MMMT) of the Ovary: An Unusual Primary Tumour

AKTER R<sup>1</sup>, TASNIM S<sup>2</sup>, NESSA K<sup>3</sup>, BANU SA<sup>4</sup>

### Abstract:

*Ovarian carcinosarcoma (Malignant Mixed Mesodermal Tumour) is rare malignant tumour with a poor prognosis. We here present a case of ovarian carcinosarcoma in a 72-years-woman suffering from intermittent lower abdominal pain for 5 months with previous history of Total Abdominal Hysterectomy (TAH) with Unilateral Salpingo-Oophorectomy (USO) due to leiomyoma 27 years back. Explanatory laparotomy and right salpingo-oophorectomy with complete surgical staging was done at Dhaka Community Medical College Hospital. Histopathology revealed both sarcomatous and carcinomatous component. Surprisingly the patient had no metastatic foci and consulted with a medical Oncologist, who didn't recommend any chemotherapy and was cancer free during last one and half years follow up.*

**Key words:** Ovarian Carcinosarcoma, Malignant Mixed Mesodermal Tumour, Surgery, Surveillance only.

### Introduction :

Ovarian carcinosarcoma is responsible for 1-4% of all ovarian tumours<sup>1</sup>. Carcinosarcoma is found not only in the ovary but also in other organs like uterus<sup>2</sup>, fallopian tube<sup>3</sup>, breast<sup>4</sup> and urethra<sup>5</sup>. The peculiarity of this malignancy is that the tumour is composed of both epithelial and mesenchymal malignant appearing cellular components. Malignant Mixed Mesodermal tumour, with rare exceptions, is a disease of elderly menopausal women, and there is an association with prior pelvic radiation.

### Case History:

A 72 years old woman presents with intermittent lower abdominal pain for 5 months. There was no history of altered bowel or bladder habit or bleeding per vagina or rectum. She gave history of total abdominal hysterectomy with left sided Unilateral Salpingo-Oophorectomy 27 years back, due to leiomyoma, but

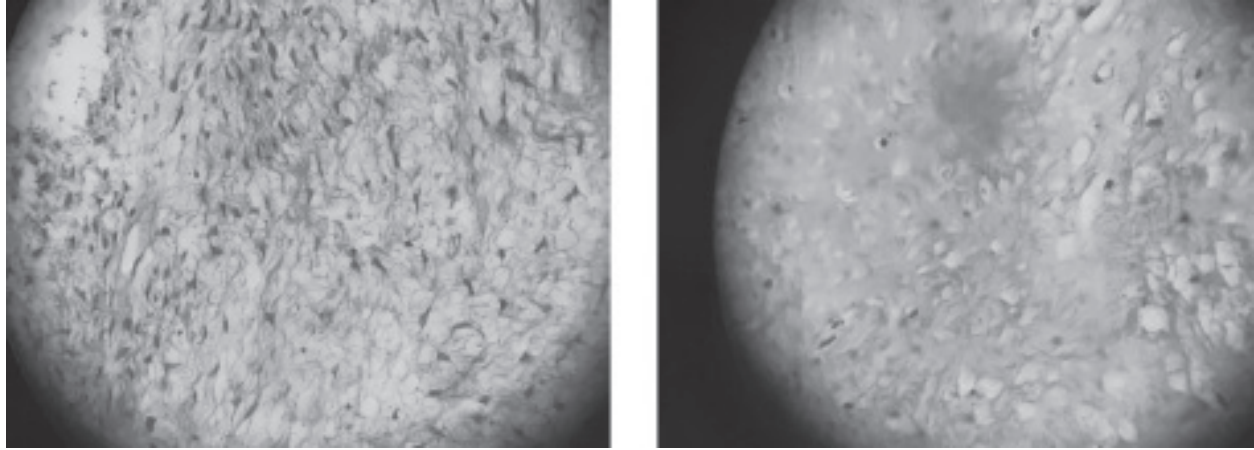
she couldn't show any document. She had also laparoscopic cholecystectomy 2 years back. Her routine hematological and biochemical parameters were normal.

Her serum CA-125 was 80 IU/ ml (normal -0-35). USG shows a large complex cyst of about 10 x 9.7cm having cystic and solid components with internal septation seen in the adnexal region. Right ovary is not well visualized. There was left sided hydronephrosis and IVU shows delayed or non excreting left kidney but serum creatinine level was normal.

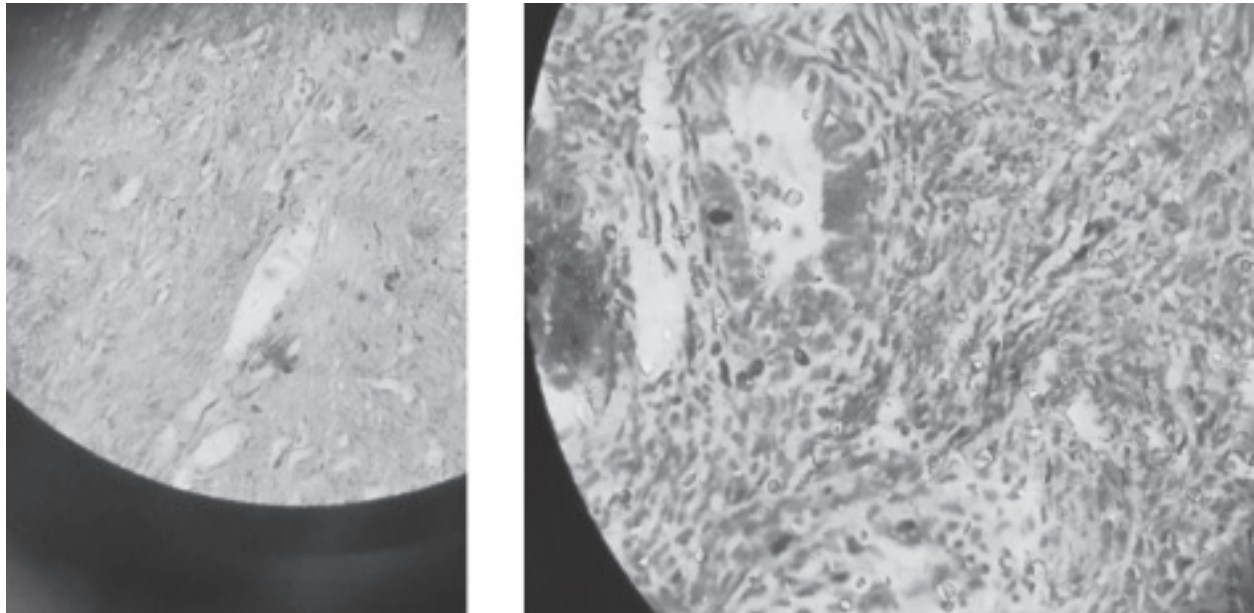
During laparotomy a gross cyst with intact capsule, no engorged vessels, no adhesion and no ascitic fluid was found. It was 9cm in maximum diameter and wall thickness 1.5cm. The inner surface was irregular with multiple polypoid projections. Laparotomy followed by right sided salpingoovariotomy and

1. Dr. Razia Akter, Assistant Professor, Department of Obstetrics and Gynecology, Dhaka Community Medical College and Hospital, Moghbazar, Dhaka.
2. Prof. Dr. Saria Tasnim, Professor and Head of Department of Obstetrics and Gynecology, Dhaka Community Medical College and Hospital.
3. Dr. Kamrun Nessa, Professor and Head of Department of Obstetrics and Gynecology, BRB Hospitals, Dhaka.
4. Dr. Selina Akter Banu, Associate Professor, Department of Obstetrics and Gynecology, Dhaka Community Medical College and Hospital, Dhaka

**Address of Correspondence:** Dr. Razia Akter, Assistant Professor, Department of Obstetrics and Gynecology, Dhaka Community Medical College and Hospital, Moghbazar, Dhaka. Email : razia.akter@hotmail.com



**Fig.-1:** Sarcomatous Component of MMMT Ovary



**Fig.-2:** Carcinomatous component of MMMT Ovary

complete surgical staging was done. Final stage was stage 1A. Microscopic examination of the tumour reveals a malignant mixed mesodermal tumour. It contains malignant heterogenous elements –the sarcomatous component having the appearance of chondrosarcoma and carcinomatous component having the appearance of serous cystadenocarcinoma. Irregular areas of necrosis was present. As stage 1A, she did not receive any chemotherapy. She had regular follow up and after 1 year of follow up by CA- 125, it was normal and other tumour markers like CA 19-9, Alpha- fetoprotein and Carcinoembryonic antigen (CEA) was found in normal ranges and she had no complain. USG and

CT scan reports were also normal at one and half years follow up.

#### **Discussion:**

MMMT a rare tumour affecting the elderly nulliparous population with a poor prognosis<sup>6,7</sup>. The tumour is highly aggressive. There are many theories regarding their histogenesis. The collision theory suggest that carcinoma and sarcoma are two independent tumours. The combination theory says that both components are derived from single stem cells which undergo divergent differentiation. The conversion theory suggests that a sarcomatous element is obtained from the carcinoma during the evolution of

tumours<sup>8</sup>. Another view is that the spindle cell component is just a pseudo-sarcomatous stromal reaction to an invasive carcinoma. Out of these, combination and conversion theories are proved to be the prime modes of histogenesis<sup>8</sup>. The malignant mesenchymal component can be homologous or heterologous. If the sarcomatous part contains elements resembling the Mullerian duct system (Fibrosarcoma, leiomyosarcoma, endometrial stromal sarcoma) –it is termed homologous. If the tumour has elements not normally found in the ovary (eg bone, skeletal muscle) it is called heterologous<sup>7,8</sup>.

Malignant mixed mesodermal sarcomas of the ovary are usually heterologous and 80% occur in post-menopausal women. The lesions are biologically aggressive and their presentation is similar to that of most epithelial ovarian malignancies. Such patients should be treated by cytoreductive surgery and post-operative platinum containing combination chemotherapy.

The metastatic foci usually shows a carcinomatous component. Pure sarcomatous elements in metastatic foci are rare<sup>8</sup>. Our case showed a pure sarcomatous component without metastasis. Some researchers have speculated that sarcomatous differentiation in metastatic lesion is dependent on anatomical sites. There is no well established consensus regarding the treatment regime. It is usually directed against carcinomatous component rather than the sarcomatous component<sup>8</sup>. Different chemotherapy regimens are used (The standard chemotherapy regimen is the use of a platinum-based agent and taxane, such as intravenous Carboplatin 5AUC or 6AUC/Cisplatin/Oxaliplatin alone or in combination with Paclitaxel 175 mg/m<sup>2</sup> for three to nine cycles q3w). The response of Platinum base chemotherapy is 25%. The role of therapeutic radiotherapy is not established. Our patient had no metastatic foci and didn't receive any

chemotherapy and was cancer free on one and half years follow up.

#### References:

1. Del Carmen MG, Birrer M, Schorge JO. Carcinosarcoma of the ovary: a review of the literature. *Gynecol Oncol.* 2012;125:271–277
2. Spaziani E, Picchio M, Petrozza V, Briganti M, Ceci F, Di Filippo A, et al. Carcinosarcoma of the uterus: a case report and review of the literature. *Eur J Gynaecol Oncol.* 2008;29:531–534.
3. Lavie O, Longacre T, Segev Y, Husain A. Ovarian carcinosarcomas associated with prolonged use of tamoxifen: case reports. *Int J Gynecol Cancer.* 2009;19:1521–1523.
4. Tampaki EC, Tampakis A, Agrogiannis G, Kavantzias N, Kontzoglou K, Kouraklis G. A case of positive mixed epithelial/mesenchymal metaplastic breast carcinoma (carcinosarcoma). Towards novel therapeutic targets: case report. *Onkologie.* 2013;36:506–509.
5. Jayamohan Y, Urs L, Rowland RG, Woolums S, Lele SM. Periurethral carcinosarcoma: a report of 2 cases with a review of the literature. *Arch Pathol Lab Med.* 2005;129:E91–E93.
6. Brown E, Stewart M, Rye T, et al. Carcinosarcoma of the ovary: 19 years of prospective data from a single center. *Cancer.* 2004;100(10):2148–2153.
7. Harris MA, Delap LM, Sengupta PS, et al. Carcinosarcoma of the ovary. *Br J Cancer.* 2003;88(5):654–657.
8. McCluggage WG. Malignant biphasic uterine tumors: carcinosarcomas or metaplastic carcinomas? *J Clin Pathol.* 2002;55(5):321–325.