

## Review Article

# Nerve injuries associated with Gynecological Surgery: Review Article

JESMIN AKTER, ANZUMAN ARA BEGUM

### Key content

- Nerve injuries are a common complication of gynecological surgery, occurring in 1.1-1.9% of cases.
- Patient mal-positioning, incorrect placement of self-retaining retractors, hematoma formation and direct nerve entrapment or transection are the primary causative factors in preoperative and peroperative nerve injury.
- Nerves most commonly injured during gynaecological surgery include the femoral, ilioinguinal, pudendal, obturator, lateral cutaneous, iliohypogastric and genitofemoral nerves.
- The majority of neuropathies resolve with conservative management and physiotherapy.
- Selective serotonin reuptake inhibitors (SSRIs), tricyclic antidepressants and gamma-aminobutyric acid (GABA) antagonists are of significant benefit in managing painful neuropathies due to nerve injuries.

### Learning objectives

- To gain an overview of the spectrum of different neuropathies that may occur following pelvic surgery.
- To learn about safe surgical techniques in the prevention of postoperative neuropathies.
- To review the clinical anatomy of the lumbo-sacral and brachial plexuses.

### Ethical issues

- Neuropathies can cause considerable postoperative morbidity.
- Should neuropathies following gynecological surgery be discussed routinely during consent taking?

- Neuropathies following surgery may have considerable medico-legal implications.

**Keywords:** Gynecological surgery, Nerve injury, Neuropathy.

### Introduction:

Iatrogenic nerve injury following gynaecological surgery occurs more commonly than is recognised and is a significant cause of postoperative neuropathy. Patient mal-positioning, improper incision sites and self-retaining retractors are major contributors to the origins of intraoperative gynaecological nerve injury.

The incidence of neuropathy following gynecological surgery is between 1.1 and 1.9%<sup>1,2,3</sup>. Most cases will have a good prognosis, with minimal or no intervention necessary for resolution of the neurological impairment. Long-term complications requiring extended care or even repair surgery are needed by a minority of patients.

In this article the authors outline the anatomy of the susceptible nerves, describe the common mechanisms of injury and discuss the management of such injuries. The preventive strategies to reduce neuropathies and the medico-legal ramifications are also discussed. Sympathetic and parasympathetic nerve injuries of the bladder and bowel are beyond the scope of this article.

### Pathophysiology of nerve injury:

Neuropathy results when there is a disruption to the blood supply of the nerve caused by injury. Three types of microvascular changes occur with nerve injury (Table 1). Neuropraxia is the result of external nerve compression leading to a disruption of conduction across a small portion of the axon. Nerve

1. Assistant Professor, Obstetrics and Gynaecology Department, Cumilla Medical College, Cumilla

2. Assistant Professor, Obstetrics and Gynaecology Department, Abdul Malek Ukil Medical College, Noakhali

**Address of Correspondence:** Dr. Mst. Jesmin Akter, Assistant Professor, Obstetrics and Gynaecology Department, Cumilla Medical College, Cumilla, E-mail: Jesmin5544@gmail.com, Phone: 01816766132

**Table-I**  
*Pathophysiology of nerve injury*

Type of nerve injury	Pathophysiology	Prognosis
<b>Neuropraxia</b>	External nerve compression	Recovery within weeks to months
<b>Axonotmesis</b>	Severe compression with axon damage	Recovery takes longer usually several months
<b>Neurotmesis</b>	Nerve transection with damage to Schwann cells	Poor prognosis without restorative surgery.

recovery takes weeks or months once remyelination occurs.

Axonotmesis is caused by profound nerve compression or traction. Damage occurs to the axon only, with preservation of the supporting Schwann cells. Regeneration is possible because supporting Schwann cells remain intact. Recovery time is longer than neuropraxia.

The most severe form of injury is termed neurotmesis, and it results from complete nerve transection or ligation, where both the axon and Schwann cells are disrupted. Regeneration is rendered impossible and without restorative surgery, prognosis is usually poor<sup>2,4</sup>.

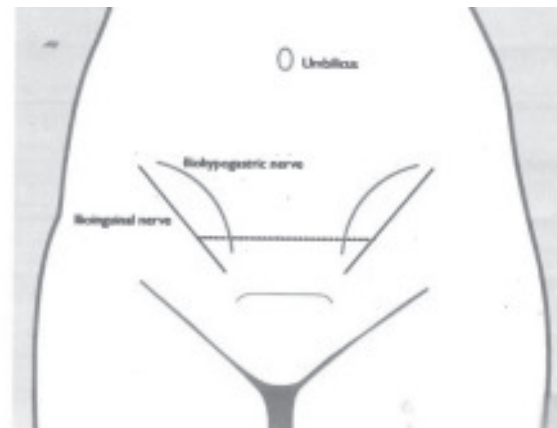
#### **Mechanism of nerve injury:**

The mechanism of intraoperative nerve injury involves a combination of compression, stretch, entrapment or transection of nerve fibers. Compression and stretch injuries are typically caused by improper placement of self-retaining retractors such as the Balfour or Brookwaller retractors<sup>5,6</sup> and in prolonged positioning of the patient in stirrup.

Transection injuries are largely related to incorrectly sited surgical incisions. The Pfannenstiel and low transverse incisions are the most common incisions performed in gynaecology. Should these incisions extend beyond the lateral margin of the inferior rectus abdominus muscle, the lateral cutaneous branches of the iliohypogastric and ilioinguinal nerves are liable to be injured (Figure 1). A cadaver study found that abdominal wall incisions below the level of the anterior superior iliac spine and approximately 5 cm superior to the pubic symphysis had the greatest potential for injuring the ilioinguinal or iliohypogastric nerves<sup>7</sup>.

Entrapment nerve injuries are more commonly encountered in pelvic floor reconstructive surgery. Pain is a common symptom of nerve entrapment in

contrast to loss of function and numbness that occurs with nerve transection.



**Fig.-1:** Ilioinguinal and iliohypogastric nerves in relation to lower transverse abdominal incision.

A recent study showed that chronic nerve-related pain was seen in 7% of women following Pfannenstiel incisions and this was attributed to entrapment of the ilioinguinal and iliohypogastric nerves<sup>8</sup>

Although rare, another source of preoperative lumbosacral nerve injury to consider is related to complications of regional anaesthesia. During epidural or spinal neuraxial blockade, poor technique may cause paraesthesia and pain as a result of needle or catheter tip trauma to nerve roots and the spinal cord. Pain may also result from injection of anesthetic into the wrong spinal compartment. Most often, neurological damage secondary to regional anaesthesia administration is immediately apparent as the patient becomes symptomatic during the procedure<sup>9,10</sup>.

#### **Specific nerve anatomy and related neuropathies**

The nerves most commonly injured during pelvic surgery originate from the lumbosacral and brachial plexus (Figures 2 and 3)

Table II provides a summary of the nerve components of the lumbosacral plexus, their function and clinical presentation after injury.

**Table-II**  
*Summary of lumbosacral plexus*

Nerve	Origin	Sensory function	Motor function	Clinical presentation
<b>Femoral</b>	L2-L4	Anterior/medial thigh, medial aspect of cuff	Hip flexion/adduction, knee extension.	Unable to climb stairs.
<b>Obturator</b>	L2-L4	Upper medial thigh	Thigh adduction	Minor ambulatory or walking problem
<b>Sciatic -Common peroneal -Tibial</b>	L4-S3	Below knee except medial foot, lateral cuff, dorsum of foot, toes, planter surface of foot	Hip extension/knee flexion, dorsiflexion, eversion of foot, planter flexion, inversion of foot.	Sciatica, foot drop, cavus deformity of foot.
<b>Iliohypogastric</b>	T12-L1	Mons pubis, lateral labia, upper inner thigh	None	Sharp burning pain radiating to incision site to mons, labia, thigh
<b>Ilioinguinal</b>	T12-L1	Groin, symphysis,	None	Same as above but to groin, symphysis pubis
<b>Pudendal</b>	S2-S3	Perineum	None	Perineal pain
<b>Lateral cutaneous nerve</b>	L2-L3	Anterior/posterior-lateral thigh	None	Pain/paraesthesia anterior/posterolateral thigh
<b>Genito-femoral</b>	L1-L2	Labia, femoral triangle	None	Pain/paraesthesia labia, femoral triangle

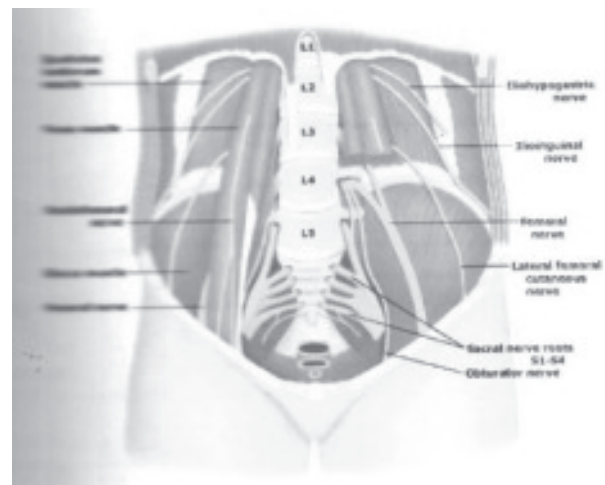
Lumbosacral plexus : Nerve injury associated with pelvic surgery. In: UpToDate, Basow DS (Ed), UpToDate, Waltham, MA 2013. Copyright  
<sup>a</sup> UpToDate, Inc. For more information visit [www.uptodate.com](http://www.uptodate.com)

### Femoral nerve:

The femoral nerve originates from nerve roots L2—L4. It passes infero-laterally through the psoas muscle and emerges from its lateral border. It exits the pelvis beneath the inguinal ligament, lateral to the femoral vessels to enter the thigh.

Gynaecological surgery is the most common contributor to iatrogenic femoral nerve injury, and abdominal hysterectomy is mostly responsible for this<sup>11</sup>. Of all reports of gynaecological associated neuropathy, the femoral nerve is most frequently implicated, with an incidence of at least 11%<sup>12</sup>.

Femoral neuropathy commonly occurs as a result of compression of the nerve against the pelvic sidewall as it emerges from the lateral border of the psoas muscle. This happens when excessively deep retractor blades are used or during the lateral placement of retractors. In a 10-year prospective study, Goldman et al<sup>13</sup> reported an 8% incidence of femoral neuropathy when self-retaining retractors were used during gynaecological surgery, compared to an incidence of <1% when not used.<sup>14</sup>



**Fig.-2: Lumbosacral plexus.**

Inappropriate patient positioning in lithotomy is also another cause of stretch-related femoral neuropathy. Hyper-flexion, abduction and external rotation of the hip results in kinking of the femoral nerve under the inguinal ligament<sup>13</sup>.

Femoral neuropathy presents with weakness of hip flexion and adduction and knee extension. There is

loss of the knee jerk reflex and paraesthesia over the anterior and medial thigh, as well as the medial aspect of the calf.

### **Ilioinguinal and iliohypogastric nerves**

The T12-L1 nerve root gives rise to the ilioinguinal and iliohypogastric nerves. Both nerves pass laterally through the head of the psoas muscle before running diagonally along quadratus lumborum. The iliohypogastric nerve pierces the external oblique aponeurosis above the superficial inguinal ring, while the ilioinguinal nerve emerges through it.

Both nerves have a sensory function only. While the iliohypogastric provides sensation to the skin of the gluteal and hypogastric regions, the ilioinguinal nerve provides sensory innervation to the skin overlying the groin, inner thigh and labia majora.

Injury to these nerves is typically caused by suture entrapment at the lateral borders of low transverse or Pfannenstiel incisions that extend beyond the lateral border of the rectus abdominus muscle. The reported incidence of ilioinguinal or iliohypogastric neuropathy following a Pfannenstiel incision is 3.7%<sup>15</sup>. Laparoscopic aid retropubic mid urethral tape procedures may also injure this nerve<sup>16</sup>.

The diagnostic triad for ilioinguinal/iliohypogastric nerve entrapment syndrome consists of:

1. Sharp burning pain radiating from the incision site to the mons pubis, labia and thigh,
2. Paresthesia over the nerve distribution areas,
3. Pain relief following administration of local anesthetic.

### **Genitofemoral nerve:**

The genitofemoral nerve (L1—L2) transverses the anterior surface of psoas, and lies immediately lateral to the external iliac vessels. It divides into a genital branch, which enters the deep inguinal ring, and a femoral branch, which passes deep to the inguinal ligament within the femoral sheath.

This nerve is susceptible to injury during pelvic sidewall surgery and during removal of the external iliac nodes. Genitofemoral nerve injury results in paraesthesia over the mons pubis, labia majora and femoral triangle. Injury to this nerve results in lack of sensation during sexual activity.

### **Lateral cutaneous nerve:**

The lateral cutaneous nerve of the thigh (L2-L3) also emerges from the lateral border of psoas. It crosses, the iliac fossa anterior to the iliacus muscle and enters the thigh posterior to the lateral end of the inguinal ligament.

The mechanism of injury during pelvic surgery to this nerve is similar to that of the femoral nerve. Symptoms produced by injury include paraesthesia, pain and numbness in the anterior and posterolateral aspect of thigh which is referred to as meralgia paraesthesia.

### **Obturator nerve:**

The anterior branches of L2-L4 give rise to the obturator nerve and converge behind the psoas muscle. The obturator nerve then passes over the pelvic brim in front of the sacroiliac joint and behind the common iliac vessels to enter the thigh via the obturator foramen.

This nerve is most frequently injured during retroperitoneal surgery, excision of endometriosis, the passage of a trocar through the obturator foramen, insertion of trans obturator tapes and during paravaginal defect repairs.

Obturator neuropathy will present with sensory loss in the upper medial thigh and motor weakness in the hip adductors.

### **Sciatic and common peroneal nerve:**

The sciatic nerve arises from the L4—S3 nerve roots. It emerges from the pelvis below the piriformis muscle, curving laterally and downward through the gluteal region. Initially it lies midway between the posterior superior iliac spine and ischial tuberosity. Lower down in the thigh it courses midway between the ischial tuberosity and greater trochanter.

The common peroneal nerve and tibial nerve are its two derivatives at the mid-thigh. The common peroneal nerve importantly winds forward around the neck of the fibula.

The sciatic and peroneal nerves are commonly injured at the sciatic notch and the lateral aspect of the fibular neck, respectively. Both nerves are susceptible to stretch injuries from hyperflexion of the thighs in improper lithotomy positions. Furthermore, the common peroneal nerve may be compressed at the fibular neck in lithotomy position.

Sciatic nerve injury presents as sensory impairment below the knee and weakness of hip extension and knee flexion. Foot drop is reported when the common peroneal nerve is injured, along with paraesthesia over the calf and dorsum of the foot.

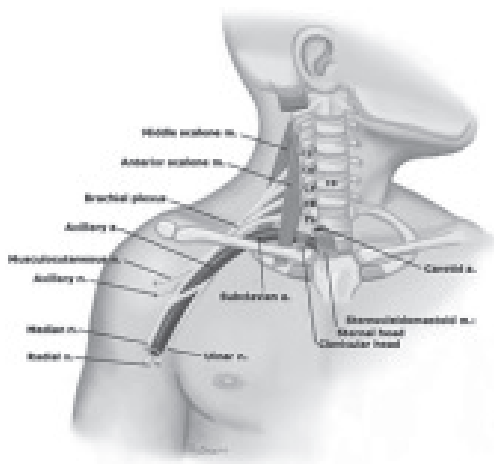
#### **Pudendal nerve:**

The pudendal nerve (S2-S4) exits the pelvis initially through the greater sciatic foramen below the piriformis. Importantly, it runs behind the lateral third of the sacrospinous ligament and ischial spine alongside the internal pudendal artery and immediately re-enters the pelvis through the lesser sciatic foramen to the pudendal canal (Alcock's canal).

This nerve is susceptible to entrapment injuries during sacrospinous ligament fixation as it runs behind the lateral aspect of the sacrospinous ligament.

The patient will report postoperative gluteal, perineal and vulval pain, which worsens in the seated position if the nerve is damaged<sup>17</sup>.

The disruption of neurological pathways secondary to gynaecological surgery has been postulated as an etiological factor for female sexual dysfunction<sup>18</sup>. Some studies found that sexual dysfunction was evident postoperatively following disruption of the pudendal nerve sensory pathway<sup>19</sup>. However, evidence for this conclusion is quite limited, as only a handful of clinical studies to date have investigated neurologic sensory deficits as a cause of sexual dysfunction.



**Fig.-3: Brachial plexus**

Reproduced with permission from Gray JE. Nerve injury associated with pelvic surgery. In: UpToDate, Basow DS (Ed), UpToDate, Waltham, MA 2013. Copyright © UpToDate, Inc. For more information visit [www.uptodate.com](http://www.uptodate.com).

#### **The brachial plexus**

The brachial plexus originates from nerve roots C5-T1. It supplies the upper limb and lies within the posterior triangle of the neck (Figure 3).

The radial nerve leaves the posterior compartment of the arm by winding around a spiral groove on the back of the humerus. Pressure on the humerus during arm positioning can result in sensory loss in the lateral three and half fingertips and paralysis of the wrist and finger extensors.

The ulnar nerve arises from the medial cord and enters the forearm posterior to the medial epicondyle of the humerus. Undue pressure placed on the medial aspect of the elbow during arm board positioning can compress the ulnar nerve as it winds around the medial epicondyle. This results in sensory loss in the tips of the medial *one and half* finger and a “claw hand” from paralysis of the small muscles of the hand.

Stretch injuries are the most common mechanism of injury to the brachial plexus.<sup>14</sup> Hyper-abduction of the arm may result in a lesion of the upper nerve roots of the brachial plexus, involving nerves (C5—C6). This typically occurs where arm boards are extended beyond 90 degrees from the long axis of the operating table or when the arm unknowingly fall from the arm board during a procedure. As a result, the arm hangs by the side, and is medially rotated and pronated. This is known as Erb's palsy or “waiter tip” deformity.

Brachial plexus injuries have also been reported when shoulder braces are used to provide patient support in the steep Trendelenburg position during laparoscopic surgery. The lower brachial plexus nerve roots (C8-T1) are stretched if the brace is positioned too laterally. This result in a Klumpke's palsy, with loss of the function of the small muscles of the hand.

#### **Treatment of nerve injuries:**

Diagnosis of neuropathies presenting postoperatively require a careful history and examination to identify the extent and probable mechanism of nerve injury. Too often patients of neuropathic complaints are dismissed in the setting of residual anaesthesia, incision pain and postoperative analgesia, especially during the acute postoperative period. It is also important to distinguish iatrogenic nerve injury from other postoperative neurological complaints such as musculoskeletal injury and autoimmune or inflammatory conditions.



Fortunately, most neuropathies will resolve spontaneously, with minimal intervention. Sensory neuropathies typically resolve within 5 days, whereas motor deficits may take up to 10 weeks to recover. Occasionally neuropathies persist beyond 1 year.

Detailed neurological examination and electromyographic (EMG) studies are key to diagnosing a neurologic deficit. Once a neuropathy has been identified, the patient should be referred to a neurologist. EMG is useful in identifying and localising acute nerve injury by measuring sensory and motor nerve conduction velocity. With intraoperative nerve injuries, EMG should be performed 3-4 weeks from the point of suspicion of nerve damage, as denervation of the affected muscle is often delayed.

Acute management of neuropathies should be dictated by the symptoms presented. Painful neuropathies often respond to pharmacological agents known to be effective in the treatment of neurogenic pain, such as, tricyclic anti-depressants and gamma-aminobutyric acid (GABA) antagonists. Painful neuropathies rarely fail to resolve after 6 months. In such cases, local nerve blockade or even surgical nerve excision or decompression can be considered.

Motor impairment from retraction or stretch-related nerve injuries during improper patient positioning should be managed by physiotherapy, so as to maintain flexibility and range of movement. Active use of the muscles afflicted is generally recommended, although splinting may be protective against further injury.

Nerve lesions that do not heal are often the result of complete nerve transection. These nerves may be amenable to specialist repair using microsurgical techniques, such as tension-free end-to-end anastomosis. The aim is to regain alignment of the epineural sheath and neural fascicles. Repair of a transected obturator nerve has been shown to have an excellent prognosis with complete motor recovery after physiotherapy<sup>14</sup>.

#### **Prevention of nerve injuries:**

A thorough and complete understanding of the anatomy of the lumbosacral and brachial nerve plexuses by the surgeon is absolutely integral to minimising the risk of nerve injury during gynaecological operations. Also crucial in preventing

nerve injury is the preoperative identification of patients who are more prone to neurological complications. Studies have shown that patients who have a thin body habitus, ill-developed abdominal wall muscles or a narrow pelvis are more at risk of retractor blade associated nerve injury<sup>14</sup>. Such patients are at further risk if the operating time exceeds 4 hours.

A large number of iatrogenic lumbosacral nerve injuries during gynaecological surgery can be attributed to the incorrect positioning of self-retaining retractor blades. The gold standard of correct positioning is for the self-retractor blades to cradle the rectus muscle without compressing the psoas muscle underneath.

When positioning the retractors, the surgeon must check visually and by direct palpation that the psoas muscle is not entrapped between the blades and the pelvic side wall. Furthermore, the shallowest retractor blade sufficient to providing adequate exposure should be chosen, as it has been suggested that the degree of nerve injury is proportional to blade length. Rolled up laparotomy pads may be used to cushion the retractor blades against the pelvic side wall as a precaution. Retractor blade position should be monitored intermittently during the operation and re-adjusted accordingly.

It is recommended that undoing the retractors and re-positioning at regular intervals to relieve blade pressure against the pelvic side wall if a lengthy operation is being undertaken. As hand-held retractors will only exert intermittent as opposed to continual pressure on retracted tissue, they should be selected over self-retaining ones wherever possible.<sup>14</sup>

Particular attention must be paid to the correct preoperative positioning of the patient in lithotomy stirrups. The proper lithotomy position dictates that the hip and knee are only moderately flexed. At the hip, there should be minimal abduction and external rotation. The stirrups or boots should be at equal height. Excessive movement around the hip joint results in stretch and/or compression of the sciatic and femoral nerves.

Common peroneal nerve injury is avoided when there is padding in place between the lateral fibular heads and the stirrup, thus preventing nerve compression against a hard surface. As with abdominal surgery,

the length of operative time during lithotomy has been cited as a significant risk factor for increasing the risk of nerve injury, especially if operating time exceeds 2 hours.

A surgeon should avoid extending his incision beyond the lateral margins of the rectus muscles, where the ilioinguinal and iliohypogastric nerves lie. If wide margins are necessary, upward curving incisions should be made to avoid the path of the underlying nerves. During fascial closing of low abdominal incisions, care must be taken to incorporate tissue

Shoulder braces, if used during steep Trendelenburg, should be positioned over the acromio-clavicular joint, thus preventing brachial plexus injury. During surgery, the upper arm must be pronated and padding should be adequately draped over the postero-medial elbow to prevent ulnar nerve compression against the operating table.

Arm boards should be placed at an angle no further upwards than 90 degrees to avoid hyper-abduction nerve injury.

#### Medico-legal comment:

Inadvertent nerve injury can lead to litigation, with important financial implications for the NHS. Nerve damage was the fourth most common injury treatment in New Zealand between 2005 and 2010 and accounted for 4.3% of all injury claims. An observational cohort study by Moore et al. showed that orthopedic surgery was the most common specialty associated with nerve damage, while obstetrics and gynaecology were ranked 7<sup>th</sup> and 9<sup>th</sup> place respectively. Mal-positioning of the patient under general anaesthesia appeared to be the most important cause of nerve injury<sup>20</sup>.

#### Conclusion:

Postoperative neuropathy following gynaecological surgery is a significant cause of morbidity. The mechanism of intraoperative nerve injury involves a combination of compression, stretch, entrapment or nerve transection. Nerves most commonly subjected to intraoperative injury include nerves of the lumbosacral and brachial plexuses.

Incorrect placement of self-retaining retractors, patient mal-positioning and improper surgical incisions are major contributors to intraoperative nerve injury. Most cases are self-limiting, and symptoms resolve with several weeks. However, we

believe that a thorough understanding of the pelvic anatomy and proper placement of self-retaining retractors can prevent most nerve injuries that are related to gynecology surgery.

#### References :

1. Hoffman MS, Roberts WS, Cavanagh D. Neuropathies associated with radical pelvic surgery for gynecologic cancer. *Gynecol Oncol* 1988;31:46;6.
2. Cardosi RJ, Cox CS, Hoffman MS. Postoperative neuropathies after major pelvic surgery. *Obstet Gynecol* 2002;100:240-4.
3. Bohrer JC, Walters MD, Park A, Polston D, Barber MD. Pelvic nerve injury following gynecologic surgery: a prospective cohort study. *Am J Obstet Gynecol* 2009;201:1-7.
4. Bradshaw AD, Advincula AP. Postoperative neuropathy in gynecologic surgery. *Obstet Gynecol Clin North Am* 2010;37:451-9.
5. McDaniel GC, Kirkley WH, Gilbert JC. Femoral nerve injury associated with the Pfannenstiel incision and abdominal retractors. *Am J Obstet Gynecol* 1963;87:381-5.
6. Brasch RC, Bufo AJ, Kreienberg PF, Johnson GP. Femoral neuropathy secondary to the use of a self-retaining retractor. Report of three cases and a review of the literature. *Dis Colon Rectum* 1995;38:1115-8.
7. Whiteside JL, Barber MO, Walters MD, Falcone T. Anatomy of ilioinguinal and iliohypogastric nerves in relation to trocar placement and low transverse incisions. *Am J Obstet Gynecol* 2003;189:1574-8.
8. Loos MJ, Scheltinga MR, Mulders LG, Roumen RM. The Pfannenstiel incision as a source of chronic pain. *Obstet Gynecol* 2008;111:839-46.
9. Auroy Y, Narchi P, Messiaen A, Litt L, Rouvier B, Samii K. Serious complications related to regional anesthesia: results of a prospective survey in France. *Anesthesiology* 1997;87:479-86.
10. Horlocker TT, Wcde DJ. Neurologic complications of spinal and epidural anesthesia. *Reg Anesth Pain Med* 2000;25:83-98.
11. Fardin P, Benetello P, Negrin P. Iatrogenic femoral neuropathy. Considerations on its

- prognosis, flecfromyogr *Clin Neurophysiol* 1980;20:153-5,
12. Chan JK, Marietta A. Prevention of femoral nerve injuries in gynecologic surgery. *Am J Obstet Gynecol*. 2002;186:1-7.
  13. Goldman JA, Feldberg D, Dicker D, Samuel N, Dekel A. Femoral neuropathy subsequent to abdominal hysterectomy. A comparative study. *Eur J Obstet Gynecol Reprod Biol* 1985;20:385-92.
  14. Irvin W, Andersen W, Taylor P, Rice L. Minimizing the risk of neurologic injury in gynecologic surgery. *Obstet Gynecol* 2004;103:374-82.
  15. Lujendijk RW, Jeekel J, Storm RK, Schutte PJ, Hop WC, Drogendijk AC, et al. The low transverse Pfannenstiel incision and the prevalence of incisional hernia and nerve entrapment. *Ann Surg* 1997;225:365-9.
  16. Miyazaki F, Shook G. Iliioinguinal nerve entrapment during needle suspension for stress incontinence. *Obstet Gynecol* 1991;80:246-8.
  17. Benson JT, Griffis K. Pudenda! neuralgia, a severe pain syndrome. *Am J Obstet Gynecol* 2004;192:1663-8.
  18. Neill C, Abdel-Fattah M, Ramsay IN. Sexual function and vaginal surgery. *The Obstetrician & Gynaecologist* 2009;11:193-8.
  19. Connell K, Guess MK, La Combe J, Wang A, Powers K, Lazarou G, Mikha M. Evaluation of the role of pudendal nerve integrity in female sexual function using noninvasive techniques. *Am J Obstet Gynecol* 2005;192:1712-7.
  20. Moore AE, Zhang J, Stringer MD. Iatrogenic nerve injury in a national no-fault compensation scheme: an observational cohort study. *Int J Clin Pract* 2012;66:409-16.