

## Case Report

# Robert's Uterus, Rare Uterine Anomaly: A Case Report

SHAKEELA ISHRAT<sup>1</sup>, IVA RANI NANDI<sup>2</sup>, JESMINE BANU<sup>3</sup>

### Abstract:

*Roberts uterus is an extremely rare variety of congenital mullerian duct anomaly. It is also known as asymmetric septate uterus. The uterine septum is complete and fused with uterine wall on one side dividing the cavity into two: one non-communicating and another communicating with cervix. Regular menstrual flow occurs from the communicating cavity. At the same time, obstruction to menstrual flow in one cavity results in formation of hematometra, sometimes hematosalpinx and endometriosis. Presenting symptoms are severe dysmenorrhea and abdominal pain. Imaging modalities like three dimensional ultrasonography or magnetic resonance imaging are useful in diagnosing the mullerian duct anomaly. Traditionally the condition has been treated by laparotomy followed by complete excision of the obstructed one sided cavity. In recent years, incision of septum has been done by hysteroscopy, resulting in a uterine cavity with better reproductive outcome. Here presented the case of a 19 year old woman with Robert's uterus. The imaging modalities failed to diagnose the case. The anomaly was explored by laparoscopy and hysteroscopy followed by laparotomy. The obstructed hemi-cavity had thick altered blood. It was obliterated following excision of endometrium. The woman was relieved of pain thereafter.*

**Key words:** Mullerian anomalies, Robert's uterus, Septate uterus, Hematometra.

### Introduction:

Roberts uterus is an extremely rare variety of mullerian duct anomaly. It can be considered as variant of septate uterus, class V of American Society of Reproductive Medicine (ASRM) Classification and class U2 of European Society of Human Reproduction and Embryology-European Society for Gynaecological Endoscopy (ESHRE-ESGE) classification.<sup>1</sup> Other terms ascribed to it include obstructive septate uterus or asymmetric septate uterus. The uterine septum is complete and fused with uterine wall on one side. In other words, the uterine septum divides the uterine cavity asymmetrically into hemi cavities, one non-communicating and another communicating with cervix (Fig 1). Regular menstrual flow occurs. At the

same time, obstruction to menstrual flow in obstructed cavity results in hematometra, sometimes hematosalpinx and endometriosis. Presenting symptoms are severe dysmenorrhea, recurrent and acute abdominal pain.<sup>2</sup>

The uterine anomaly was first described by H Robert in 1970<sup>2</sup>. Since then there have been a few case reports of the condition. Imaging modalities like three dimensional ultrasonography or magnetic resonance imaging are useful in diagnosing the mullerian duct anomaly. Traditionally the condition has been treated by explorative laparotomy followed by complete excision of the obstructed hemicavity. When there is associated adnexal mass (hematosalpinx or endometriotic cyst) additional clearance is needed.<sup>2-6</sup>

1. Associate Professor, Department of Reproductive Endocrinology and Infertility, Bangabandhu Sheikh Mujib Medical University, Dhaka, Bangladesh
2. FCPS Trainee, Department of Reproductive Endocrinology and Infertility, Bangabandhu Sheikh Mujib Medical University, Dhaka, Bangladesh
3. Chairman, Department of Reproductive Endocrinology and Infertility, Bangabandhu Sheikh Mujib Medical University, Dhaka, Bangladesh

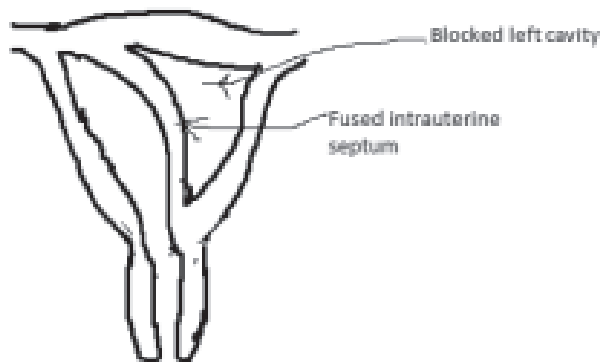
**Address of Correspondence:** Dr Shakeela Ishrat, Associate Professor, Department of Reproductive Endocrinology and Infertility, Room no 113, Block D, Bangabandhu Sheikh Mujib Medical University, Cellphone: 01729897221, Email: shakeelaishrat@bsmmu.edu.bd

In recent years, incision of septum has been done by hysteroscopy, resulting in a uterine cavity with better reproductive outcome.<sup>7-9</sup> Here we have reported a case of Robert's uterus in a 19 years old women.

#### Case Summary:

A 19 year old unmarried college student presented with painful menstruation since menarche and left sided lower abdominal pain for last two and a half years. Her menarche was at the age of 13 years followed by regular menstruation of average flow and duration. Dysmenorrhea began 1 day after menstruation, persisted throughout menstruation and subsided thereafter. But for the last two months the pain was severe and not relieved after menstruation.

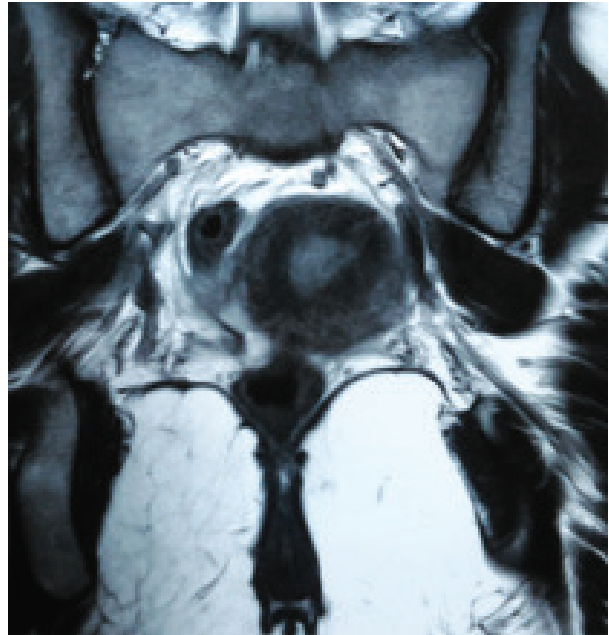
On examination, she was of average body built with well-developed secondary sex characters. Vulva and perineum appeared normal. Since she was an unmarried girl, per rectal examination was done which revealed an asymmetrically enlarged uterus. She had an ultrasonogram which reported bicornuate uterus with haematometra. There was echogenic fluid collection within endometrial cavity suggesting haematometra. Kidneys, ureters and bladder were normal in size and position.



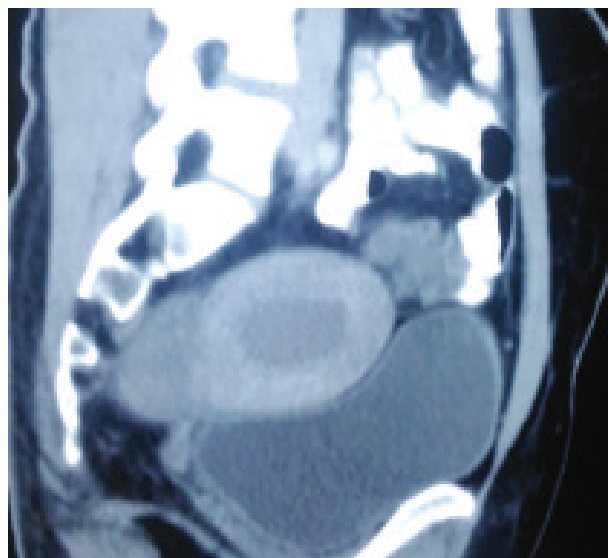
**Fig.-1:** Roberts uterus

She had an MRI which also reported the uterine malformation as bicornuate uterus with haematometra. But the MRI films, when reviewed after surgery suggested otherwise. The coronal (Fig 2) and sagittal (Fig 3) images showed a thick hypointense septum in uterus which asymmetrically divided the endometrial cavity into a smaller right cavity and a larger left cavity. The lower portion of

the septum was transversely oriented and was obstructing the left endometrial cavity leading to haematometra and distension. Chronic blood products typically appeared bright in T1W and T2W fat suppressed images and a shady effect on T2W images. The right endometrial cavity was normally communicating with the cervical and vaginal canal. Uterine fundal contour was normal.



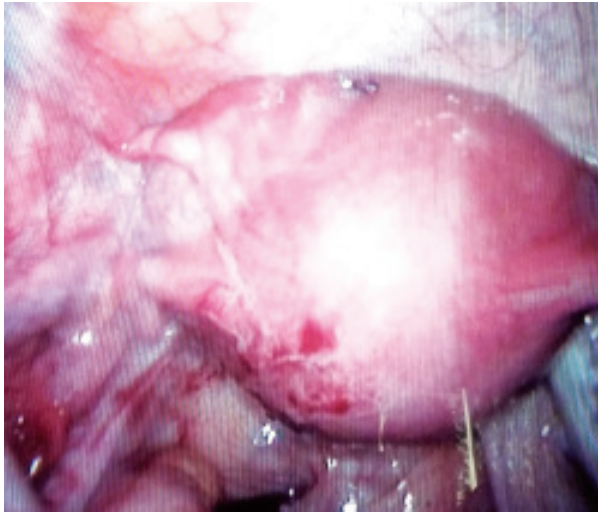
**Fig.-2:** MRI Coronal view : The endometrial cavity asymmetrically divided into a smaller right cavity and a larger left cavity



**Fig.-3:** MRI Sagittal view: A thick hypointense septum in uterus

The provisional diagnosis was bicornuate uterus with non-communicating functional horn. She was given continuous progestin therapy to suppress menstruation and referred to Bangabandhu Sheikh Mujib Medical University. When examined under anesthesia, vagina and the cervix appeared normal. She had diagnostic laparoscopy and hysteroscopy followed by laparotomy.

At laparoscopy it was apparent that the uterus was not bicornuate or unicornuate as the fundus was normal and intact. Bilateral tubes and ovaries appeared normal. The uterus was enlarged in size, more on left side with a swelling between the round ligament and fallopian tube (Fig 4). At hysteroscopy the cervix was patent. Tubal ostium was visible on right side but not on the left side.



**Fig.-4:** Laparoscopic view of uterus: fundus intact, a swelling on left side between fallopian tube and round ligament of uterus

After laparotomy, at first altered brown coloured thick blood was aspirated by syringing from the swelling on the left side of uterus. An incision was given on the left sided bulged area to open up the cavity. Endometrial lining was excised, leaving the myometrium intact as far as possible. The residual cavity was found as dead space and obliterated with sutures after myomectomy.

Patient was discharged on seventh postoperative day after an uneventful postoperative period. During follow-up she had normal cyclical menstruation without dysmenorrhea.

### Discussion:

Female genital tract develops from the embryonic structures called paramesonephric duct or mullerian duct. There is fusion of the two mullerian ducts proceeding cephaloid from the mullerian tubercle upto the junction of future round ligament. Shortly after that there is resorption of the septum between the two ducts. Congenital defects of uterus results from failure of fusion or resorption. Partially fused uterus with two recognizable horns results in bicornuate uterus. When the midline septum is not adequately resorbed, it gives rise to septate uterus. The external configuration of uterus is relatively normal with a septum within the uterus<sup>4</sup>.

Robert's uterus is a variant of septate uterus in which inferior part of the septa deviates to fuse with uterine wall on one side causing obstruction to one uterine hemi-cavity. The obstructed cavity with functional endometrium and cyclical menstrual flow which does not find a way out while the other cavity communicates with the cervix and has normal menstrual outflow<sup>4</sup>. The pubertal girl presents with cyclical menstrual period with severe dysmenorrhea. Other mullerian anomalies like unicornuate uterus with non-communicating functional horn<sup>10</sup> and obstructed hemi-vagina with ipsilateral renal anomaly (OHVIRA) syndrome<sup>11</sup> present with similar symptoms of normal menstrual flow and severe dysmenorrhea since menarche. The menstrual flow can extend into the fallopian tube leading to the formation of hematosalpinx, chocolate cyst and pelvic endometriosis.<sup>4</sup> Cryptomenorrhea, due to congenital anomalies and less commonly due to acquired causes like trauma, has long term complications of endometriosis and infertility.<sup>12</sup>

The 2-D ultrasound of uterus can identify two separate cavities, one cavity enlarged with hematometra. However it has limitation as it cannot assess the outer contour of the uterus. The 2-D ultrasound is helpful in visualizing the associated adnexal masses like hematosalpinx or chocolate cyst, but unable to differentiate different types of mullerian duct anomalies.<sup>3,6</sup> Three dimensional or volumetric reconstruction of multiple 2D images is done in 3-D ultrasonogram. This computerized multi-planar reconstruction acquired and displayed over time is known as realtime 3-D, live 3-D or 4-D ultrasonogram.<sup>13</sup> Coronal view 3-D/4-D sonogram of uterus can delineate surface contour, myometrium,

extent of septum or fundal indentation and distance between ostia, which cannot be done by hysterosalpingography or hysteroscopy.<sup>14</sup> The relationship between cavity and myometrium can be adequately visualized by 3-D/4-D ultrasonogram as well as magnetic resonance imaging (MRI).<sup>15</sup> MRI is the imaging modality of choice for full visualization of the extent of mullerian abnormalities. It is the most reliable imaging modality for the diagnosis of Robert's uterus because it shows the uterine septa with normal external uterine fundal contour as well as hematometra and hematosalpinx.

The patients are treated by explorative laparotomy followed by opening up the uterus and excision of obstructed hemicavity. Instead of removal of hemiuterus, uterine cavity can be opened and only endometrium is excised sparing the myometrium. Then the cavity is obliterated by sutures. Excision of obstructed hemicavity leads to disruption of myometrium followed by scar tissue formation, exposing the girl to the risk of rupture at the time of pregnancy and delivery.<sup>2,5</sup>

Hysteroscopy is useful because it can directly evaluate the uterine cavity and when combined with laparoscopy can adequately visualize the uterine malformation<sup>7</sup>. In recent years, the condition has been managed by hysteroscopy. Electrosurgical excision of the obstructing septum has been done with needle electrode of transvaginal resectoscope under sonographic guidance to avoid uterine perforation.<sup>8-9</sup> Transvaginal excision of septum has many advantages. Disruption of uterine wall and scar formation is avoided. Preservation of adequate and functional uterine cavity is possible which is crucial for future pregnancy without rupture. However there should be adequate expertise with hysteroscopy. Safety should be ensured by simultaneous sonographic monitoring.<sup>9</sup>

There has been a case report of pregnancy in Robert's uterus.<sup>16</sup> Pregnancy was in right non-communicating half, the left non-pregnant half communicating with the cervix. The women gave history of only mild dysmenorrhea. She also had one previous full term delivery at home. The non-communicating horn did not appear to cause her any problems. Rare trans-peritoneal migration of sperms may result in pregnancy in the non-communicating half of the uterus<sup>2</sup>

Young women with severe dysmenorrhea or suspected endometriosis should be investigated for congenital anomalies. Obstructed genital anomalies are a risk factor of endometriosis in adolescents. One study reported congenital anomalies in 32% of adolescents with pelvic endometriosis.<sup>17</sup>

There may be inappropriate surgeries if the gynecologists are not aware of this rare anomaly while managing severe dysmenorrhoea in menstruating young girls<sup>18</sup>. Pre-surgical evaluation for appropriate diagnosis is mandatory for appropriate counselling of the patients and planning endoscopic surgeries, if possible.

### Conclusion:

Robert's uterus is a very rare uterine anomaly. It can be well evaluated with MRI. Gynecologists should read the MRI themselves and correlate the findings clinically. It is important to consider the congenital anomalies in young women who have severe dysmenorrhea since menarche with normal menstrual flow. Early diagnosis and treatment will prevent progression to debilitating endometriosis and infertility. Hysteroscopic resection of septum will provide a larger uterine cavity and better reproductive outcome.

### References:

1. Ludwin A, Ludwin I. Comparison of the ESHRE-ESGE and ASRM classification of Mullerian duct anomalies in every day practice. *Hum Reprod* 2015; 30(3):569-580
2. Maddukuri SB, Karegowda LH, Prakashini K, Kantipudi S. Roberts uterus: a rare congenital mullerian duct anomaly causing hematometra *BMJ CaseRep* 2014 (Published online)
3. Mittal P, Gupta R, Mittal A, Taneja A, Shekhon PS, Gupta S. Magnetic Resonance Imaging (MRI) depiction of Roberts uterus: A rare Mullerian Duct Anomaly presenting with cyclical pain in young menstruating women. *Pol J Radiol* 2017; 82:134-36
4. Capito C, Sarnacki S. Menstrual retention in a Roberts uterus *J Pediatr Adolesc Gynecol* 2009; 22(5):e104-6
5. Bhuyar S, Deshmukh P. Roberts uterus with menstrual retention-a rare mullerian anomaly. *Srilanka J ObsGynae* 2014; 43-44

6. Behr SC, Courtier JL, Qayyum A. Imaging of mullerian duct anomalies. *Radiographics*. 2012; 132(6):E233-50
7. Perino A, Chianciano N, Simonaro C, Cittadini E. Endoscopic management of a case of complete septate uterus with unilateral hematometra. *Hum Reprod* 1995; 10(8):2171-73
8. Xiao S, Xue M, Wan Y, Li Y, Xu D. Hysteroscopy and laparoscopy based diagnosis and treatment of girls with unbroken hymen with an obstructive uterine septum : two case reports *J of Med Case Reports* 2014; 8:222
9. Ludwin A, Ludwin I, Martins WP. Roberts septate uterus: modern imaging technique and ultrasonogram guided hysteroscopic treatment without laparoscopy/laparotomy. *Ultrasound Obstet Gynecol* 2016 ; 48(4):526-529
10. Mabrouk M, Arena A, Zanello M, Raimando D, Seracchioli R, Unicornuate uterus with non-communicating functional horn : diagnostic work up and laparoscopic horn amputation. *FertilSteril* 2020;113:885-7
11. Smith NA, Laufer MR. Obstructed hemivagina and ipsilateral renal anomaly (OHVIRA) syndrome: management and follow up. *FertilSteril* 2007; 87:918-22
12. Mazhar SB, Mumtaz J, Saeed Q, Nawaz F. Cryptomenorrhoea secondary to past childhood pelvic trauma in young adolescent girls: case series. *Fertility & Reproduction*. 2019; 1930: 119-121
13. Benacerraf BR, Benson CB, Abuhamad A, Copel JA, Abramowicz JS, DeVore GR et al. Three and 4-dimensional ultrasound in Obstetrics and Gynecology. Proceedings of the American Institute of Ultrasound in Medicine Consensus Conference. *J Ultrasound Med* 2005;24:1587-1597
14. Bocca SM, Oehninger S, Stadtmayer L, Agard J, Duran AH, Sarhan A et al. A study of the cost, accuracy and benefits of 3-dimensional sonography compared with hysterosalpingography in women with uterine anomalies. *J Ultrasound Med* 2012; 31:81-85
15. Bermejo C, Ten PM, Cantarero R, Diaz D, Pedregosa JP, Barron E et al. Three-dimensional ultrasound in diagnosis of Mullerian duct anomalies and concordance with magnetic resonance imaging. *Ultrasound ObstetGynecol* 2010; 35:393-601
16. Madhurs C, Varuna P. Pregnancy in non-communicating half of septate uterus. *J ObstetGynecol India* 2012;62:s31-s32
17. Mattaliotakis M, Goulielmos GN, Matalliotaki C, Trivli A, Mattaliotakis I, Arici A. Endometriosis in adolescents and young girls: report on a series of 55 cases. *J PediatrAdolescGynecol* 2017;30(2):568-570
18. John SK, Prabhu S, Virmani S, Kumar V, Thotan SP. Misdiagnosed Roberts uterus leading to surgical misadventures. *J PediatrAdolesc Gynecol* 2017;30(4): 508-510