



**BJP**

**Bangladesh Journal of Pharmacology**

**Research Article**

**Hepatoprotective studies on meth-  
anolic extract of whole plant of *Lin-  
dernia ciliata***

## Hepatoprotective studies on methanolic extract of whole plant of *Lindernia ciliata*

Pallerla Praneetha, Vanapatla Swaroopa Rani, Yellu Narasimha Reddy and Bobbala Ravi Kumar

Department of Pharmacognosy and Phytochemistry, University College of Pharmaceutical Sciences, Kakatiya University, Telangana State, India.

### Article Info

Received: 18 September 2014

Accepted: 10 October 2014

Available Online: 5 November 2014

DOI: 10.3329/bjp.v9i4.20471

### Cite this article:

Praneetha P, Rani VS, Reddy YN, Kumar BR. Hepatoprotective studies on methanolic extract of whole plant of *Lindernia ciliata*. Bangladesh J Pharmacol. 2014; 9: 567-74.

### Abstract

*Lindernia ciliata* is traditionally used in the treatment of jaundice. In the present study, the methanolic extract of *L. ciliata* was evaluated for its hepatoprotective activity in paracetamol, ethanol and D-galactosamine intoxicated rats. The activity of the extract was assessed on the basis of improvement in the altered level of various serum biochemical parameters and in the changes occurred in the histology of liver of the rats. The extract was also investigated for its anti-oxidant potential by employing different *in vitro* methods. Among the three test doses of extract, 200 mg/kg was found to be the most effective dose. The significant ( $p < 0.01$ ) hepatoprotective and anti-oxidant activities exhibited by the extract, in different *in vivo* models and *in vitro* studies respectively may be attributed to the flavonoids and phenolic

### Introduction

Hepatic damage is a global metabolic and epidemic disease affecting essential biochemical activities in almost every age group (Dhiman et al., 2012). Excess consumption of certain drugs like paracetamol, antibiotics and some chemotherapeutic agents and exposure to some chemicals such as peroxidised oils, aflatoxin,  $\text{CCl}_4$  and alcohol make liver vulnerable to variety of disorders including hepatitis. These account for high death rate (Nirmala et al., 2012). Though there are many herbs used traditionally for the treatment of jaundice and chronic liver diseases, only few of them have been scientifically evaluated and still there are a number of plants which are yet to be investigated scientifically.

*Lindernia ciliata* (Colsm.) Pennell. of family Scrophulariaceae is a low growing, stoloniferous, mat-forming, annual, herb from 0.1 - 0.2 m high. It is restricted to the tropics and sub-tropics of Asia, northern Australia and North America. In India it was found as an insignificant weed, mainly in rice fields (Neamsuvan et al., 2012).

Traditionally it is used as a remedy for gonorrhoea, jaundice, urinary disturbances, bronchitis, headache, liver complaints, spleen diseases, constipation, fever, loss of appetite, asthma, cough, skin diseases (Devi et al., 2013). In view of its traditional medicinal use in the treatment of liver disorders, the present study was designed to evaluate its hepatoprotective activity against three mechanistically devised models viz. paracetamol, ethanol and D-galactosamine induced hepatotoxicity in rats and its *in vitro* anti-oxidant activity.

### Materials and Methods

#### Animals

Wistar albino rats weighing 150-200 g were purchased from Sainath agencies, Hyderabad, India with a prior permission from our institutional animal ethical committee (CPCSEA Reg. No. 146/2009) and used for the studies. The animals were housed in standard polypropylene cages, and maintained under standard



laboratory conditions (12:12 hours light and dark cycle; at an ambient temperature of  $25 \pm 5^\circ\text{C}$ ; 35- 60% of relative humidity). The animals were fed with standard rat pellet diet and water *ad libitum*.

#### **Drugs and chemicals**

Paracetamol was obtained as gift sample from Dr. Reddy's Lab, Hyderabad, India. All other drugs and chemicals were purchased from various companies and the details are as follows: Silymarin, D-galactosamine (D-GalN)- Sigma-Aldrich, Spruce Street, St. Louis, China; The biochemical analytical kits aspartate aminotransferase (AST), alanine aminotransferase (ALT), alkaline phosphatase (ALP), total bilirubin (TB), direct bilirubin (DB), glucose (GLU), albumin (ALB), total protein (TP), lactate dehydrogenase (LDH), and trichloro acetic acid (TCA) - Merck Specialities Private Limited, Mumbai, India; 1,1 Diphenyl-1-picryl hydrazyl (DPPH), thiobarbituric acid (TBA), phosphate buffer saline (PBS) (pH- 7.4) - Himedia, Mumbai, India; Deoxyribose, Griess reagent,  $\text{H}_2\text{O}_2$ , nitro blue tetrazolium (NBT), phenazine methosulphate (PMS), nicotinamide adenine dinucleotide (NADH), phosphate buffer saline (PBS), ethylene amine adenine dinucleotide phosphate (EDTA) - Sigma, Germany; ethanol- Changshu Yangyuan Chemicals, China. All other chemicals and solvents used were of analytical grade.

#### **Collection and preparation of extracts**

The plant *L. ciliata* was collected in the month of August 2012, from rice fields of Bhayyaram, Telangana state, India, after the authentication of the plant by Prof. V.S. Raju, Department of Botany, Kakatiya University, Warangal. A voucher specimen of the plant (KU/UCPSC/49) is being maintained in the herbarium of Department of Pharmacognosy and Phytochemistry, University College of Pharmaceutical Sciences, Kakatiya University, Warangal.

The whole plant was air dried, coarsely powdered and macerated with methanol in a round bottom flask for 7 days with intermittent stirring and filtered after seven days and concentrated under reduced pressure to yield a green semisolid mass. It was given a code extract.

#### **Acute toxicity study**

Acute toxicity study was carried out for methanolic extract of *L.ciliata* according to the Organization for Economic Co-operation and Development (OECD) 420 guidelines (OECD, 2001). All animals were observed for toxic symptoms and mortality for 72 hours.

#### **Total phenolic content**

The total phenolic content of the extract was determined using the Folin-Ciocalteu colorimetric method as described elsewhere (Marinova et al., 2005). The extract (100-1,000  $\mu\text{g}/\text{mL}$ ) or standard solution of gallic acid (10-100  $\mu\text{g}/\text{mL}$ ) was added to 25 mL volumetric flask containing 9 mL of distilled deionised

water. A reagent blank was prepared using distilled water instead of sample. One milliliter of Folin-Ciocalteu phenol reagent was added to the mixture and shaken. After 5 min, 10 mL of 7% aqueous sodium carbonate was added to the mixture. The solution was diluted to 25 mL with dd  $\text{H}_2\text{O}$  and mixed. After incubation for 90 min at room temperature, the absorption against prepared reagent blank was determined at 760 nm using UV-Visible spectrophotometer. Quantification was done with respect to the standard gallic acid and expressed as gallic acid equivalents (GAE) in mg per gram of extract.

#### **Total flavonoid content**

The total flavonoid content of the extract was measured using the aluminum chloride colorimetric method as described in the literature (Marinova et al., 2005). The extract (100-1000  $\mu\text{g}/\text{mL}$ ) or standard solution of rutin (10-100  $\mu\text{g}/\text{mL}$ ) was added to 10 mL volumetric flask, containing 4 mL of double distilled  $\text{H}_2\text{O}$ . To the flask 0.3 mL of 5% sodium nitrite solution was added. After 5 min, 0.3 mL of 10% aluminum chloride solution was added. At 6<sup>th</sup> min 2 mL of 1M NaOH was added and the total volume was made-up to 10 mL with dd  $\text{H}_2\text{O}$ . The solution was mixed well and the absorbance was measured against prepared reagent blank at 510 nm. The total flavonoid content was expressed as rutin equivalents in mg per gram of extract.

#### **Paracetamol-induced hepatotoxicity in rats**

The experiment was performed according to the method given in the literature with minor modifications (Gini et al., 2010). The rats were divided into six groups comprising six in each. 2% gum acacia was used as vehicle for suspending the standard drug and the extract. Group I was kept as control received single daily dose of vehicle (2% gum acacia 1 mL/kg) for seven days. Groups II, III, IV, V and VI were given orally daily dose of vehicle (2% gum acacia 1 mL/kg), silymarin (100 mg/kg), extract (100, 200 and 400 mg/kg) once a day for seven days respectively. On 8<sup>th</sup> day a dose of paracetamol (3 g/kg) was administered to the animals of all groups leaving Group I. Then blood and liver samples were collected from the animals of all groups 24 hours after administration of paracetamol for estimation of various biochemical parameters and histopathological studies respectively.

#### **Ethanol-induced hepatotoxicity in rats**

The protective effect of extract against ethanol induced liver damage was done according to the procedure given in the literature with minor modifications (Zhen-Lu et al., 2007). The rats were divided into six groups and pretreated for ten days with single daily dose of vehicle, silymarin, and the extract in different doses as described in paracetamol induced hepatotoxicity experiment. On 10<sup>th</sup> day one hour after the daily treatment, the animals of all the groups except group I,

intoxicated with an acute oral dose of ethanol (5 g/kg) diluted with distilled water (6:4 v/v). The blood and liver samples were collected 18 hours after administration of ethanol under ether anesthesia, for quantification of various biochemical parameters and histopathological studies respectively.

#### **Assessment of antihepatotoxic activity of effective dose of extract against D-GaIN induced hepatotoxicity in rats**

The antihepatotoxic activity of extract against D-GaIN induced hepatotoxicity was carried out according to the procedure given in the literature with minor modifications (Karan et al., 1999). The rats were randomly divided into four groups of six animals each. Group I served as normal and received the vehicle (1 mL/kg orally of 2% gum acacia in water) for 3 days. On the first day, D-GaIN (400 mg/kg i.p) was given to groups II, III and IV. Vehicle (2% gum acacia 1 mL/kg), silymarin (100 mg/kg) and EXTRACT (200 mg/kg) were given to the animals of Groups II, III and IV respectively for three times at the time point of 2, 24, 48 hours after the administration of D-GaIN. The blood and liver samples were collected from the animals 1 hour after the last treatment for estimation of various biochemical parameters and histopathological studies respectively.

#### **Determination of prothrombin time (Yanling et al., 2008)**

The prothrombin time was determined by collecting blood in normal capillary tubes and breaking it into pieces until a thread is observed. Time was noted between the collections of blood to the appearance of thread.

#### **Histological studies**

Histological studies were done by staining the fine section of liver isolates and examining under the microscope. The liver samples collected from the rats of the study were washed with normal saline (0.9%). Then, 2-3 pieces of approximately 6 cm size were cut and fixed in phosphate buffered 10% formaldehyde solution. After embedding in paraffin wax, thin sections of 5 mm thickness of liver tissue were cut and stained with hemotoxylin-eosin stain.

#### **In vitro anti-oxidant studies on extract**

##### **DPPH radical scavenging assay**

This method was performed as described in the literature with minor modifications (Blios et al., 1958). 1 mL of 0.1 mM solution of DPPH in methanol was added to 2.5 mL of the test extract in methanol (10-100 µg/mL). The reaction mixture was then allowed to stand at room temperature in a dark chamber for 30 min. After 30 min, absorbance was measured at 517 nm using UV-Visible spectrophotometer. Rutin was used as a standard. The scavenging activity of DPPH radical (%) was calculated from the following equation:

$$\% \text{Scavenging activity} = [A_{\text{Control}} - A_{\text{Extract}}] / A_{\text{Control}} \times 100.$$

Lower absorbance of the reaction mixture indicates higher free radical scavenging activity.

##### **Superoxide scavenging activity**

The procedure was done according to the method described in the literature with slight modification (Nishikimi et al., 1972). 1.0 mL each of NBT solution (156 µM in 0.1 M PBS, pH 7.4), NADH solution (468 µM in 0.1 M PBS, pH 7.4) and test extract (dissolved in 0.1M PBS, pH 7.4) of different concentrations (100-1,000 µg/mL) were mixed. Then 1 mL of PMS solution (60 µM in 0.1M PBS, pH 7.4) was added and incubated at 25°C for 5 min. The absorbance of all the mixtures was measured against a blank (0.1M PBS, pH 7.4) at 560 nm. Rutin was used as a positive control in the assay. The scavenging activity on superoxide radical was calculated by using the following formula:

$$\% \text{Scavenging activity} = \{ [A_0 - (A_1 - A_2)] / A_0 \} \times 100$$

A<sub>0</sub>: Absorbance of control (PBS instead of extract solution); A<sub>1</sub>: Absorbance of sample; A<sub>2</sub>: Absorbance of sample under identical conditions as A<sub>1</sub> with PBS instead of NBT solution

##### **Nitric oxide scavenging activity**

The assay was carried out according to the reported method (Garratt et al., 1964). 1.0 mL each of 10 mM sodium nitroprusside, phosphate buffered saline (pH 7.4) and various concentrations (100-1,000 µg/mL) of the test extracts were mixed. The mixture was incubated for 150 min at 25°C. To 0.5 mL of the incubated solution, 1 mL sulfanilamide (0.33% in 20% glacial acetic acid) was added and allowed to stand for 5 min. Then 1 mL of naphthylethylenediamine dihydrochloride (NED) (0.1% w/v) was added and the mixture was incubated for 30 min at 25°C. The pink chromophore generated was measured spectrophotometrically at 540 nm against a blank sample. Ascorbic acid was used as standard.

##### **Hydroxyl radical scavenging activity**

Hydroxyl radical scavenging activity was evaluated using the method of Bibhabasu, (2008) with slight modifications (Bibhabasu et al., 2008). 100 µL each of 2-deoxy-2-ribose (2.8 mM), phosphate buffer (20 mM, pH 7.4), FeCl<sub>3</sub> (100 µM), EDTA (100 µM), H<sub>2</sub>O<sub>2</sub> (1.0 mM) and ascorbic acid (100 µM) were mixed with 400 µL of various concentrations (100-1000 µg/mL) of the test sample and incubated for 1 hour at 37°C. To 0.5 mL of the reaction mixture 1 mL 2.8% TCA and 1 mL 1% aqueous TBA were added and the mixture was incubated at 90°C for 15 min to develop the color. After cooling, the absorbance was measured at 532 nm against an appropriate blank solution. Mannitol, a classical hydroxyl radical scavenger, was used as a positive control.

##### **Reducing power assay**

The assay was performed according to the reported

method (Oyazu et al., 1986). Stock solutions were prepared by dissolving 10 mg of the extract in 1 mL of DMSO and working concentrations (10–100 µg/mL) were prepared in PBS (0.2 M). 2.5 mL of the test extract at different concentrations was mixed with 2.5 mL of 1% potassium ferricyanide. After incubating the mixture at 50°C for 20 min, 2.5 mL of 10% TCA was added and centrifuged at 1,036 rpm for 10 min. Then 2.5 mL of upper layer of reaction mixture was mixed with 2.5 mL of distilled water and 0.5 mL of 0.1% freshly prepared FeCl<sub>3</sub> solution. The absorbance of the reaction mixture was measured at 700 nm. Ascorbic acid was used as positive control. Increased absorbance of the reaction mixture indicated increased reducing power.

### Statistical analysis

The data obtained were analyzed by one-way of variance (ANOVA) followed by Durnett all Vs control for the significant interrelation between the various groups using GraphPad prism-3 computer software.  $p < 0.05$  and  $p < 0.01$  were considered to be significant.

## Results

The total flavonoid content in the methanolic extract of *L. ciliata* was found to be  $75.5 \pm 0.9$  mg of rutin equivalents per gram of extract and the total phenolic content was  $31.3 \pm 1.9$  mg of gallic acid equivalents/g of extract.

Paracetamol intoxication in normal rats significantly ( $p < 0.01$ ) elevated the level of hepatospecific enzymes (AST, ALT, ALP), TB, DB, LDH and decreased the level of TP, ALB in serum (Table I). It indicates acute hepatocellular damage and biliary obstruction which was endorsed by the histopathological examination of the liver sections of rats showing centrilobular necrosis, dilatation of sinusoidal spaces, and bleeding in hepatic lobes (Figure 1). The rats treated with extract and silymarin showed a significant ( $p < 0.01$ ) protection, against paracetamol-induced hepatic damage by normalizing serum biochemical parameters and by minimizing the histopathological abnormalities. Among the test doses, percentage

Groups	SGOT (U/L)	SGPT (U/L)	ALP (U/L)	TB (mg/dL)	DB (mg/dL)	TP (g/dL)	ALB (g/dL)	LDH (U/L)	PT (sec)
Normal	63.6 ± 3.1	77.4 ± 2.6	339.2 ± 8.1	0.2 ± 0.0	0.04 ± 0.01	8.8 ± 0.3	3.7 ± 0.0	163.4 ± 6.2	12.7 ± 2.1
Toxic	126.8 ± 6.7	366.4 ± 18.3	838.2 ± 8.5	2.1 ± 0.1	1.1 ± 0.1	3.1 ± 0.2	1.8 ± 0.2	385.3 ± 7.9	147.2 ± 4.8
Standard	74.7 ± 1.9 <sup>a</sup>	100.7 ± 3.2 <sup>a</sup>	378.5 ± 8.9 <sup>a</sup>	0.3 ± 0.0 <sup>a</sup>	0.1 ± 0.0 <sup>a</sup>	8.2 ± 0.3 <sup>a</sup>	3.3 ± 0.1 <sup>a</sup>	183.7 ± 4.9 <sup>a</sup>	24.1 ± 5.5 <sup>a</sup>
Extract 100 mg/kg	94.9 ± 2.2 <sup>a</sup>	153.3 ± 5.5 <sup>a</sup>	444.7 ± 5.1 <sup>a</sup>	0.5 ± 0.0 <sup>a</sup>	0.4 ± 0.0 <sup>a</sup>	6.7 ± 0.2 <sup>a</sup>	2.7 ± 0.0 <sup>a</sup>	224.1 ± 3.2 <sup>a</sup>	54.1 ± 2.5 <sup>a</sup>
Extract 200 mg/kg	87 ± 2.6 <sup>a</sup>	128.8 ± 3.7 <sup>a</sup>	403 ± 3.9 <sup>a</sup>	0.5 ± 0.0 <sup>a</sup>	0.2 ± 0.0 <sup>a</sup>	7.5 ± 0.3 <sup>a</sup>	2.9 ± 0.2 <sup>a</sup>	198.6 ± 5.6 <sup>a</sup>	39.5 ± 4.5 <sup>a</sup>
Extract 400 mg/kg	92.3 ± 2.1 <sup>a</sup>	139.4 ± 4.8 <sup>a</sup>	410.3 ± 5.9 <sup>a</sup>	0.5 ± 0.0 <sup>a</sup>	0.3 ± 0.0 <sup>a</sup>	7.3 ± 0.2 <sup>a</sup>	2.8 ± 0.1 <sup>a</sup>	207.9 ± 6.7 <sup>a</sup>	51.6 ± 6.1 <sup>a</sup>

Data expressed as mean ± SD; n = 6; values in parenthesis indicate percentage recovery. P value- Paracetamol Vs vehicle; P value Paracetamol Vs treatments- <sup>a</sup><0.01

Groups	SGOT (U/L)	SGPT (U/L)	ALP (U/L)	TB (mg/dL)	DB (mg/dL)	TP (g/dL)	ALB (g/dL)	LDH (U/L)	PT (sec)
Normal	31.4 ± 2.1	63.2 ± 2.8	392.1 ± 7.2	0.1 ± 0.0	0.1 ± 0.0	8.1 ± 0.1	4.9 ± 0.5	221.4 ± 1.5	12.6 ± 3.5
Toxic	132.7 ± 6.1	178.3 ± 4.1	843.2 ± 7.3	2.8 ± 0.1	0.8 ± 0.1	3.0 ± 0.1	2.2 ± 0.3	591.6 ± 2.7	145.6 ± 5.2
Standard	49.3 ± 3.6 <sup>a</sup>	78.3 ± 3.2 <sup>a</sup>	434.3 ± 7.5 <sup>a</sup>	0.4 ± 0.0 <sup>a</sup>	0.1 ± 0.0 <sup>a</sup>	7.2 ± 0.3 <sup>a</sup>	4.4 ± 0.3 <sup>a</sup>	243.7 ± 2.5 <sup>a</sup>	25.1 ± 3.4 <sup>a</sup>
Extract 100 mg/kg	76.4 ± 5.3 <sup>a</sup>	108.5 ± 6.9 <sup>a</sup>	513.1 ± 5.4 <sup>a</sup>	0.9 ± 0.2 <sup>a</sup>	0.3 ± 0.0 <sup>a</sup>	6.4 ± 0.2 <sup>a</sup>	3.5 ± 0.1 <sup>a</sup>	328.4 ± 4.2 <sup>a</sup>	58.2 ± 4.3 <sup>a</sup>
Extract 200 mg/kg	55.6 ± 2.7 <sup>a</sup>	88.2 ± 4.1 <sup>a</sup>	479.1 ± 7.2 <sup>a</sup>	0.6 ± 0.0 <sup>a</sup>	0.2 ± 0.0 <sup>a</sup>	7.1 ± 0.2 <sup>a</sup>	4.3 ± 0.1 <sup>a</sup>	271.3 ± 2.9 <sup>a</sup>	34.1 ± 3.2 <sup>a</sup>
Extract 400 mg/kg	60.3 ± 2.5 <sup>a</sup>	96.9 ± 3.7 <sup>a</sup>	491.2 ± 5.9 <sup>a</sup>	0.6 ± 0.0 <sup>a</sup>	0.3 ± 0.0 <sup>a</sup>	6.8 ± 0.2 <sup>a</sup>	4.0 ± 0.2 <sup>a</sup>	288.1 ± 5.2 <sup>a</sup>	41.1 ± 4.3 <sup>a</sup>

Data expressed as mean ± SD; n = 6; values in parenthesis indicate percentage recovery; P value - Ethanol Vs vehicle; P value Ethanol Vs treatments- <sup>a</sup><0.01

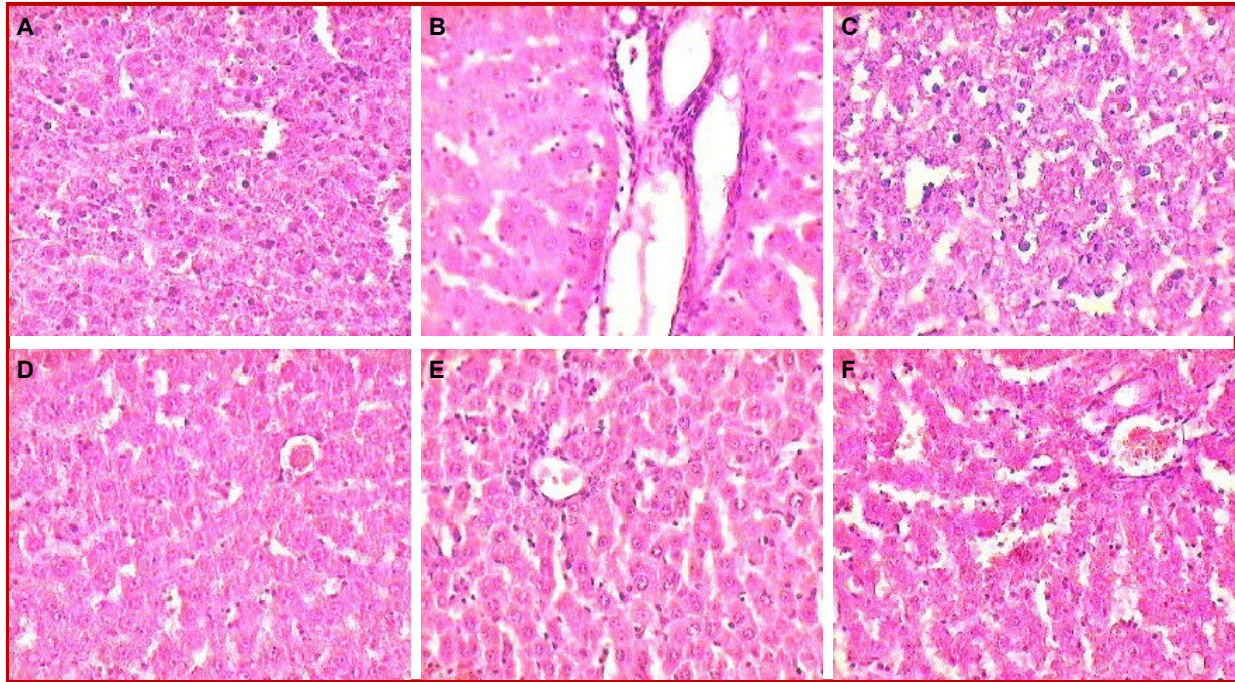


Figure 1: Effect of *Lindernia ciliata* extract on histopathological changes in liver of rats in paracetamol-induced hepatotoxicity (100x magnification) A) Normal; B) Toxic; C) Standard; D) Extract (100 mg/kg); E) Extract (200 mg/kg); F) Extract (400 mg/kg)

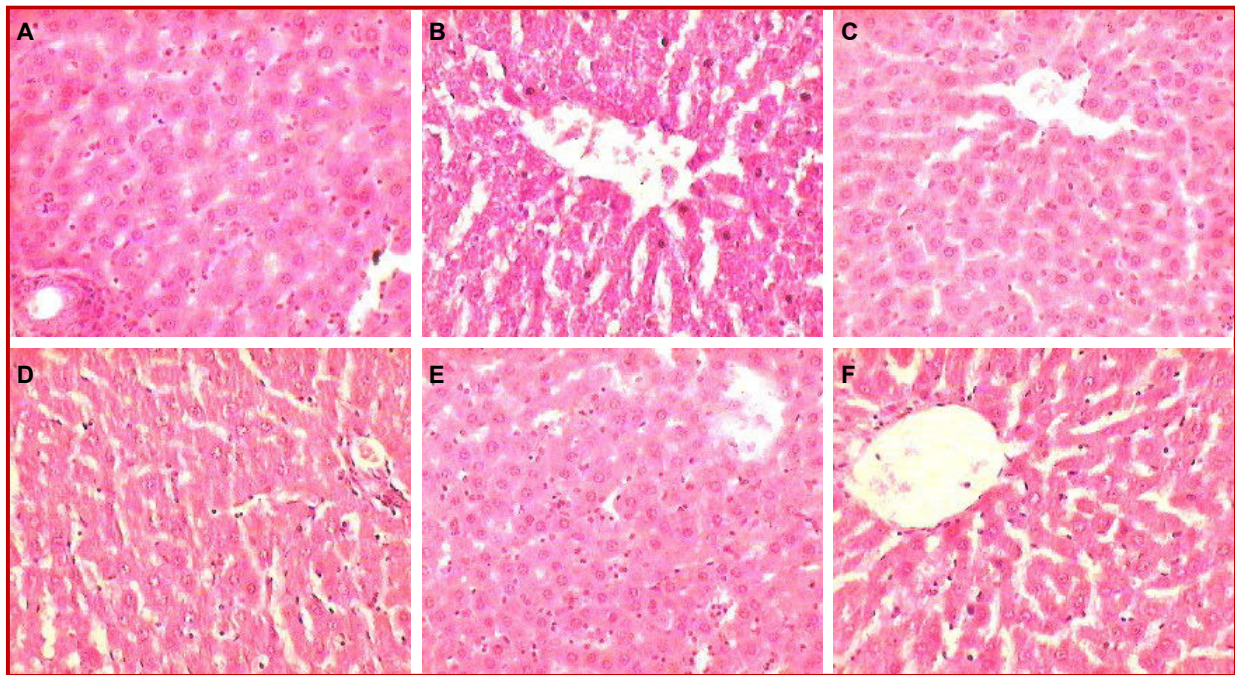


Figure 2: Effect of *Lindernia ciliata* extract on histopathological changes in liver of rats in ethanol-induced hepatotoxicity (100x magnification) A) Normal; B) Toxic; C) Standard; D) Extract (100 mg/kg); E) Extract (200 mg/kg); F) Extract (400 mg/kg)

protection shown by extract at 200 mg/kg was well comparable to that of silymarin (100 mg/kg).

Ethanol intoxication in normal rats also caused significant ( $p < 0.01$ ) alteration in the level of the serum biochemical parameters (Table II) and chan-

ges in the histology of the liver of the rats showing kupffer cell proliferation, dilatation of sinusoidal space and bleeding in hepatic lobes (Figure 2). Treatment with standard and all test doses showed a significant ( $p < 0.01$ ) recovery from the ethanol

Table III										
Effect of <i>Lindernia ciliata</i> on different serum biochemical parameters in D-galactosamine induced hepatotoxicity in rats										
	Glucose (U/L)	SGOT (U/L)	SGPT (U/L)	ALP (U/L)	TB (mg/dL)	DB (mg/dL)	TP (g/dL)	ALB (g/dL)	LDH (U/L)	PT (sec)
Normal	84.0 ± 3.0	65.7 ± 3.0	69.2 ± 2.3	452.7 ± 4.2	0.15 ± 0.0	0.02 ± 0.01	8.8 ± 0.3	3.9 ± 0.2	199.0 ± 8.9	18.5 ± 2.3
Toxic	15.6 ± 2.5	199.9 ± 4.4	263.1 ± 6.2	1282.6 ± 11.6	2.7 ± 0.2	1.8 ± 0.1	4.2 ± 0.3	1.4 ± 0.1	373.2 ± 6.3	157.1 ± 5.4
Standard	64.3 ± 3.5 <sup>a</sup>	81.5 ± 2.0 <sup>a</sup>	87.8 ± 2.1 <sup>a</sup>	537.8 ± 13.1 <sup>a</sup>	0.6 ± 0.0 <sup>a</sup>	0.2 ± 0.0 <sup>a</sup>	8.0 ± 0.2 <sup>a</sup>	3.3 ± 0.2 <sup>a</sup>	227.0 ± 5.6 <sup>a</sup>	29.8 ± 4.4 <sup>a</sup>
LC 200	50.3 ± 1.5 <sup>a</sup>	88.6 ± 3.6 <sup>a</sup>	96.9 ± 7.2 <sup>a</sup>	704.5 ± 21.5 <sup>a</sup>	0.8 ± 0.0 <sup>a</sup>	0.1 ± 0.0 <sup>a</sup>	8.0 ± 0.3 <sup>a</sup>	3.2 ± 0.2 <sup>a</sup>	242.5 ± 4.2 <sup>a</sup>	40.1 ± 4.4 <sup>a</sup>

Data expressed as mean ± SD, n = 6, values in parenthesis indicate percentage recovery. P value - D-galactosamine Vs vehicle; P value D-galactosamine Vs treatments- <sup>a</sup><0.01

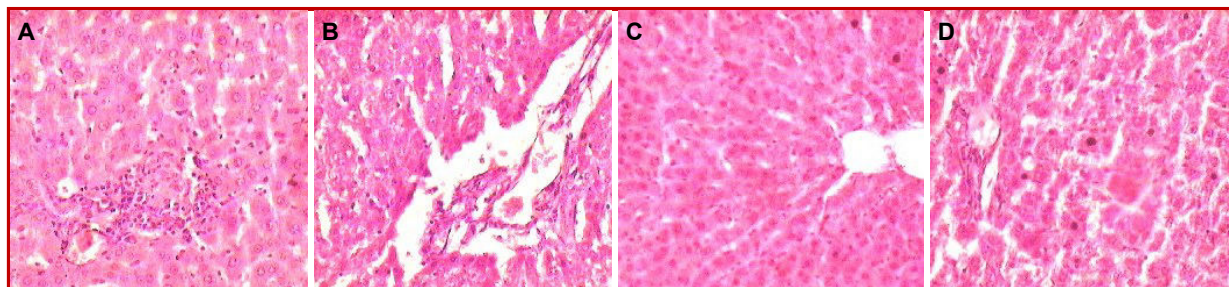


Figure 3: Effect of *Lindernia ciliata* extract on histopathological changes in liver of rats in galactosamine-induced hepatotoxicity (100x magnification) A) Normal; B) Toxic; C) Standard; D) Extract (200 mg/kg)

induced hepatic damage which was evident from the reversal of alterations in the level of serum biochemical parameters and changes in histology of liver. The extract, at all test doses exhibited a phenomenal hepatoprotective activity. Among the test doses, percentage protection shown by extract at 200 mg/kg was well comparable to that of silymarin 100 mg/kg.

The results of the study are presented in Table III and histopathological photographs of liver section of rats of the study are shown in Figure 3. Extract at 200 mg/kg orally was evaluated in the study since the percentage protection offered by it was well comparable to that of reference drug, silymarin 100 mg/kg in hepatoprotective studies. D-GaIN intoxication in normal rats significantly ( $p < 0.01$ ) increased the level of hepatic enzymes (AST, ALT, ALP), TB, DB, LDH and decreased the level of TP, ALB and GLU in serum and caused the remarkable changes in histology of the liver showing inflammatory infiltration of cells near portal areas, kupffer cell hyperplasia, ballooning degeneration, bleeding in central portal and midzonal areas. In silymarin (100 mg/kg b.w.) and extract 200 mg/kg treated rats a significant ( $p < 0.01$ ) protection, against D-GaIN induced hepatic damage was observed and was evident from the normalization of the level of the serum biochemical parameters and recovery from the histological changes.

The test extract has shown a concentration dependent *in vitro* free radical scavenging activity. The  $IC_{50}$  of the extract and the standard are shown in Table

IV. The extract also showed a concentration dependent reducing power. The reducing power of the extract is expressed in terms of ascorbic acid equivalents and was found to be  $44.7 \pm 1.7$  mg.

Table IV		
<i>In vitro</i> anti-oxidant studies on the extract		
Free radical	$IC_{50}$ value of the extract in $\mu\text{g/mL}$	$IC_{50}$ value of the extract standard in $\mu\text{g/mL}$
DPPH	$39.5 \pm 2.8$	$0.4 \pm 0.1$ (Rutin)
Superoxide	$422.6 \pm 5.7$	$3.4 \pm 0.1$ (Rutin)
Nitric oxide	$46.8 \pm 3.8$	$6.1 \pm 0.2$ (Ascorbic acid)
Hydroxyl radical	$259.2 \pm 2.1$	$3.4 \pm 0.1$ (Mannitol)

Data expressed as mean ± SD; n = 6

## Discussion

In the present study, extract was investigated for its hepatoprotective potential against three mechanistically devised models (paracetamol, ethanol and D-galactosamine) hepatotoxicity in rats. It is well known that overdoses of paracetamol are hepatotoxic. Drug induced liver injuries are wide spread and account for one half of the cases of acute liver failure and mimics all forms of acute and chronic liver diseases (Kaplowitz et al., 2001). Similarly, alcohol abuse is another major health problem worldwide.

Administration of paracetamol or ethanol increased the levels of AST, ALT, ALP and LDH in serum indicating damage to the liver cell plasma membrane as these enzymes are normally present in cytoplasm. Treatment with extract at 100, 200 and 400 mg/kg significantly reduced the elevated level of these enzymes in paracetamol or ethanol treated rats. This reflects that the extract have some functions in preserving structural integrity of hepatocellular membrane thus prevented enzymes leakage into the blood circulation. Besides various normal functions, liver excretes the breakdown product of hemoglobin namely bilirubin into bile. Administration of the necrotizing agents like paracetamol or ethanol produces sufficient injury to hepatic parenchyma to cause large increase in bilirubin content (Dufour et al., 2000). Pretreatment with extract at all the test doses significantly ( $p < 0.01$ ) decreased their levels and are comparable with that of silymarin (100 mg/kg). In paracetamol or ethanol-induced hepatotoxicity, a decrease in TP and albumin occurs due to the disruption and dissociation of polyribosomes on endoplasmic reticulum leading to defective protein biosynthesis. extract at 100, 200, 400 mg/kg increased the serum TP and ALB levels with varying degree of significance. This may be due to promotion of the assembly of ribosomes on endoplasmic reticulum to facilitate uninterrupted protein biosynthesis. Prothrombin or factor II is one of the clotting factors made by the liver. In paracetamol or ethanol intoxicated rats the PT was drastically increased which may be attributed to decreased synthesis of clotting factors. Recovery of PT after administration of test extracts provides an index of recovery of synthetic capacity of the damaged liver.

The hepatoprotective activity of extract was further verified by histopathological observations. It is well documented that over doses of paracetamol or ethanol leads to drastic alterations in histoarchitecture of liver showing centrilobular necrosis, fatty changes, dilation of sinusoidal spaces, kupffer cell proliferation, ballooning degeneration and bleeding area in hepatic lobes. The extract at all test doses showed a definite sign of protection and recovery against injury. Of the three test doses, extract at 200 mg/kg exhibited significant liver protection against the toxicants as evident from the reversal of changes in biochemical parameters and histoarchitecture of liver.

The hepatotoxicity induced by D-galactosamine resembles that of human viral hepatitis both in metabolic and morphological aberrations that always caused periportal necro inflammation and hepatocyte apoptosis (Keppler et al., 1968; Decker et al., 1974; Katunuma et al., 2006). D-GaIN has been known to cause hepatotoxicity by the accumulation of UDP-GaIN derivatives in the liver followed by a

depletion of hepatic UTP, resulting in the inhibition of mRNA and proteins (Aniya et al., 2005). Treatment with extract 200 mg/kg body weight significantly decreased the serum ALT, AST, LDH, ALP, TB and DB levels suggesting that *L. ciliata* might scavenge reactive oxygen species generated from D-GaIN intoxication and hence prevent hepatic cellular enzymes and bilirubin from leaking into the blood (Dufour et al., 2000). The extract also showed a remarkable recovery in PT and serum level of TP and ALB. Treatment with extract 200 mg/kg exhibited significant liver protection, by normalizing the histological architecture of liver of the rats, which was almost similar to that of silymarin (100 mg/kg).

Oxidative stress can be increased either by increase in free radical production in the body or by decrease in endogenous anti-oxidants. As so many free radicals can contribute to oxidative stress, individual assessment of susceptibility becomes important. Oxidative stress plays an important role in the pathogenesis of many liver diseases (Tanikawa and Torimura, 2006). In view of that, extract was systematically evaluated for its anti-oxidant ability using different *in vitro* methods. DPPH is a stable free radical, when anti-oxidant reacts with DPPH• the electron is paired off and the DPPH solution is decolorized (Bhagat, 2011). Nitric oxide plays a vital role in various inflammatory processes. Higher levels of these radical are toxic to tissue and contribute to the vascular collapse (Rajan et al., 2011). The hydroxyl radical is an extremely reactive free radical formed in biological systems and has been implicated as a highly damaging species in free radical pathology, capable of damaging almost every molecule found in living cells viz., DNA, lipids and proteins (Hochstein, 1988). Superoxide anion is also very harmful to cellular components and produced from molecular oxygen due to oxidative enzyme of body as well as via non-enzymatic reaction such as autoxidation by catecholamine's (Naskar et al., 2010). The methanolic extract of *L. ciliata* has shown a concentration dependent DPPH, nitric oxide, hydroxyl and superoxide radical scavenging activities. The extract also exhibited significant reducing power which ultimately adds to its anti-oxidant potential. The anti-oxidant activity may be attributed to the phenolic and flavonoidal compounds present in the extract.

---

### Acknowledgements

The overall results of the study indicated that the three activities exhibited by the extract are complementing each other in giving protection to the liver either as prophylactic or curative and substantiated the traditional claim of the plant, *L. ciliata* in the treatment of jaundice.



## Acknowledgements

This work was supported by a grant from UGC-BSR Meritorious Research Fellowship, New Delhi.

## References

- Aniya Y, Koyama T, Miyagi C, Miyahira M, Inomata C, Kinoshita S, Ichiba T. Free radical scavenging and hepatoprotective actions of the medicinal herb, *Crassocephalum crepidioides* from the Okinawa Islands. *Biol Pharm Bull.* 2005; 28: 9-23.
- Bhagat J, Lobo R, Parmar V. *In vitro* free radical scavenging potential of Indian habitant *Anisochilus carnosus* (L. F.) Wall [J]. *Chin J Nat Med.* 2011; 9: 456-60.
- Blios MS. Anti-oxidant determination by the use of stable free radical. *Nature* 1958; 181: 1199-200.
- Decker K, Keppler D. Galactosamine hepatitis: Key role of the nucleotide deficiency period in the pathogenesis of cell injury and cell death. *Rev Physiol Biochem Pharmacol.* 1974; 71: 77-106.
- Devi CHB, Singh NKS, Ram SS, Sudarshan M, Chakraborty A, Rajmuhon N. Trace element profile of some selected medicinal plants of Manipur, India. *Sci J Pure Appl Sci.* 2013; 2: 332-40.
- Dhiman A, Nanda A, Ahmad S. A recent update in research on the antihepatotoxic potential of medicinal plants. *J Chin Integr Med.* 2012; 10: 117-19.
- Dufour DR, Lott JA, Nolte FS, Gretch DR, Koff RS, Seeff LB. Diagnosis and monitoring of hepatic injury. II. Recommendations for use of laboratory tests in screening, diagnosis, and monitoring. *Clin Chem.* 2000; 46: 2050-68.
- Garratt DC. The quantitative analysis of drugs. Vol 3. Japan, Chapman and Hall Ltd, 1964, pp 456-58.
- Gini CK, Muraleedhara GK. Hepatoprotective effect of *Spirulina lonar* on paracetamol induced liver damage in rats. *Asian J Exp Biol Sci.* 2010; 1: 614-23.
- Hazra B, Biswas S, Mandal N. Anti-oxidant and free radical scavenging activity of *Spondias pinnata*. *BMC Comp Alt Med.* 2008; 8: 63.
- Hochstein P, Atallah AS. The nature of oxidant and anti-oxidant systems in the inhibition of mutation and cancer. *Mutation Res.* 1988; 202: 363.
- Kaplowitz N. Drug-induced liver disorders: Implications for drug development and regulation. *Drug Safety.* 2001; 24: 483-90.
- Karan M, Vasisht K, Handa SS. Antihepatotoxic activity of *Swertia chirata* against paracetamol and galactosamine induced hepatotoxicity in rats. *Phytother Res.* 1999; 13: 95-101.
- Katunuma N, Ohashi A, Sano E, Ishimaru N, Hayashi Y, Murata E. Catechin derivatives: Specific inhibitor for caspases-3, 7 and 2, and the prevention of apoptosis at the cell and animal levels. *FEBS Lett.* 2006; 580: 741-46.
- Keppler D, Lesch R, Reutter W, Decker K. Experimental hepatitis induced by D-galactosamine. *Exp Mol Pathol.* 1968; 9: 279-90.
- Lu ZM, Tao WY, Zou XL, Fu HZ, Ao ZH. Protective effects of mycelia of *Antrodia camphorata* and *Armillariella tabescens* in submerged culture against ethanol-induced hepatic toxicity in rats. *J Ethnopharmacol.* 2007; 110: 160-64.
- Marinova D, Ribarova F, Atanassova M. Total phenolics and total flavonoids in Bulgarian fruits and vegetables. *J Univ Chem Tech Met.* 2005; 40: 255-60.
- Naskar S, Islam A, Mazumder UK, Saha P, Haldar PK, Gupta M. *In vitro* and *in vivo* anti-oxidant potential of hydromethanolic extract of *Phoenix dactylifera* fruits. *J Sci Res.* 2010; 2: 144-57.
- Neamsuvan O, Singdam P, Yingcharoen K, Sengnon N. A survey of medicinal plants in mangrove and beach forests from sating Phra Peninsula, Songkhla Province, Thailand. *J Med Plants Res.* 2012; 6: 2421-37.
- Nirmala M, Girija K, Lakshman K, Divya T. Hepatoprotective activity of *Musa paradisiaca* on experimental animal models. *Asian Pac J Trop Biomed.* 2012; 10: 11-15.
- Nishikimi M, Rao NA, Yagi K. The occurrence of super oxide anion in the reaction of reduced *Phenazine methosulphate* and molecular oxygen. *Biochem Biophys Res Commun.* 1972; 46: 849-53.
- Oyaizu M. Studies on product of browning reaction prepared from glucose amine. *Japan J Nutr.* 1986; 44: 307-15.
- Rajan S, Mahalakshmi S, Deepa VM, Sathya K, Shajitha S, Thirunalasundari T. Anti-oxidant potentials of *Punica granatum* fruit rind extracts. *Int J Pharm Pharm Sci.* 2011; 3: 82-88.
- Tanikawa K, Torimura T. Studies on oxidative stress in liver diseases: Important future trends in liver research. *Med Mol Morphol.* 2006; 39: 22-27.
- Yanling S, Jie S, Hui H, Hui G, Sheng Z. Hepatoprotective effects of *Ganoderma lucidum* peptides against d-galactosamine-induced liver injury in mice. *J Ethnopharmacol.* 2008; 117: 415-19.

### Author Info

Pallerla Praneetha (Principal contact)  
e-mail: praneetha.sruthi@gmail.com