



BJP

Bangladesh Journal of Pharmacology

Research Article

Evaluation of hepatoprotective effect of chloroform and methanol extracts of *Opuntia monacantha* in paracetamol-induced hepatotoxicity in rabbits

Evaluation of hepatoprotective effect of chloroform and methanol extracts of *Opuntia monacantha* in paracetamol-induced hepatotoxicity in rabbits

Mohammad Saleem¹, Iram Irshad¹, Muhammad Kashif Baig² and Faiza Naseer¹

¹College of Pharmacy, GC University, Faisalabad, Pakistan; ²Independent Medical College, Faisalabad, Pakistan.

Article Info

Received: 7 November 2014

Accepted: 5 December 2014

Available Online: 3 January 2015

DOI: 10.3329/bjp.v10i1.20825

Cite this article:

Saleem M, Irshad I, Baig MK, Naseer F. Evaluation of hepatoprotective effect of chloroform and methanol extracts of *Opuntia monacantha* in paracetamol-induced hepatotoxicity in rabbits. Bangladesh J Pharmacol. 2015; 10: 16-20.

Abstract

The chloroform and methanol extracts of *Opuntia monacantha* were studied for its hepatoprotective effect against paracetamol-induced liver damage in rabbits. Results proved that both extracts at 200, 400 and 600 mg/kg body weight in one week protocol showed significant ($p < 0.001$) hepatoprotective activity by reducing the magnitude of liver markers including alanine aminotransferase, aspartate aminotransferase, alkaline phosphatase and total bilirubin levels. The results were supported by histopathological studies of liver tissue. Chemical analysis of *O. monacantha* indicated the presence of alkaloids, tannins, saponins, flavonoids and polysaccharides and its hepatoprotective potential may be due to the presence of flavonoids. It is concluded that 600 mg/kg is the potent dose of both extracts of *O. monacantha* as a hepatoprotective plant.

Introduction

The liver is "Great Chemical Factory" of the body as involved in regulation, synthesis, storage and secretion of many important proteins, nutrients and chemicals. The liver is also involved in detoxification of toxic chemicals and xenobiotics. It is exposed to various toxins, changing liver functions and eventually leading to liver ailments like hepatitis, cirrhosis and alcoholic liver disease (Ahsan et al., 2009). During many biochemical processes, free radical reactive oxygen species are generated that cause liver injury (Ali et al., 2004). Antioxidants can scavenge free radicals, thus limiting the process of hepatic cell necrosis (Raja et al., 2006). The investigation of natural plants and isolation of their beneficial constituents is very vital to control liver disease (Saleem and Naseer, 2014). Many hepatoprotective plants have been identified like *Cocculus hirsutus* (Thakare et al., 2009), *Carissa spinarum* (Hegde and Joshi, 2010), *Khamira Gaozaban Ambri Jadwar Ood Saleeb Wala* (Akhtar et al., 2013), *Trichodesma sedgwickianum* (Saboo et al., 2013), *Trianthema decandra*

(Balamurugan and Muthusamy, 2008), *Convolvulus arvensis* (Ali et al., 2013), *Ipomoea staphylinia* (Bag and Mumtaz, 2013), *Malva parviflora* (Mallhi et al., 2014), *Chenopodium murale* (Saleem et al., 2014) and *Rumex dentatus* (Saleem et al., 2014). Though we know the hepatoprotective and antioxidant potential of many plants, but still there is much less information available regarding the hepatoprotective potential of *Opuntia monacantha* commonly known as Chnutarthar from family: Cactaceae (Ahmad, 2007). This herb has been used for liver impairment traditionally but there is no scientific evidence available. Hence this study was undertaken with the objective to explore the hepatoprotective potential of *O. monacantha*.

O. monacantha has been used in urinary tract tumors, piles, inflammations, anemia, ulcers and enlargement of the spleen (Galati et al., 2002). The flowers have been used for respiratory and ophthalmic complaints and fruit in gonorrhoea (Ahmad, 2007). It has a traditional use as a medicinal agent for burns, indigestion and as antipyretic agent (Kifayatullah and Waheed, 2014).



Polysaccharides separated from *O. monacantha* have anti-diabetic and antiglycated activity. It also possesses free radical scavenging, antioxidant and antimicrobial potential (Bari et al., 2012).

Thus, the objective of the present study was to evaluate the hepatoprotective activity of the chloroform and methanol extracts of *O. monacantha* against paracetamol-induced liver damage in rabbits.

Materials and Methods

Collection of plants

The plant was collected from district Faisalabad, Punjab Pakistan. The plant was identified and authenticated by Dr. Mansoor Hameed, Department of Botany, University of Agriculture, Faisalabad. Voucher No. 1027-2012 can be used for future references.

Preparation of plant extract

The collected plant was cleaned, washed and dried under shade for a week and was pulverized in a mechanical grinder. The powder obtained (3 kg) was successively macerated first in chloroform (9L) and then in methanol (9L) solvents for seven days in airtight vessels with occasional shaking at room temperature. Then filtration was done with Whatman filter paper No. 1 and the filtrates were concentrated in a rotary evaporator at 61°C for chloroform extract and at 65°C for methanol extract. The concentrate was stored at 4°C in dark amber colored bottle (Ahmad and Eram, 2011).

Experimental animals

Rabbits were used as experimental animals in the study weighing between 1.2-1.5 kg. Standard diet and water *ad libitum* were given to them.

Experimental protocol

Fifty four rabbits were divided into 9 groups. Each group having 6 rabbits. The study was continued for a week (Grish et al., 2009; Yasmin et al., 2010). The study protocol was approved by the Ethical Review Committee, GC University, Faisalabad, Pakistan.

Group I received distilled water (5 mL/kg p.o) daily for seven days and served as normal control. Group II received distilled water (5 mL/kg p.o) daily and paracetamol (2,000 mg/kg) after three hours daily for seven days.

Group III received standard drug silymarin (100 mg/kg) and paracetamol (2,000 mg/kg) after three hours daily for seven days.

Group IV received a chloroform extract of *O. monacantha* (200 mg/kg) and paracetamol (2,000 mg/kg) after three hours daily for seven days.

Group V received a chloroform extract of *O. monacantha*

(400 mg/kg) and paracetamol (2,000 mg/kg) after three hours daily for seven days.

Group VI received a chloroform extract of *O. monacantha* (600 mg/kg) and paracetamol (2,000 mg/kg) after three hours daily for seven days.

Group VII received methanol extract of *O. monacantha* (200 mg/kg) and paracetamol (2,000 mg/kg) after three hours daily for seven days.

Group VIII received a methanol extract of *O. monacantha* (400 mg/kg) and paracetamol (2,000 mg/kg) after three hours daily for seven days.

Group IX received a methanol extract of *O. monacantha* (600 mg/kg) and paracetamol (2,000 mg/kg) after three hours daily for seven days.

Biochemical investigation

In this study, evaluation of hepatoprotective activity was done biochemically and histopathologically. On the 8th day, blood samples were taken and clotted for 45 min at room temperature and serum was separated by centrifugation at 2,500 rpm for 15 min. Separated serum was used for the estimation of biochemical parameters like alanine aminotransferases (ALT), aspartate aminotransferases (AST), alkaline phosphatases (ALP) and total bilirubin level (Ali et al., 2013).

Histopathological examination

Histopathological studies were performed in the Pathology Lab of the Independent University, Hospital, Faisalabad, Pakistan to examine the microscopic changes in liver anatomy (Saleem et al., 2014). After 48 hours of the last dose of treatment, phenobarbitone anesthesia (35 mg/kg i.p.) was given and animals were slaughtered. Liver from each animal was removed after dissection and preserved in 10% formalin. Sections of livers stained with hematoxylin and eosin were observed microscopically for histopathological changes.

Preliminary phytochemical analysis

Phytochemical analysis was done to determine the presence of alkaloids, tannins, saponins and flavonoids, polysaccharides, steroids and anthraquinones (Bari et al., 2012).

Statistical analysis

Values were represented as mean \pm SEM and data was analyzed by one-way ANOVA. Values were taken as significant $p < 0.001$.

Results

Hepatoprotective effect of chloroform and methanolic extracts at 200, 400 and 600 mg/kg were determined by estimating liver enzymes: AST, ALT, ALP and TB. The average value of the AST of normal animals was $66.8 \pm$

Table I**Effect of chloroform and methanolic extracts of *O. monacantha* on AST, ALT, ALP and TB levels**

Treatment	TB (mg/dL)	ALT (U/L)	AST (U/L)	ALP (U/L)
Distill water	0.7 ± 0.0	68.2 ± 4.7	66.8 ± 8.4	117.3 ± 5.3
Distill water + Paracetamol (2,000 mg/kg)	3.3 ± 0.2	165.3 ± 22.4	115.6 ± 12.2	223.3 ± 7.7
Silymarin (100 mg) + Paracetamol (2,000 mg/kg)	0.5 ± 0.0	68.8 ± 7.7	75.5 ± 8.4	133.5 ± 9.9
Chloroform extract (200 mg) + Paracetamol (2,000 mg/kg)	1.8 ± 0.3	98.3 ± 6.6	86.3 ± 4.5	145.6 ± 7.7
Chloroform extract (400 mg) + Paracetamol (2,000 mg/kg)	1.3 ± 0.2	95.3 ± 16.0	82.5 ± 11.9	141.5 ± 9.5
Chloroform extract (600 mg) + Paracetamol (2000 mg/kg)	1.0 ± 0.1	93.6 ± 6.6	80.8 ± 6.4	138.5 ± 6.2
Methanol extract (200 mg) + Paracetamol (2000 mg/kg)	1.6 ± 0.2	99.0 ± 5.9	98.2 ± 6.7	145.0 ± 2.1
Methanol extract (400 mg) + Paracetamol (2,000 mg/kg)	1.2 ± 0.3	80.1 ± 8.0	90.0 ± 5.8	141.7 ± 17.6
Methanol extract (600 mg) + Paracetamol (2,000 mg/kg)	1.1 ± 0.1	76.1 ± 4.7	78.2 ± 7.2	139.5 ± 11.8

8.4 U/L. Treatment with paracetamol raised this value to 115.6 ± 12.2 U/L. Administration of chloroform extract of *O. monacantha* at a dose of 200, 400 and 600 mg/kg brought this enzyme level to 86.3 ± 4.5 U/L, 82.5 ± 11.9 U/L and 80.8 ± 6.4 U/L respectively, but the methanol extract with same doses altered the AST level as 98.2 ± 6.7 U/L, 90.0 ± 5.8 U/L and 78.2 ± 7.2 U/L respectively which was comparable to standard hepatoprotective drug silymarin AST level 75.5 ± 8.4 U/L (p<0.001) (Table I).

The average value of ALT of normal animals was 68.2 ± 4.7 U/L. Treatment with paracetamol raised this value up to 165.3 ± 22.4 U/L. Administration of chloroform extract of *O. monacantha* at a dose of 200, 400 and 600 mg/kg brought this enzyme level to 98.3 ± 6.6 U/L, 95.3 ± 16.0 U/L and 93.6 ± 6.6 U/L respectively and methanol extract decreased to 99.0 ± 5.9 U/L, 80.1 ± 8.0 U/L and 76.1 ± 4.7 U/L respectively which was comparable to silymarin 68.8 ± 7.7 U/L (p<0.001) (Table I).

The average value of ALP of normal animals was 117.3 ± 5.3 U/L. Treatment with paracetamol raised this value to 223.3 ± 7.7 U/L. Administration of chloroform extract of *O. monacantha* at a dose of 200, 400 and 600 mg/kg brought this enzyme level to 145.6 ± 7.7 U/L, 141.5 ± 9.5 U/L and 138.5 ± 6.2 U/L respectively, and methanol extract with same doses decreased enzyme to 145.0 ± 2.1 U/L, 141.7 ± 17.6 U/L and 139.5 ± 11.8 U/L respectively, compared to silymarin 133.5 ± 9.9 U/L (p<0.001) (Table I).

The average value of TB of normal animals was 0.7 ± 0.0 mg/dL. Treatment with paracetamol raised this value to 3.3 ± 0.2 mg/dL. Administration of chloroform extract of *O. monacantha* at a dose of 200, 400 and 600 mg/kg brought this level to 1.8 ± 0.3 mg/dL, 1.3 ± 0.2 mg/dL and 1.0 ± 0.1 mg/dL respectively, and methanol extract to 1.6 ± 0.2 mg/dL, 1.2 ± 0.3 mg/dL and 1.1 ± 0.1 mg/dL respectively, compared to silymarin 0.5 ± 0.0 mg/dL (p<0.001) (Table I).

Table II**Phytochemical analysis of *Opuntia monacantha***

Compounds	Chloroform extract	Methanol extract
Alkaloids	+	+
Polysaccharides	+	+
Tannins	+	+
Saponins	+	+
Flavonoids	+	+
Steroids	-	-
Anthraquinones	-	-

Histopathological studies showed that the liver tissues were normal in the control group. Paracetamol treated group showed inflammation and tissue necrosis. Silymarin treated group showed mild inflammation. Animals treated with chloroform extract of *O. monacantha* showed mild inflammation that was comparable to standard drug. Maximum protection was shown in the dose of 600 mg/kg. Animals treated with methanolic extract of *O. monacantha* also showed a hepatoprotective effect and it was more pronounced with 600 mg/kg extract dose shown in Figure 1.

The Phytochemical Screening showed the presence of alkaloids, tannins, saponins, Polysaccharides and flavonoids and absence of steroids and anthraquinones in both chloroform and methanolic extracts (Table II).

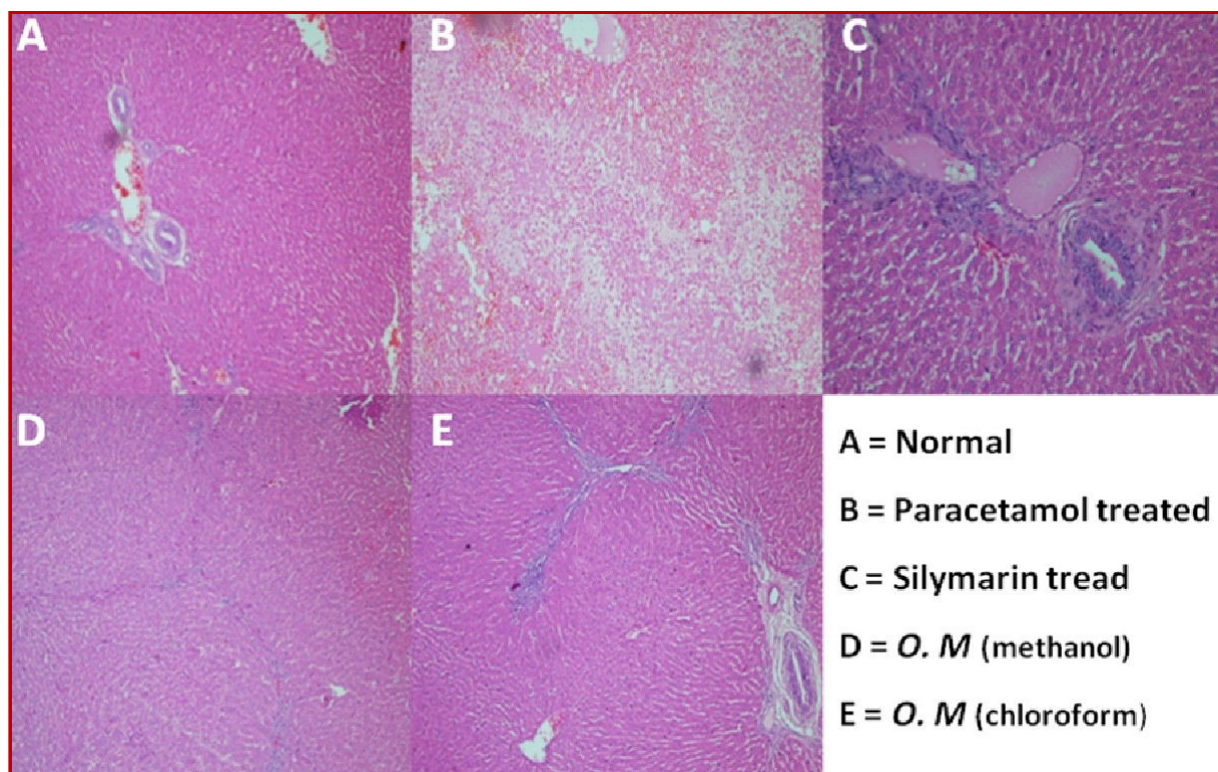


Figure 1: Histopathological study of liver sections of rabbit; (A) Normal group: Liver section showing normal liver morphology; hepatocytes has a round nucleus centrally homogenous cytoplasm, flat endothelial cells around central vein and sinusoid. (B) Paracetamol treated group: showing liver architecture is destroyed, showing replacement of hepatocytes by inflammatory cells comprising neutrophils and rare lymphocytes. The hepatocytes showed necrosis with intervening hemorrhage. (C) Silymarin treated group: In liver section, 1-2 hepatocytes rows around the central vein showed; hepatic cell degeneration along with necrosis (loss of nuclei), less injury of endothelial cells around central vein and less fat vacuoles in hepatocytes (D) *O. monacantha* (Methanol) treated group: liver architecture was maintained showing normal arrays of hepatocytes with intervening normal sinusoids. The hepatocytes were normal polygonal with granular eosinophilic cytoplasm and round nuclei. The portal tracts were normal with few lymphocytes. (E) *O. monacantha* (Chloroform) treated group: In liver section, 1-2 hepatocytes rows around the central vein showed; hepatic cell degeneration along with necrosis (loss of nuclei), less injury of endothelial cells around central vein and less fat vacuoles in hepatocytes

Discussion

Paracetamol-induced liver toxicity and cell death are due to generation of toxic metabolites after its metabolism through CYP-450 (Ibrahim et al., 2011). It is converted into N-acetyl P-benzoquinoneimine, produces oxidative stress and causes glycogen and glutathione depletion by irreversible conjugation with sulfhydryl groups of glutathione (Saleem and Naseer, 2014). In the present study protective effect of chloroform and methanol extract of *O. monacantha* against paracetamol-induced liver injury in rabbits has been studied. After administration of a toxic dose of paracetamol, the magnitude of liver marker enzymes boosted up and produced tissue necrosis. When the plant chloroform and methanol extracts in 200, 400 and 600 mg/kg/day doses for a week were administered p.o. to rabbits, less increase in enzymes (ALT, AST & ALP) and bilirubin level was observed as compared to paracetamol treated group ($p < 0.001$).

When these alterations in biochemical parameters were compared with the reference (silymarin), a very less difference was observed. The results indicated that extract treated animals showed incredible recovery ($p < 0.001$) and supported by histopathology of liver section. Hepatotoxin treated group showed altered morphology and tissue necrosis while extract treated group showed fewer changes and hepatotoxicity. Phytochemical analysis of *O. monacantha* showed the presence of polyphenols, flavonoids, alkaloids, tannins, saponins and polysaccharides and these were reported to be hepatoprotective (Ali et al., 2013; Mallhi et al., 2014). It may be concluded that hepatoprotective activity of chloroform and methanol extract of *O. monacantha* is due to the presence of these important constituents.

So, it is concluded that 600 mg/kg of chloroform and methanol extract of *O. monacantha* is highly potent dose as hepatoprotective agent and this potential may be due

to the presence of the active constituent: polyphenols, flavonoids, alkaloids and tannins.

References

- Ahmad M, Eram S. Hepatoprotective studies on *Haloxylon Salicornicum*: A plant from cholistan desert. Pakistan J Pharm Sci. 2011; 24: 377-82.
- Ahmad SS. Medicinal wild plants from Lahore-Islamabad motorway (M-2). Pakistan J Botany. 2007; 39: 355-75.
- Ahsan R, Islam MK, Musaddik A, Haque E. Hepatoprotective activity of methanol extract of some medicinal plants against carbon tetrachloride induced hepatotoxicity in Albino rats. Global J Pharmacol. 2009; 3: 116-22.
- Akhtar MS, Asjad HMM, Bashir S, Malik A, Khalid R, Gulzar F, Irshad N. Evaluation of antioxidant and hepatoprotective effects of *Khamira Gaozaban Ambri Jadwar Ood Saleeb Wala* (KGA). Bangladesh J Pharmacol. 2013; 8: 44-48.
- Ali M, Qadir MI, Saleem M, Janbaz KH, Gul H, Hussain L, Ahmed B. Hepatoprotective potential of *Convolvulus arvensis* against paracetamol-induced hepatotoxicity. Bangladesh J Pharmacol. 2013; 8: 300-04.
- Ali M, Ramachandram R, Rafiullah MR, Singh O, Siddiqui AW, Mir SR. Prevention of carbon tetrachloride-induced hepatotoxicity by the ethanol extract of *Capparis moonii* fruits in rats. Pharma Bio. 2004; 42: 286-88.
- Bag AK, Mumtaz SMF. Hepatoprotective and nephroprotective activity of hydroalcoholic extract of *Ipomoea staphylina* leaves. Bangladesh J Pharmacol. 2013; 8: 263-68.
- Balamurugan G, Muthusamy P. Observation of the hepatoprotective and antioxidant activities of *Trianthema decandra* Linn. (Vallai sharunnai) roots on carbon tetrachloride-treated rats. Bangladesh J Pharmacol. 2008; 3: 83-89.
- Bari NM, Zubair M, Rizwan K, Rasool N, Bukhari HI, Akram S, Bokhari HT, Shahid M, Hameed M, Ahmad UV. Biological activities of *Opuntia Monacantha* Cladodes. International Centre for Chemical and Biological Sciences, University of Karachi. 2012; 34: 990-95.
- Galati EM, Tripodo MM, Trovato A, Miceli N, Monforte MT. Biological effect of *Opuntia ficus indica* (L.) Mill. (Cactaceae). J Ethnopharmacol. 2002; 79: 19-22.
- Girish C, Koner BC, Jayanthi S, Rao KR, Rajesh B, Pradhan SC. Hepatoprotective activity of six polyherbal formulations in paracetamol induced liver toxicity in mice. Indian J Med Res. 2009; 3: 569-78.
- Hegde K, Joshi AB. Hepatoprotective and antioxidant effect of *Carissa spinarum* root extract against CCl₄ and paracetamol-induced hepatic damage in rats. Bangladesh J Pharmacol. 2010; 5: 73-76.
- Ibrahim M, Khaja ZU, Narasu ML. Hepatoprotective activity of *Boswellia serrata* extracts: *In vitro* and *in vivo* studies. Int J Pharm Applications. 2011; 2: 89-98.
- Kifayatullah M, Waheed I. Evaluation of hydroethanolic extract of *Opuntia monacantha* haw cladodes for antipyretic activity. World J Pharm Pharmaceut Sci. 2014; 3: 1021-30.
- Mallhi TH, Abbas K, Ali M, Qadir MI, Saleem M, Khan YH. Hepatoprotective activity of methanolic extract of *Malva parviflora* against paracetamol-induced hepatotoxicity in mice. Bangladesh J Pharmacol. 2014; 9: 342-46.
- Raja S, Ahamed KF, Kumar V. Antioxidant effect of *Cytisus scoparius* against carbon tetrachloride treated liver injury in rats. J Ethnopharmacol. 2006; 109: 41-47.
- Saboo SS, Tapadiya G, Farooqui IA, Khadabadi SS. Free radical scavenging, *in vivo* antioxidant and hepatoprotective activity of folk medicine *Trichodesma sedgwickianum*. Bangladesh J Pharmacol. 2013; 8: 58-64.
- Saleem M, Ahmed B, Karim M, Ahmed S, Ahmad M, Qadir MI, Syed NIH. Hepatoprotective effect of aqueous methanolic extract of *Rumex dentatus* in paracetamol induced hepatotoxicity in mice. Bangladesh J Pharmacol. 2014; 9: 284-89.
- Saleem M, Ahmed B, Qadir MI, Karim M, Rafiq M, Ahmad M, Ahmad B. Hepatoprotective effect of *Chenopodium murale* in mice. Bangladesh J Pharmacol. 2014; 9: 124-28.
- Saleem M, Naseer F. Medicinal plants in the protection and treatment of liver diseases. Bangladesh J Pharmacol. 2014; 10: 511-26.
- Thakare SP, Jain HN, Patil SD, Upadhyay UM. Hepatoprotective effect of *Cocculus hirsutus* on bile duct ligation-induced liver fibrosis in albino Wistar rats. Bangladesh J Pharmacol. 2009; 4: 126-30.
- Yasmin S, Kashmiri AM, Anwar K. Screening of aerial parts of *Abutilon bidentatum* for hepatoprotective activity in rabbits. J Medicinal Plants Res. 2011; 5: 349-53.

Author Info

Mohammad Saleem (Principal contact)
e-mail: saleem2978@hotmail.com