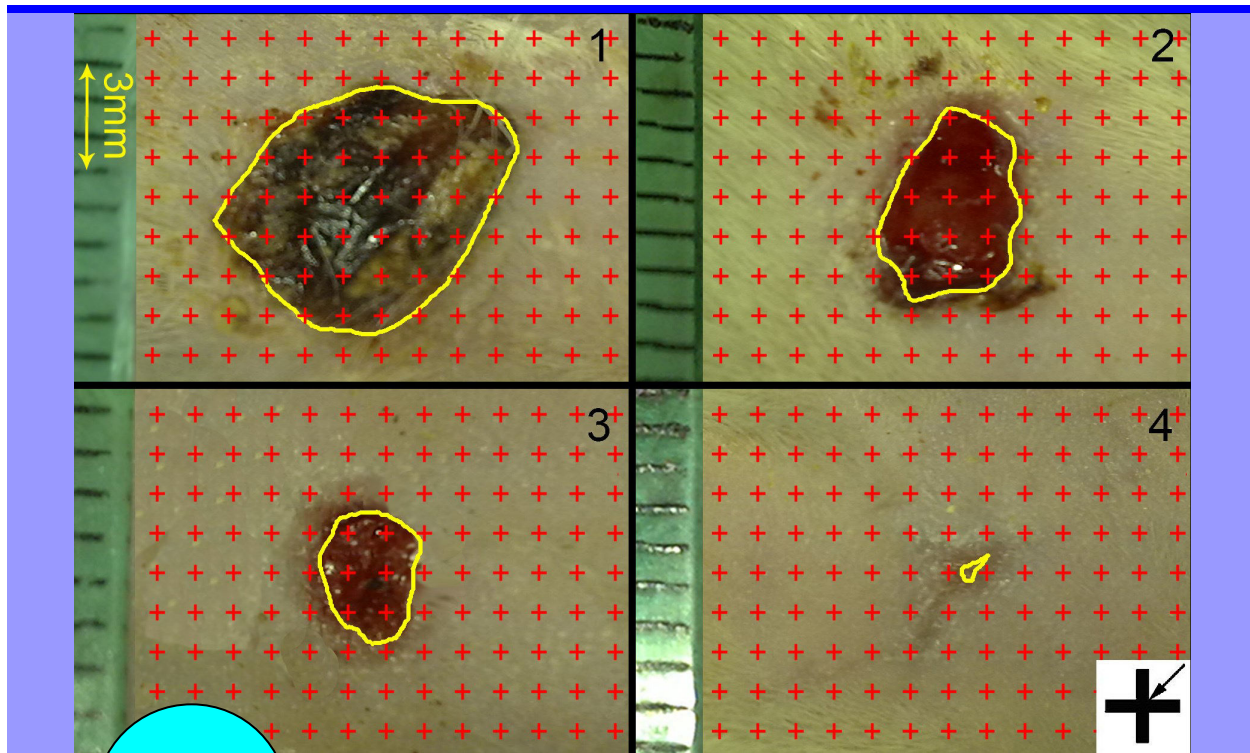

BJP

Bangladesh Journal of Pharmacology

Research Article

The wound healing effect of *Iris forentina* on full thickness excisional skin wounds: A histomorphometrical study

## The wound healing effect of *Iris florentina* on full thickness excisional skin wounds: A histomorphometrical study

Seyed Abbas Mirmalek<sup>1</sup>, Tina Parsa<sup>2</sup>, Yekta Parsa<sup>2</sup>, Soheila Yadollah-Damavandi<sup>2</sup>, Seyed Alireza Salimi-Tabatabaee<sup>3</sup>, Ehsan Jangholi<sup>2</sup>, Sahar Hosseini<sup>4</sup>, Soheil Ashkani-Esfahani<sup>5</sup>, Hanieh Abooghadareh<sup>4</sup> and Erfan Haghighifard<sup>4</sup>

<sup>1</sup>Department of Surgery, Islamic Azad University, Tehran Medical Sciences Branch, Tehran, Iran; <sup>2</sup>Young Researchers and Elite Club, Islamic Azad University, Tehran Medical Sciences Branch, Tehran, Iran; <sup>3</sup>Students' Research Committee, Islamic Azad University, Tehran Medical Sciences Branch, Tehran, Iran; <sup>4</sup>Student Research Committee, Shiraz University of Medical Sciences, Shiraz, Iran; <sup>5</sup>Shiraz Medical School, Shiraz University of Medical Sciences, Shiraz, Iran.

### Article Info

Received: 28 June 2015

Accepted: 1 October 2015

Available Online: 18 December 2015

DOI: 10.3329/bjp.v11i1.23906

### Cite this article:

Mirmalek SA, Parsa T, Parsa Y, Yadollah-Damavandi S, Salimi-Tabatabaee SA, Jangholi E, Hosseini S, Ashkani-Esfahani S, Abooghadareh H, Haghighifard E. The wound healing effect of *Iris florentina* on full thickness excisional skin wounds: A histomorphometrical study. Bangladesh J Pharmacol. 2016; 11: 86-90.

### Abstract

*Iris florentina* is an ancient herbal remedy which was prescribed by many physicians due to its positive effects on dermatological problems, specifically skin wounds. Hence, we aimed to investigate the effects of this agent on full-thickness excisional skin wounds in laboratory rats. Three groups of rats (180 ± 20 g; n=8) with 1 cm diameter full-thickness excisional skin wound received daily treatment with *I. florentina* 10% ointment, and a group with no treatment. By using histomorphometrical methods, the amount of fibroblast population, collagen bundle synthesis, and vascularization (length density, mean diameter and volume density of the vessels) were estimated. Outcome of the study exhibited that the increase in fibroblast proliferation rate, collagen bundle synthesis, vascular density and vascular mean diameter in *I. florentina* treated group were significant in comparison to the untreated group (p<0.05). Results indicated that *I. florentina* can be prescribed as a herbal medicine for treatment of skin wounds or be used as an additional agent for today's common medicines.

### Introduction

*Iris*, a genus of 260–300 species of flowering plants, takes its name from the Greek word for a rainbow (Mavrodiev et al., 2014; Mosihuzzman et al., 2013), referring to the wide variety of flower colors found among the species (Manning and Goldblatt, 2008; Masson et al., 2014). Various books on traditional medicine such as “The Canon of Medicine” written by Avicenna and “Al-Hawi” by Rhazes, have mentioned different therapeutic effects for this genus such as anti-inflammatory (anti-swelling), pain reduction, and positive effects in the treatment of irritations, and skin ulcers caused by burns, diabetic ulcers, and superficial wounds especially in combination with herbs such as

Mint leaves and Chamomile (Avicenna, 1984; Zarshenas et al., 2012). Other ancient physicians had also noted anti-inflammatory and anti-oxidant properties of the members of the *Iris* family, e.g. “Hakim Momen” in his book “tohfat-al-momenin” or Rarity of the faithful, and “Abu Mansour Heravi” in “Al-Abnie Al-Haghayegh Al-Advie” or fundamental facts of herbs (Momen, 2008; Heravi, 1968; Nadaroglu et al., 2007).

*Iris florentina* is a member of the *Iris* family which is abundantly found in Iran as well as India and China. No published paper was found on the effects of *I. florentina* on the wound healing process and skin regeneration parameters (Guo and DiPietro, 2010; Ashkani-Esfahani et al., 2012). In this study, we aimed



to investigate the healing effects of *I. florentina* on excisional full thickness skin wounds using histomorphometrical and stereological methods. For estimating the effect of this herbal medicine on the skin samples, we determined the parameters which were reported to be involved in the healing process such as the amount of fibroblast proliferation, collagen bundle synthesis, hair follicle production, and vascularization and also wound closure rate in laboratory rats.

## Materials and Methods

### Plant collection

The all parts of *I. florentina* were collected from the field of Medicinal Plants Institute-ACECR (Karaj, Iran) and was identified by the Pharmacognosy Department of Tehran University (herbarium code: 76005).

### Preparation of the plant extract and the vehicle

Plant materials, mixture of all plant organs, was dried at room temperature (25°C) for 4–7 days. The dried material was ground into powder and subsequently extracted with a mixture of water: Ethanol (96%) (1:1, v/v) for 72 hours. The obtained material was then filtered and the filtrate was evaporated to obtain a dark hydro-alcoholic extract. In order to facilitate the application of the agent, *I. florentina* was dissolved in Eucerin (Sigma-Aldrich, Germany) for preparing 10% (*I. florentina* group) ointment (w/w). The vehicle was also supplied by using Eucerin ointment without the *I. florentina* component (vehicle-treated group).

### Animal cares and creation of the wounds

Twenty-four female Wistar rats (180 ± 20 g; 2–3 months old) were obtained from the Pasteur Institute (Karaj, Iran). They were housed in clean and standard glass cages maintained at 25 ± 2°C with 12/12 hours light and dark cycle. All the rats were acclimated to the laboratory condition for a week and then randomly divided into different experimental groups. They were fed with standard pelleted diet supplied and water.

According to a pilot study with different concentrations *I. florentina*, 10% ointment was selected for this study. All the rats were randomly divided into three groups (n=8): vehicle-treated group, *I. florentina* 10% ointment treated group, and the untreated control group. In these three groups on the day 0, under general anesthesia, one circular excisional full-thickness skin wounds with 1 cm diameter were created on the dorsal surface of the animal's neck. The treatments were repeated every 24 hours until the last day of the study. The last day of the study was assigned as the day in which at least one of the wounds in any group was closed. The animals were sacrificed by inhalation of high dose of ether in the last day. Full thickness skin samples from the wound sites

with a 1 cm margin were provided and fixed in buffered formaldehyde (pH=7.2) for further procedures.

### Preparation of samples and histomorphometrical study

Histomorphometrical and stereological studies were performed according to a previous method reported earlier (Ashkani-Esfahani et al., 2013; Khoshneviszadeh et al., 2014). To determine the wound closure rate, images were captured from the wound surfaces every three days with a digital camera. To calibrate the magnification, a standard ruler was set at the level of the wound in each photograph, and the wound area at each visit was estimated using a stereology software composed of a point grid, and using the following formula:

$$\text{Area} = \sum P \times a/p$$

where  $\sum P$  was the total points laid on the wound area and  $a/p$ , the area surrounded by every four crosses, was considered as the area per point (mm<sup>2</sup>) (Guo and DiPietro, 2010) (Figure 1)

The wound closure rate was calculated as:

$$\text{Wound closure rate (\%)} = [(\text{area at visit 1} - \text{area at each visit}) / \text{area at visit 1}] \times 100$$

Nine pieces of the skin samples, each about 1 mm<sup>2</sup>, was cut and prepared in a systematic random sampling manner for histomorphometrical and stereological analysis. The pieces of each sample were embedded in a paraffin block. Isotropic uniformly random (IUR) sections of the blocks with 5 and 15 μm thickness was created and stained with Hedenhain's azan-trichrome stain (Khoshneviszadeh et al., 2014; Ashkani-Esfahani et al., 2014). Microscopic analyses of the dermis was performed by using a video-microscopy system made up of a microscope linked to a camera (Alpha-200; Sony™; Japan) and a flat monitor. The volume densities of the collagen bundles, vessels, and hair follicles (V<sub>v</sub>; fraction of the unit volume of the dermis which was occupied by the collagen bundles, vessels, or hair follicles) was estimated by using the stereological point counting method and the following formula:

$$V_v (\text{collagen, vessel, or hair follicle/dermis}) = P (\text{collagen or vessel or hair follicle}) / P (\text{dermis})$$

where P (collagen or vessel or hair follicle) was the number of points hitting the profiles of the collagen bundles, vessels, or hair follicles; P(dermis) was the number of points hitting the reference visible field (dermis)

The numerical density (N<sub>v</sub>; number of cells per unit volume of the dermis) of the fibroblasts was estimated by employing the 15 μm slides, the "optical dissector" method (Ashkani-Esfahani et al., 2013), and the following formula:

$$N_v = \sum Q / \sum A \times h$$

where "∑Q" was the number of nuclei coming into focus in the

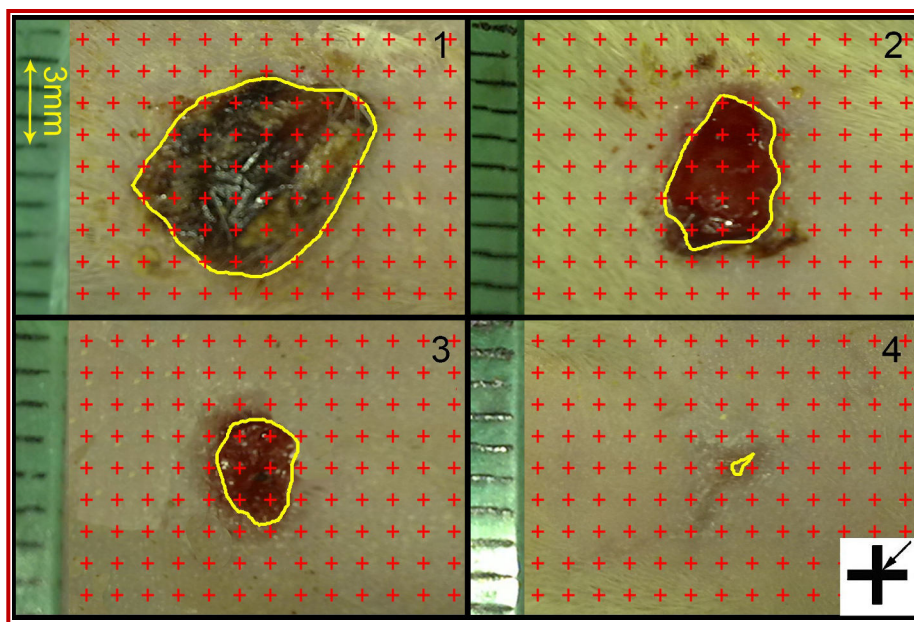


Figure 1: Samples of digital photographs were captured from the wound surfaces every other day to measure the wound area. The total number of points within the wound borders (yellow line) was counted. At the corner of this figure, a cross is presented. The right upper corner of the cross is considered as the point (arrow), and it is counted only if the right upper corner hits the wound surface. (1): day 1, (2): day 4; (3) day 8; (4) day 12

dissector height, “ $\Sigma A$ ” was the total area of the counting frame in all microscopic fields, and “ $h$ ” was the height of the dissector within which the counting is done

The upper and the lower 5  $\mu\text{m}$  were considered as “the area of safety”.

#### Statistical analysis

The data was collected, analyzed, and reported as mean and standard deviation (mean  $\pm$  SD). The statistical comparisons between the groups were carried out by the SPSS statistical software (version 16.0). One-way analysis of variance (ANOVA), Tukey’s post-test, and Mann-Whitney U-test were used to analyze the data. Moreover,  $p=0.05$  was considered as statistically significant.

## Results

The wound closure rate of control and vehicle groups were approximately similar (Figure 2). Based on the results of this study, *I. florentina*-treated group with an average of 7.7% closure per day showed faster wound closure rate in comparison with the control (5.7%/day) and the vehicle-treated (4.9%/day) groups ( $p<0.05$ ).

Numerical density of the fibroblasts (Nv) in the dermis of the *I. florentina* group was higher than that of the control and vehicle groups. The numerical density of the fibroblasts in *I. florentina*-treated group was reported 110% higher than the control group ( $p<0.001$ ) and 118% higher than the vehicle treated group ( $p<0.001$ ) (Table I). The mean of volume density of the collagen bundles

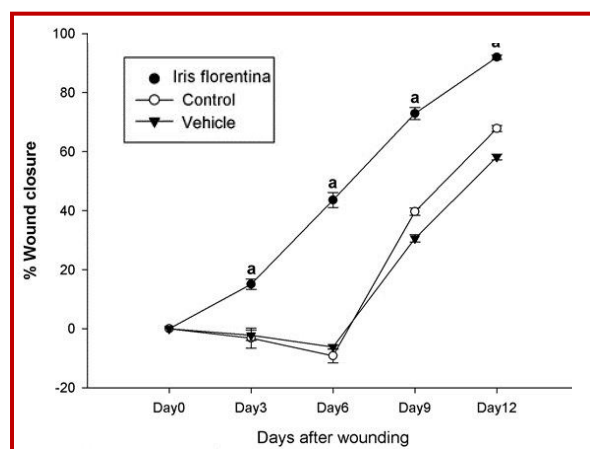


Figure 2: Wound closure rates in the control, IF treated, and vehicle-treated groups. Each point represents mean  $\pm$  SD of the wounds of each group. The wound closure rate had significantly increased in IF treated group compared to the control and vehicle-treated groups ( $p<0.05$ )

was  $79 \pm 7\%$  in *florentina*-treated group which was 62% and 43% higher than the control and the vehicle groups ( $p<0.05$ ), respectively. Vessel’s volume density was  $7.01 \pm 0.4\%$  in *florentina*-treated group, 195% and 115% higher than the control and the vehicle groups ( $p<0.05$ ).

Length density of the vessels was 20.08% in *I. florentina*-treated group that had no significant difference with the other groups. In comparison to the *I. florentina*-treated group, the mean of the vessel diameters was 40% lower in the vehicle group ( $p=0.321$ ) and 158% lower in the control group ( $p=0.048$ ; Table I).

**Table I**  
**Effect of *Iris florentina* on fibroblasts, collagen and vessels in the dermis of the wounded rat**

Groups	Fibroblast ( $\times 10^4$ per $\text{mm}^3$ )	Collagen ( $V_{V_{\text{collagen}}/\text{dermis}}$ , %)	Vessel ( $V_{V_{\text{vessel}}/\text{dermis}}$ , %)		
	Numerical density	Volume density %	Volume density %	Length density (mm/ $\text{mm}^3$ )	Mean diameter ( $\mu\text{m}$ )
Vehicle (Ointment)	17.3 (8.2)	55.4% (5.8%)	3.3% (0.3%)	20.2 (8.1)	2.2 (0.4)
<i>Iris florentina</i> (10%) treated group	37.9 (6.4) <sup>a</sup>	79.7% (7.1%) <sup>b</sup>	7.1% (0.4%) <sup>a</sup>	20.1 (5.5)	3.1 (2.1) <sup>b</sup>
Untreated wound group	18.1 (6.6)	49.1% (5.2%)	2.4% (0.3%)	17.2 (7.3)	1.2 (0.3)

Data are mean (SD); <sup>a</sup> $p < 0.05$ , *Iris Florentina* group vs. control group and vehicle group; <sup>b</sup> $p < 0.05$ , *Iris Florentina* group vs. Control group

## Discussion

In this study, the effects of *I. florentina* were studied on the wound healing process in rats by using stereological parameters; estimating the amount of fibroblasts population, revascularization, and collagen bundle synthesis revealed that topical *I. florentina* hastens skin tissue regeneration.

According to previous investigations, almost all common categories of flavonoids are present in various members of Iridaceae family (Harborne and Williams, 2011). The potential of plant flavonoids and other hydrophilic natural compounds, some of which are found in *I. florentina* as well as xanthenes and isoflavones, for the treatment of various skin disorders and skin injuries, carcinomas, aging, and etc. has been reported in previous studies; moreover, *I. florentina* extract also showed anti-oxidant activity (Hamedi et al., 2013; Modeer et al., 2000; Gangwar et al., 2014; Bahramsoltani et al., 2014). IF is rich in polyphenols, flavonoids and anthocyanins with high anti-oxidant action which is involved in anti-aging properties other than the skin healing effects (Mukherjee et al., 2011; Kumar et al., 2007).

Studies on *Iris germanicain* animal models were found to be a potent anti-inflammatory, antimicrobial and immunomodulatory herb (Ibrahim et al., 2012; Bagheri et al., 2011; Xie et al., 2014; Tundis et al., 2015). In current study, stereological investigation of specimens showed higher rates of granulation tissue formation that improved in treatment group. Anti-inflammatory response in *I. florentina*-treated group was more efficient than vehicle and control groups.

Wound closure rate and re-epithelization in *I. florentina*-treated group were significantly higher than vehicle and control groups. In addition, *I. florentina* significantly stimulatory influence on fibroblast proliferation, collagen bundle synthesis, revascularization and neovascularization which is of considerable prominence. Hence, the observations of this study appear to be

mediated through the anti-oxidant property of *I. florentina* (Bahramsoltani et al., 2014; Mukherjee et al., 2011; Kumar et al., 2007).

## Conclusion

Overall, *I. florentina*, a medicinal herb which is introduced by ancient medicine for various skin problems, specifically skin injuries, and also was evaluated by today's scientific researches, has shown beneficial properties to be prescribed as a natural remedy or an additional treatment for skin wounds.

## Ethical Issue

The animal care and experimental protocols were in accordance with the Principles of Laboratory Animal Care (NIH publication #85-23, revised in 1985) and were approved by the ethics committee for the use of experimental animals at Shiraz University of Medical Sciences, Shiraz, Iran.

## References

- Ashkani-Esfahani S, Emami Y, Esmaeilzadeh E, Bagheri F, Namazi MR, Keshtkar M, Khoshneviszadeh M, Noorafshan A. Silymarin enhanced fibroblast proliferation and tissue regeneration in full thickness skin wounds in rat models: A stereological study. *J Saudi Society Dermatol Dermatol Surg.* 2013; 17: 7-12.
- Ashkani-Esfahani S, Zarifi F, Asgari Q, Samadnejad AZ, Rafiee S, Noorafshan A. Taurine improves the wound healing process in cutaneous leishmaniasis in mice model, based on stereological parameters. *Adv Biomed Res.* 2014; 3: 204.
- Ashkani-Esfahani S, Imanieh M, Khoshneviszadeh M, Meshksar A, Noorafshan A, Geramizadeh B, Ebrahimi S, Handjani F, Tanideh N. The healing effect of arnebia euchroma in second degree burn wounds in rat as an animal model. *Iran Red Crescent Med J.* 2012; 14: 70-74.
- Avicenna. The canon of medicine. Tehran, Soroosh, 1984.

- Bahramsoltani R, Farzaei MH, Rahimi R. Medicinal plants and their natural components as future drugs for the treatment of burn wounds: An integrative review. *Arch Dermatol Res.* 2014; 306: 601-17.
- Bagheri M, Jahromi BM, Mirkhani H, Solhjoui Z, Noorafshan A, Zamani A, Amirghofran Z. Azelnidipine, a new calcium channel blocker, promotes skin wound healing in diabetic rats. *J Surg Res.* 2011; 169: e101-7.
- Gangwar M, Gautam MK, Sharma AK, Tripathi YB, Goel RK, Nath G. Anti-oxidant capacity and radical scavenging effect of polyphenol rich *Malotus philippensis* fruit extract on human erythrocytes: An *in vitro* study. *Scientific World J.* 2014; 2014: 279451.
- Guo S, DiPietro LA. Factors affecting wound healing. *J Dent Res.* 2010; 89: 219-29.
- Hamed A, Zarshenas MM, Sohrabpour M, Zargar A. Herbal medicinal oils in traditional Persian medicine. *Pharm Biol.* 2013; 51: 1208-18.
- Harborne J, Williams C. The phytochemical richness of the Iridaceae and its systematic significance. *Annali di Botanica.* 2011; 58.
- Heravi AM. Al-Abniean Haghayegh al-Advie. Tehran, Tehran University, 1968.
- Ibrahim SR, Mohamed GA, Al-Musayeb NM. New constituents from the rhizomes of Egyptian *Iris germanica* L. *Molecules* 2012; 17: 2587-98.
- Khoshneviszadeh M, Ashkani-Esfahani S, Namazi MR, Noorafshan A, Geramizadeh B, Miri R. Topical simvastatin enhances tissue regeneration in full-thickness skin wounds in rat models. *Iran J Pharm Res.* 2014; 13: 263-9.
- Kumar B, Vijayakumar M, Govindarajan R, Pushpangadan P. Ethnopharmacological approaches to wound healing: Exploring medicinal plants of India. *J Ethnopharmacol.* 2007; 114: 103-13.
- Masson J, Liberto E, Brevard H, Bicchi C, Rubiolo P. A metabolomic approach to quality determination and authentication of raw plant material in the fragrance field. *Iris rhizomes: A case study.* *J Chromatogr A.* 2014; 14: 143-54.
- Mavrodiev EV, Martinez-Azorin M, Dranishnikov P, Crespo MB. At least 23 genera instead of one: The case of *Iris* L. s.l. (Iridaceae). *PLoS One.* 2014; 9: e106459.
- Mosihuzzman M, Naheed S, Hareem S, Talib S, Abbas G, Khan SN, Choudhary MI, Sener B, Tareen RB, Israr M. Studies on alpha-glucosidase inhibition and anti-glycation potential of *Iris loczyi* and *Iris unguicularis*. *Life Sci.* 2013; 92: 187-92.
- Mukherjee PK, Maity N, Nema NK, Sarkar BK. Bioactive compounds from natural resources against skin aging. *Phytomedicine* 2011; 19: 64-73.
- Momen H. Tohfat-al-momenin. Tehran, Nashre-Shahr Institution, 2008.
- Manning J, Goldblatt P. The *Iris* family: Natural history and classification. Portland, Oregon, Timber Press, 2008. pp 200-04.
- Moder T, Domeij H, Anduren I, Mustafa M, Brunius G. Effect of phenytoin on the production of interleukin-6 and interleukin-8 in human gingival fibroblasts. *J Oral Pathol Med.* 2000; 29: 491-99.
- Nadaroglu H, Demir Y, Demir N. Anti-oxidant and radical scavenging properties of *Iris germanica*. *Pharmaceut Chem J.* 2007; 41: 409-15.
- Tundis R, Loizzo MR, Bonesi M, Menichini F. Potential role of natural compounds against skin aging. *Curr Med Chem.* 2015; 22: 1515-38.
- Xie GY, Zhu Y, Shu P, Qin XY, Wu G, Wang Q, Qin MJ. Phenolic metabolite profiles and anti-oxidants assay of three Iridaceae medicinal plants for traditional Chinese medicine "She-gan" by on-line HPLC-DAD coupled with chemiluminescence (CL) and ESI-Q-TOF-MS/MS. *J Pharm Biomed Anal.* 2014; 98: 40-51.
- Zarshenas MM, Mehdizadeh A, Zargar A, Mohagheghzadeh A. Rhazes (865-925 AD). *J Neurol.* 2012; 259: 1001-02.

**Author Info**

Ehsan Jangholi (Principal contact)

e-mail: ehsanjangholi@gmj.ir

## **Your feedback about this paper**

1. Number of times you have read this paper

2. Quality of paper

3. Your comments