



BJP

Bangladesh Journal of Pharmacology

Research Article

**Cardioprotective activity of fruit
of *Garcinia pedunculata* on iso-
prenaline-induced myocardial
infarction in rat**

Cardioprotective activity of fruit of *Garcinia pedunculata* on isoprenaline-induced myocardial infarction in rat

Ravi Mundugaru¹, Padmaja Udaykumar², Sivanesan Senthilkumar³ and Sudhakara Bhat¹

¹Department of Pharmacology and Toxicology, SDM Centre for Research in Ayurveda and Allied Sciences, Udipi 574 118, India; ²Department of Pharmacology Father Muller Medical College, Mangalore 575 002, India; ³Department of Research and Development, Saveetha University, Thandalam, Chennai 602 105, India.

Article Info

Received: 9 September 2015
Accepted: 1 January 2016
Available Online: 25 January 2016
DOI: 10.3329/bjp.v11i1.24941

Cite this article:

Mundugaru R, Udaykumar P, Senthilkumar S, Sudhakara. Cardioprotective activity of fruits of *Garcinia pedunculata* on isoprenaline induced myocardial infarction in albino rats. Bangladesh J Pharmacol. 2016; 11: 231-35.

Abstract

The present study reveals the protective effect of *Garcinia pedunculata* aqueous fruit extract in isoprenaline-induced myocardial infarction in Wistar rats. Isoprenaline (200 mg/kg) administration subcutaneous once daily for two consecutive days significantly ($p < 0.01$) increased the CK-MB, AST, ALT, ALP activity and CRP ($p < 0.05$) levels. Pretreatment with extract (400 mg/kg) orally for 14 consecutive days significantly ameliorated the effect of isoprenaline by reducing the activity of CK-MB and the levels of ALP, SGPT respectively. No significant changes were seen in the case of SGOT activity and CRP levels. Severe necrotic lesions in the myocardial tissue were observed in the isoprenaline-treated group. In extract-treated group, mild degenerative changes of myocardial tissues to nearly normal cytoarchitecture were seen. The results indicate the cardioprotective effect of *G. pedunculata* against isoprenaline-induced myocardial infarction rat model.

Introduction

Myocardial infarction is the acute ischemic condition where profound necrosis of myocardial tissue occurs. This mainly results of imbalance between coronary blood supply and myocardial oxygen demand (de Bono et al., 1992). Isoprenaline is a synthetic catecholamine acts as a β adrenergic agonist. It has been reported to produce myocardial infarction in higher dose (Jordan et al., 1999; Panda and Naik, 2009). Isoprenaline undergoes auto-oxidation and generate highly cytotoxic free radicals. These free radicals stimulate per-oxidation of membrane phospholipids causing severe damage to myocardial membrane. Subsequently, the inflammation event takes place with infiltration of neutrophils into the infarcted area where it can promote myocardial cell damage through the release of proteolytic enzymes. It intern produces cytotoxic reactive oxygen species (Kannan and Quine, 2013). Thus, the model is used as a novel method to produce myocardial infarction in experimental animals.

Amlavetasa *Garcinia pedunculata* is a medicinal herb that belongs to the family Clusiaceae. Tribal people of Assam region were widely using the dried fruits of the plant as cardi tonic along with their diet (Comalada et al., 2005). It has been reported that the dried fruits of GP are used for asthma, cough, bronchitis and fever (Jayaprakasha et al., 2006). The phytochemical analysis has shown the dried fruit rinds and pericarp contains (-) hydroxy citric acid, benzophenones, pedunculol, garcinol and cambogin (Kagyung et al., 2010). It has been screened for its anti-inflammatory, *in vitro* anti-oxidant and hepatoprotective activity (Patiri and Borah, 2007; Ravi Mundugaru et al., 2014). At present, there is an increased attention on phytochemicals and polyphenols such as alkaloids, flavonoids, xanthenes derived from different plant species. These chemicals possess excellent anti-oxidant properties and have potential therapeutic values in prevention and management of cardiovascular disease (Sahu et al., 1989).

As there is no documented experimental basis for its



use as a cardioprotective activity, the present study has been carried out to elucidate cardioprotective activity of aqueous extract of *G. pedunculata* in isoprenaline-induced myocardial infarction model.

Materials and Methods

Plant material and extract preparation

Fruits of *G. pedunculata* were collected from Assam region, India with the help of a botanist during March of 2012. It was authenticated in Pharmacognosy Laboratory, SDM Centre for Research in Ayurveda and Allied Sciences, Udupi. The voucher specimen (No. 13100501) has been deposited for further future reference. The powder of fruits of *G. pedunculata* was prepared in the Pharmacy attached to SDM College Ayurveda, Udupi, from authenticated plant material. The powder obtained from a single batch was used throughout the experimental study. Two fifty grams of the fruit powder of *G. pedunculata* was soaked in 2L of distilled water for 24 hours; it was filtered and concentrated in a water bath. The concentrated extract of *G. pedunculata* was used for the isoprenaline-induced cardioprotective activity.

Experimental animals

Male Wistar albino rats weighing 180-220 g were obtained from animal house attached to SDM Centre for Research in Ayurveda and Allied Sciences, Udupi. They were fed with standard diet and water *ad libitum*. The animals were housed in a controlled environment with 12:12 hours light and dark cycle, temperature of 25°C and relative humidity 50%. The experimental animals were acclimatized for two weeks in the laboratory condition before the experiment. The experiments were carried out in accordance with the guidelines of institutional ethical committee under the reference number SDMCRA/IAEC/2012-13DGM 03ab.

Chemicals

Isoprenaline was purchased from Sigma Chemicals USA (product code- 101128695).

Acute oral toxicity test

The acute oral toxicity study was carried out as per OECD guidelines 425 using AOT software. The aqueous extract of fruits of *G. pedunculata* was made into a suspension in 0.5% gum acacia and dosed in the following order 175, 550 and 2000 mg/kg body weight. After the dosing, the animals were observed for 14 days for mortality. The LD₅₀ was determined by using AOT software.

Induction of myocardial infarction

Isoprenaline was dissolved in normal saline and injected subcutaneously at a dose of 200 mg/kg body

weight once daily for 2-consecutive days (Priscilla and Prince, 2009; Kumaran and Prince, 2010).

Experimental design

Rats were randomly divided into three groups of six rats each. Group I received 0.5% gum acacia for 14 consecutive days and served as normal control group. Group II rats received 0.5% gum acacia for 14 consecutive days and in addition received isoprenaline 200 mg/kg, subcutaneously at an interval of 24 hours. Group III rats were pre-treated with 400 mg/kg of extract for a period of 14 consecutive days and in addition received isoprenaline 200 mg/kg, subcutaneously on 14th and 15th day at an interval of 24 hours.

Twenty-four hours after the last dose of isoprenaline, animals were anesthetized and blood samples were collected from retro-orbital puncture for estimation of biochemical parameters such as CK-MB in serum was that was determined using CK-MB diagnostic kit and CRP was measured using a specific immunoassay kit (Immunospec Corporation, USA). The serum biochemical markers such as AST, ALT and ALP measured according to standard methods (Bradly et al., 1972; Wilkinson et al., 1969). Rats were then sacrificed under deep anesthesia and the heart was rapidly isolated washed with ice-cold saline. The tissue was then transferred to 10% formalin for histological examination. The tissue was embedded in paraffin. The section was cut at 5 µm thickness and stained with hematoxyline-eosin stain and mounted in diphenyl xylene. The histopathological changes of heart tissue were observed under a compound microscope and their micro-photographs were taken (Bancroft and Gamble, 2002).

Statistical analysis

The experimental data were expressed as mean ± SEM. Statistical analysis was carried out by one-way analysis of variance followed by Dennett multiple t-test. A level for p<0.05 was considered to be statistically significant.

Results

In acute oral toxicity study in any dose up to 2,000 mg/kg of aqueous extract of fruits of the plant *G. pedunculata* did not produce any mortality. This indicates that LD₅₀ is much more than 2,000 mg/kg and hence 1/5th of the dose was selected for the present cardioprotective study.

A significant elevation in the serum CK-MB, SGOT, SGPT, ALP activity and C-reactive protein levels were observed in isoprenaline-treated myocardial infarcted rats as compared to Group I control rats (Table I). The extract pre-treated group significantly reduced the activity of serum biomarkers such as CK-MB, SGPT and ALP and caused mild to moderated reduction of SGOT

Table I
Effects of fruit extract of *G. pedunculata* on biochemical parameters

Group	Dose	Serum SGOT (IU/dL)	Serum SGPT (IU/dL)	Serum ALP (IU/dL)	Serum CRP (mg/L)	CK-MB (U/L)
Normal control	5 mL/kg	130.0 ± 6.8	40.7 ± 4.4	185.0 ± 21.1	0.7 ± 0.0	79.0 ± 5.5
Isoprenaline control	200 mg/kg	252.8 ± 13.3 ^a	262.7 ± 39.4 ^a	483.2 ± 43.4 ^a	1.2 ± 0.2 ^a	325.0 ± 48.7 ^a
Extract + Isoprenaline	400 mg/kg	248.6 ± 23.0	107.0 ± 8.7 ^b	254.7 ± 36.2 ^b	0.9 ± 0.1	92.0 ± 2.5 ^b

Data expressed in Mean ± SEM, ^ap<0.01 in comparison to normal control group, ^bp<0.01 in comparison to isoprenaline control

activity and CRP levels in serum (Table I).

Histological examination of heart tissue

Microscopic examination of the section of heart from different groups was carried out to assess the impact of isoprenaline injection on cardiac cytoarchitecture and its modulation by test drug administration.

Sections of heart from normal control rats exhibited normal cytoarchitecture. The myofibrillar structure was normal with striations, branching and continuity with adjacent myofibrils.

Examination of sections of heart from isoprenaline group exhibited remarkable changes in the cytoarchitecture. In most of the rats moderate to severe necrotic lesions were found especially in the apical region. The basal region was not affected to great extent. In the area surrounding this region myocarditis, interstitial edema and focal cell infiltration were observed. Loss of myocardial fibres was observed in some areas. Hemorrhage and fatty changes were observed in some sections. Severe necrotic lesions were observed in all the rats in this group (Figure 1).

In *G. pedunculata* extract-treated isoprenaline injected group, the severity of the degenerative changes was found to be moderate and less in comparison to the control isoprenaline group. Moderate necrosis with cell infiltration was observed in sections from two rats. Mild to moderate necrosis and degenerative changes in the form myocarditis and fatty changes were observed in sections from the remaining rats.

Discussion

In the present study, there is a significant elevation in serum CK-MB, ALT, AST and ALP levels in isoprenaline treated group. Pre-treatment with *G. pedunculata* extract for 14 days showed a marked decrease in the elevated serum biomarkers. This suggests the test drug has the potential to inhibit free radical generation and subsequent cell damage. The earlier report suggests that the test drug has strong anti-oxidant potential. This might be the possible mechanism of the protective outcome of the present study.

Subsequently after myocardial infarction caused by

isoprenaline inflammatory process involved in the myocardial tissue damage and cellular necrosis. It is reported that the infarcted area undergoes local necrosis and myocyte apoptosis resulting in complementary activation, free radical generation and accumulation of cellular debris. This is followed by infiltration of neutrophils and macrophages into the infarcted area, where they can promote myocardial cell damage by release of proteolytic enzymes and cytokines. Pre-treatment with extract showed a marked decrease in the serum levels of CRP. It is also reported that extract has good anti-inflammatory activity (Ravi Mundugaru et al., 2014).

Histological examination of sections of heart from isoprenaline treated group exhibited remarkable changes in the cytoarchitecture. In most of the rats moderate to severe necrotic lesions were found especially in the apical region than basal. In the area surrounding this region myocarditis interstitial edema, focal cell infiltration, hemorrhages and fatty changes were observed. Extract-treated group showed maximum protective effect by reduced histological changes as compared to isoprenaline-treated myocardial infarcted rats.

Conclusion

Aqueous extract of fruits of *G. pedunculata* protected experimentally induced myocardial infarction in rats as revealed by the amelioration of histological changes and biochemical and inflammatory markers of cardiac tissue damage.

Acknowledgement

Authors are highly grateful to revered President Dr. D. Veerendra Heggade for the constant support, and Dr. B. Yashoverma, Secretary, SDM Educational Society for the guidance. We thank the Registrar, Research Director and Dean, Saveetha University, Chennai for their constant motivation to carry out the research activities.

References

Bradly DW, Maynard JE, Emery G, Webster H. Transaminase activities in serum of long-term hemodialysis patients. Clin

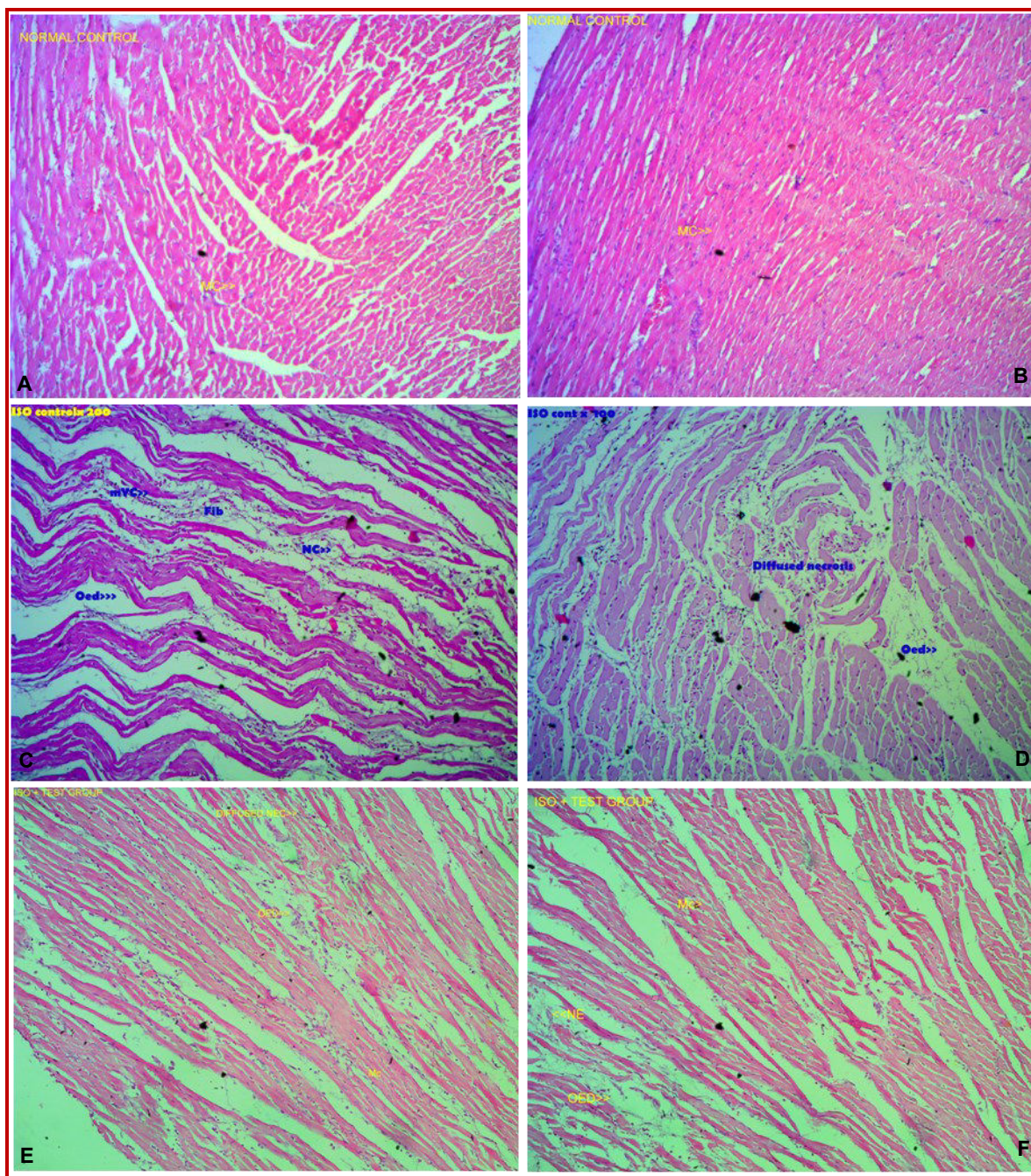


Figure 1 (A, B): Photomicrographs of representative heart sections from normal control group treated with gum acacia shows normal cytoarchitecture. Myocardium (MC); (C, D): Photomicrographs of representative heart sections from isoprenaline group shows moderate to severe necrotic lesions (NC), myocarditis interstitial edema (Oed), focal cell infiltration (Fc), hemorrhages (Hg) and fatty changes were observed; (E, F): Photomicrographs of representative heart sections from test drug + Isoprenaline injected rats shows mild moderate necrotic lesions (NEC) and myocardial interstitial edema (Oed). The test drug showed a maximum protective effect by reduced histological changes

Chem. 1972; 18: 1442.

Bancroft JD, Gamble M. Theory and practice of histological techniques. 5th ed. Churchill Livingstone, 2002.

Comalada M, Camuesco D, Sierra S, Ballester I, Xaus J, Galvez J, et al. *In vivo* quercitrin anti-inflammatory effect involves

release of quercetin, which inhibits inflammation through down-regulation of the NF-kappa B pathway. *Eur J Immunol.* 2005; 35: 584-92.

Cusack MR, Marber MS, Lambiase PD, Bucknall CA, Redwood SR. Systemic inflammation in unstable angina is the result of myocardial necrosis. *J Am Coll Cardiol.* 2002; 39: 1917-23.

- de Bono DP, Simoons ML, Tijssen J, Arnold AE, Betriu A, Burgersdijk C, et al. Effect of early intravenous heparin on coronary patency, infarct size, and bleeding complications after alteplase thrombolysis: Results of a randomised double blind European Cooperative Study Group Trial. *Br Heart J*. 1992; 67: 122-28.
- Jordan JE, Zhao ZQ, Vinten-Johansen J. The role of neutrophils in myocardial ischemia-reperfusion injury. *Cardiovasc Res*. 1999; 43: 860-78.
- Kannan MM, Quine SD. Ellagic acid inhibits cardiac arrhythmias, hypertrophy and hyperlipidaemia during myocardial infarction in rats. *Metabolism* 2013; 62: 52-61.
- Jayaprakasha GK, Negi PS, Jena BS. Anti-oxidative and anti-mutagenic activities of the extracts from the rinds of *Garcinia pedunculata*. *Innov Food Sci Emerg Technol*. 2006; 7: 246-50.
- Kagyung R, Gajurel PR, Rethy P, Singh B. Ethnomedicinal plants used for gastrointestinal diseases by *Adi* tribes of Dehang-Debang biosphere reserve in Arunachal Pradesh. *Indian J Tradit Knowl*. 2010; 9: 496-501.
- Kumaran KS, Prince PS. Caffeic acid protects rat heart mitochondria against isoproterenol-induced oxidative damage. *Cell Stress Chaperon*. 2010; 15: 791-806.
- Patiri B, Borah A. Wild edible plants of Assam. 1st ed. Assam, The Director Forest Communication, Forest Department, Assam, 2007.
- Panda VS, Naik SR. Evaluation of cardioprotective activity of *Ginkgo biloba* and *Ocimum sanctum* in rodents. *Altern Med Rev*. 2009; 14: 161-71.
- Priscilla DH, Prince PS. Cardioprotective effect of gallic acid on cardiac troponin-T, cardiac marker enzymes, lipid peroxidation products and anti-oxidants experimentally induced myocardial infarction in Wistar rats. *Chem Biol Interact*. 2009; 179: 118-24.
- Ravi Mundugaru, Febin Joy, Shrinidhi R, Lipika Das, Sudhakar, Ravishankar B. Anti-inflammatory activity of aqueous extract of fruits of *Garcinia pedunculata* in experimental animals. *Am J Pharma Tech Res*. 2014; 4; 3.
- Rathore N, Kale M, John S, Bhatnagar D. Lipid per-oxidation and anti-oxidant enzymes in isoproterenol-induced oxidative stress in rat erythrocytes. *Indian J Physiol Pharmacol*. 2000; 44: 161-66.
- Sahu A, Das B, Chatterjee A. Polyisoprenylated benzophenones from *Garcinia pedunculata*. *Phytochemistry* 1989; 28: 1233-35.
- Wilkinson J H, Boutwell J H, Winsten S. Evaluation of a new system for kinetic measurement of serum alkaline phosphatase. *Clin Chem*. 1969; 15: 487-95.

Author Info

Ravi Mundugaru (Principal contact)
e-mail: ravisdm13@gmail.com

Your feedback about this paper

1. Number of times you have read this paper

2. Quality of paper

3. Your comments