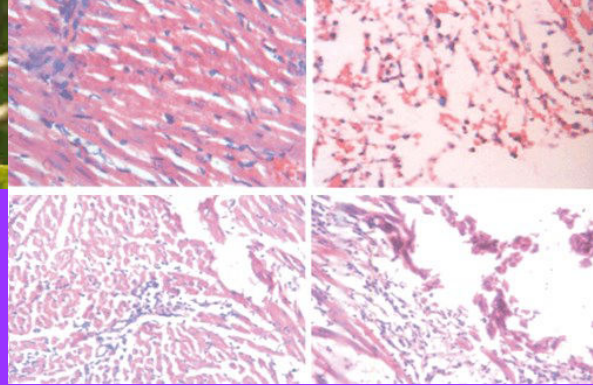

BJP

Bangladesh Journal of Pharmacology

Research Article

Cardioprotective effect of *Erythrina stricta* leaves on isoproterenol-induced myocardial infarction in rat

Cardioprotective effect of *Erythrina stricta* leaves on isoproterenol-induced myocardial infarction in rat

Asokkumar Kuppusamy, Subhadradevi Varadharajan, Christy Josey, Honey John, Daphne Sherin, Divia Chirakkan and Gokul Athiyappan

Department of Pharmacology, College of Pharmacy, Sri Ramakrishna Institute of Paramedical Sciences, Coimbatore 641 044, Tamil Nadu, India.

Article Info

Received: 25 November 2009

Accepted: 24 February 2010

Available Online: 3 March 2010

DOI: 10.3329/bjp.v5i1.3809

Cite this article:

Kuppusamy A, Varadharajan S, Josey C, John H, Sherin D, Chirakkan D, Athiyappan G. Cardioprotective effect of *Erythrina stricta* leaves on isoproterenol-induced myocardial infarction in rat. Bangladesh J Pharmacol. 2010; 5: 1-4

Abstract

The cardioprotective activity of *Erythrina stricta* leaves against isoproterenol-induced myocardial infarction in rats was studied. Rats were pretreated with leaf extract (200 mg/kg body weight, orally) daily for 28 days. After treatment, isoproterenol (8.5 mg/kg body weight) was injected to rats at an interval of 24 hours for two days to induce myocardial injury. Cardioprotection was investigated by estimating the activities of serum aminotransferase, lactate dehydrogenase and creatinine kinase. Anti-oxidant enzymes such as superoxide dismutase, catalase, glutathione peroxidase, reduced glutathione and thiobarbituric acid reactive substances were determined. The activities of serum marker enzymes were increased significantly ($p < 0.05$) in isoproterenol-induced rats. *E. stricta* extract pretreated rat showed a decrease in serum enzyme levels and increase of anti-oxidant status. The results were confirmed by histopathological evidences. The present study concludes that *E. stricta* extract has a prophylactic value in myocardial infarction.

Introduction

Acute myocardial infarction occurs when the blood supply to a part of the heart is interrupted. It is the leading cause of death all over the world. Isoproterenol-induced myocardial necrosis is a well established standard model to study the beneficial effect of drugs on cardiac dysfunction (Uma et al., 2008). Isoproterenol causes severe stress in myocardium and necrotic lesion in heart muscle. Loss of function and integrity of myocardial membranes are the outcomes of isoproterenol-induced myocardial injury involving change in membrane permeability alterations (Thippeswamy et al., 2009).

Erythrina stricta Roxb. (Papilionaceae), a medium sized deciduous tree used for various ailments in Indian system of medicine. The fresh juice of leaves used for

the relief of earaches, toothaches, pain in joints, dysentery and antidote for snake bite. The plant contains alkaloids and non-alkaloidal constituents (Chopra, 1992). The leaves of the plant are found to possess rich anti-oxidant activity (Asokkumar et al., 2008). The present study was designed to evaluate the cardioprotective effect of ethanol extract of *E. stricta* leaves in isoproterenol-induced biochemical and histopathological changes using rats.

Materials and Methods

Chemicals

Isoproterenol hydrochloride was procured from Samarth Life Science Pvt. Ltd, reduced glutathione and thiobarbituric acid from Himedia Laboratories Pvt. Ltd,



adrenaline tartarate and tocopherol from S.D. Fine Chemicals Ltd. All chemicals were of analytical grade.

Animals

Wistar albino rats of either sex (150-200 g) were selected for the study. The animals were acclimatized to laboratory conditions for 5 days prior to experiments. They were housed in polypropylene cages and water *ad libitum*. The experimental protocol has been approved by the Institutional Animal Ethical Committee.

Plant material

The leaves of *E. stricta* were obtained from Kerala, India. The plant was authenticated by Mr. G.V.S. Murthy, Botanical Survey of India, Tamil Nadu Agricultural University Campus, Coimbatore and voucher specimen of the plant was kept in the college herbarium.

Plant extraction

E. stricta was shade dried and coarse powdered material (40 g) was extracted exhaustively with ethanol in a soxhlet apparatus. The extract was concentrated to a small volume using flash evaporator and further evaporated to dryness in a vacuum desiccator. The extracts obtained were in the form of thick paste due to the presence of resinous matter. Until the time of use the extract was stored in refrigerator. The yield of the extract was found to be 12% (w/w).

Acute toxicity study

Wistar albino rats (150-200 g) maintained under standard laboratory conditions was used. A total of five animals were used which received a single oral dose (2,000 mg/kg, body weight) of the extract. Animals were kept overnight fasting prior to drug administration. After the administration of the extract, food was withheld for further 3-4 hours. Animals were observed individually at least once during the first 30 min after dosing, periodically during the first 24 hours (with special attention during the first 4 hours) and daily thereafter for a period of 14 days.

Experimental protocol

Rats were divided into four groups of 6 animals each. Group I (control) rats were treated with 2% Tween 80 in water (10 mL/kg body weight, orally). Group II rats were treated with isoproterenol in 2% Tween 80 (10 mL/kg body weight orally). Group III rats were treated with *E. stricta* leaf extract (200 mg/kg body weight, orally) and Group IV rats were treated with α -tocopherol (60 mg/kg body weight, orally). On 28th day, myocardial injury was induced to rats in Group II-IV by injection of isoproterenol (8.5 mg/kg body weight, subcutaneously) twice at an interval of 24 hours while normal control rats were given an equivalent volume of the vehicle (Prabhu et al., 2006; Rajadurai and Prince, 2005).

On completion of the experimental protocol, blood samples were collected by the retro-orbital plexus puncture method under light ether anesthesia and serum was separated by centrifugation and used for the biochemical estimations. The levels of creatine kinase, lactate dehydrogenase, serum glutamate oxaloacetate transaminase and uric acid were estimated.

Biochemical analysis

The activities of creatine kinase (CK), lactate dehydrogenase (LDH), and aminotransferase (AST) in serum were determined spectrophotometrically and the absorbance was measured at 340 nm and enzyme activity was expressed as U/L. Serum uric acid was measured at 546 nm. Animals were euthanized by phenobarbitone and hearts were removed, weighed and homogenized. The clear supernatant was used for estimation of endogenous anti-oxidant enzymes such as superoxide dismutase (SOD), catalase (CAT), glutathione peroxidase (Gpx), reduced glutathione (GSH) and thiobarbituric acid reactive substances (TBARS) by spectrophotometer (Budhwar and Kumar, 2005; Pari and Latha, 2004; Karthikeyan et al., 2003).

Histopathological studies

At the end of the study, all the rats were sacrificed by cervical decapitation and the hearts were dissected out, washed in ice cold saline. Then myocardial tissue was immediately fixed in 10% buffered neutral formalin solution. After fixation, tissues were embedded in paraffin and serial sections were cut and each section was stained with hematoxylin and eosin. The slides were examined under light microscope and photographs were taken.

Statistical analysis

Values are expressed as mean \pm standard error mean (SEM) and analyzed using statistical package for social sciences (SPSS) version 10.0 using ANOVA followed by Dunnett's test. P values <0.05 were considered significant.

Results and Discussion

In acute toxicity study, it was found that the animals were safe up to a maximum dose of 2,000 mg/kg body weight. There were no changes in normal behavioral pattern and no signs and symptoms of toxicity and mortality were observed.

Isoproterenol-treated rats (Group II) exhibited significantly higher levels of serum myocardial injury marker enzymes such as serum CK, LDH and AST, uric acid levels when compared to control (Group I; Table I). Rat treated with *E. stricta* leaf extract (200 mg/kg) and α -tocopherol (60 mg/kg) resulted in a significant decrease in those enzymes and levels of uric acid. The results

Table I

Effect of *Erythrina stricta* leaf extract and α -tocopherol on the serum levels of CK, LDH, AST and uric acid in isoproterenol-induced myocardial infarction in rats

Group	CK (U/L)	LDH (U/L)	AST (U/L)	Uric acid (mg/dL)
I (Control)	1414.7 \pm 28.0	1544.2 \pm 128.4	2063.0 \pm 24.4	1.1 \pm 0.1
II (Isoproterenol)	5043.2 \pm 78.7 ^a	11616.8 \pm 253.9 ^a	2467.8 \pm 12.7 ^b	2.1 \pm 0.2 ^b
III (extract 200 mg/kg + Isoproterenol)	1308.1 \pm 5.6 ^a	1965.4 \pm 128.5 ^a	1926.7 \pm 265.6 ^b	1.8 \pm 0.9 ^b
IV (α -tocopherol + Isoproterenol)	1373.1 \pm 138.2 ^b	9014.2 \pm 44.5 ^b	1973.9 \pm 16.2 ^b	1.3 \pm 0.0 ^b

Values are expressed as mean \pm SEM, n = 6 animals each; Group II was compared with Group I, III, and IV; ^ap<0.01, ^bp<0.05

Table II

Effect of *Erythrina stricta* leaf extract and α -tocopherol on the levels of CAT, GPx, SOD, GSH and TBARS in heart of rats in isoproterenol-induced myocardial infarction

Group	CAT (units/mg liver protein)	GPx (units/mg liver protein)	SOD (units/mg liver protein)	GSH (units/mg liver protein)	TBARS (formed/mg liver protein)
I (Control)	0.1 \pm 0.0	2.2 \pm 0.3	2.6 \pm 0.22	3.8 \pm 0.1	2.1 \pm 0.4
II (Isoproterenol)	0.0 \pm 0.0 ^b	0.1 \pm 0.0 ^a	0.1 \pm 0.0 ^a	0.2 \pm 0.0 ^a	4.0 \pm 0.4 ^a
III (extract 200 mg/kg + Isoproterenol)	0.0 \pm 0.0 ^b	0.8 \pm 0.2 ^b	1.0 \pm 0.0 ^a	0.6 \pm 0.1 ^a	0.6 \pm 0.1 ^a
IV (α -tocopherol + Isoproterenol)	0.1 \pm 0.0 ^a	2.2 \pm 0.1 ^a	2.0 \pm 0.0 ^a	2.2 \pm 0.1 ^a	0.6 \pm 0.1 ^a

Values are expressed as mean \pm SEM, n = 6 animals each; Group II was compared with Group I, III, and IV; ^ap<0.01, ^bp<0.05

indicate that *E. stricta* leaf extract has the tendency to reduce the elevated cardiac marker enzymes proving its cardioprotective effect.

SOD and CAT are considered as primary enzymes since they are involved in the direct elimination of ROS. GSH also function as free radical scavenger in the repair of free radical induced biological damage. Decrease of these enzymes denotes the myocardial damage imposed by isoproterenol (Halliwell and Gutteridge,

1985, Misra and Fridovich, 1972). The level of these anti-oxidant enzymes such as CAT, GPx and SOD were found to be decreased after isoproterenol-induced myocardial infarction when compared with control (Table II). Rats pretreated with *E. stricta* leaf extract and α -tocopherol resulted in a significant elevation of the anti-oxidant enzymes in heart tissue. The level of GSH was found to be reduced in myocardial infarcted rats. The rats treated with the extract and α -tocopherol showed an increase in levels of GSH when compared with isoproterenol-treated group and the results were found to be significant (p<0.01, p<0.05). The catecholamine-induced cardiotoxicity is due to the formation of free radicals and its oxidation products. Free radicals promoted lipid peroxidation by increasing membrane permeability ultimately leading to the development of MI (Trivedi et al., 2006).

In the present study, α -tocopherol was used as standard as it protects the myocardial membrane against the free radical damage by nature of its anti-oxidant ability (Velavan et al., 2009).

A significant elevation of tissue TBARS level was seen in isoproterenol-treated group. Administration of *E. stricta* leaf extract and α -toco-pherol for 28 days resulted in a significant reduction in TBARS and the levels were almost similar to normal control rats. It is well known that isoproterenol produces free radicals and these free radicals are involved in membrane damage, leading to elevated levels of TBARS (Ohkawa et al., 1979; Muralidharan et al., 2008). Treatment with *E. stricta* and α -tocopherol in isoproterenol-treated rats decreased the levels of TBARS and this action may be

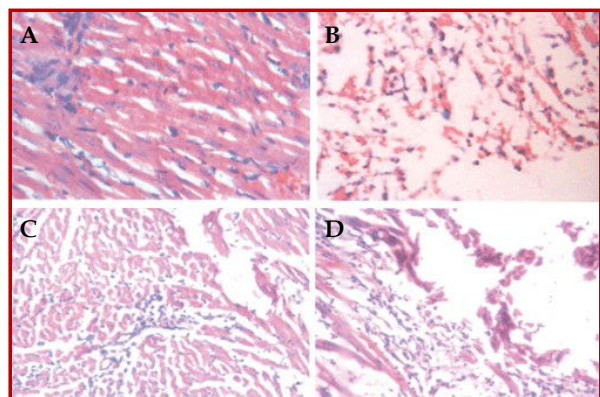


Figure 1: Photomicrographs of heart sections of rat stained with hematoxylin and eosin. A) Normal rats (Group I) showing normal myocardial fibers and muscle bundles with normal architecture. B) Isoproterenol-treated rats (Group II) showing subendocardial infarction, atrophy, more diffuse eosinophilia, edema and myocardial contraction band with vascular changes. C) *Erythrina stricta* leaf extract 200 mg/kg body weight treated rats (Group III) showing lesser necrosis and damage with normal architecture. D) Alphanatocopherol-treated rats (Group IV) showing lesser focal myocarditis

probably due suppression of membrane damage and reduction in membrane fluidity.

Histopathological examination of heart tissue of control rats showed normal myocardial fibers and muscle bundles with normal architecture (Figure 1). Rats, which received isoproterenol alone, showed subendocardial infarction, atrophy, more diffuse eosinophilia, edema and myocardial contraction band with vascular changes. Light microscopy of the tissue sections of Group III showed lesser necrosis and damage with normal architecture. Myocardial section of Group IV rats showed lesser focal myocarditis. Myocardial necrosis and separation of myocardial fibers with inflammatory mononuclear infiltrate noticed after isoproterenol administration was cured after the rats were pretreated with *E. stricta* leaf extract and α -tocopherol. This action produced by the extract reflects the protection offered during myocardial infarction.

Conclusion

Ethanol extract of *E. stricta* exerts cardioprotective effect in isoproterenol-induced myonecrosis in rats and further research to purify and identify the bioactive compounds responsible for the cardioprotection and anti-oxidative actions are under progress.

References

- Asokkumar K, Umamaheswari M, Sivashanmugam AT, Subhadradevi V, Subhashini N, Ravi TK. Anti-oxidant activities of *Erythrina stricta* Roxb. using various *in vitro* and *ex vivo* models. *Oriental Pharm Exp Med*. 2008; 8: 266-78.
- Budhwar R, Kumar S. Prevention of chromate-induced oxidative stress by alpha-lipoic acid. *Indian J Exp Biol*. 2005; 43: 531-35.
- Chopra RN. Council of scientific and industrial research: Glossary of Indian medicinal plants with active principles. 2nd ed. CSIR, New Delhi, Publication and information directorate, 1992, pp 1398-403.
- Halliwell B, Gutteridge JMC. Free radicals and toxicology. In: *Free radicals in biology and medicine*. 3rd ed. Oxford, Oxford University Press, 1985, pp 1-27.
- Karthikeyan K, Bari BRS, Gautham K, Satish KS, Devaraj NS. Cardioprotective effects of the alcoholic extract of *Terminalia arjuna* bark in an *in vivo* model of myocardial ischemic reperfusion injury. *Life Sci*. 2003; 73: 27-39.
- Misra HP, Fridovich I. The role of superoxide anion in the auto oxidation of epinephrine and simple assay for superoxide dismutase. *J Biol Chem*. 1972; 247: 3170-75.
- Muralidharan P, Balamurugan G, Kumar P. Inotropic and cardioprotective effects of *Daucus carota* Linn on isoproterenol-induced myocardial infarction. *Bangladesh J Pharmacol*. 2008; 3: 74-79
- Ohkawa H, Ohishi N, Yagi K. Assay for lipid peroxides in animal tissues by thiobarbituric acid reaction. *Anal Biochem*. 1979; 95: 351-58.
- Prabhu S, Jainu M, Sabitha KE, Devi CSS. Cardioprotective effect of mangiferin on isoproterenol-induced myocardial infarction in rats. *Indian J Exp Biol*. 2006; 44: 209-15.
- Pari L, Latha M. Protective role of *Scoparia dulcis* plant extract on brain anti-oxidant status and lipid peroxidation in STZ diabetic male Wistar rats. *BMC Complement Altern Med*. 2004; 4: 1-8.
- Rajadurai M, Prince PSM. Comparative effect of Aegle marmelos extract and alpha-tocopherol on serum lipids, lipid peroxides and cardiac enzyme levels in rats with isoproterenol-induced myocardial infarction. *Singapore Med J*. 2005; 46: 78-81.
- Thippeswamy BS, Thakker SP, Tubachi S, Kalyani GA, Netra MK, Patil U, Desai S, Gavimath CC, Veerapur VP. Cardioprotective effect of *Cucumis trigonus* Roxb on isoproterenol-induced myocardial infarction in rat. *Am J Pharmacol Toxicol*. 2009; 4: 29-37.
- Trivedi CJ, Balaraman R, Majithiya JB, Bothara SB. Effect of Atrovastatin treatment on isoproterenol-induced myocardial infarction in rats. *Pharmacology* 2006; 77: 25-32.
- Uma B, Nazam AM, Islam F. Cardioprotective effect of aqueous extract of *Embelia ribes* Burm fruits against isoproterenol-induced myocardial infarction in albino rats. *Indian J Exp Biol*. 2008; 46: 35-40.
- Velavan S, Selvarani S, Adhithan A. Cardioprotective effect of *Trichopus zeylanicus* against myocardial ischemia induced by isoproterenol in rats. *Bangladesh J Pharmacol*. 2009; 4: 88-91.

Author Info

Asokkumar Kuppasamy (Principal contact)
e-mail: kasokkumar@gmail.com