



BJP

Bangladesh Journal of Pharmacology

Clinical Trial

Effect of cock's comb extract in the treatment of palmar arsenical keratosis

Effect of cock's comb extract in the treatment of palmar arsenical keratosis

Fatema Chowdhury Anny and Mir Misbahuddin

Division of Arsenic Research, Department of Pharmacology, Faculty of Basic Science and Paraclinical Science, Bangabandhu Sheikh Mujib Medical University, Shahbag, Dhaka, Bangladesh.

Article Info

Received: 8 June 2018
Accepted: 30 March 2019
Available Online: 7 May 2019
DOI: 10.3329/bjp.v14i2.38421

Cite this article:

Anny FC, Misbahuddin M. Effect of cock's comb extract in the treatment of palmar arsenical keratosis. Bangladesh J Pharmacol. 2019; 14: 87-92.

Abstract

The aim of this study was to examine the effect of cock's comb extract in the treatment of moderate palmar arsenical keratosis. All the patients (n=35) were provided cock's comb extract ointment to apply topically at the site of lesion (s) twice daily for 12 weeks. Adherence to the ointment and adverse effects were monitored regularly through the phone call and during the visit of each patient every fortnightly. Photographs of both palms were collected both before and after treatment. Clinical improvement was assessed by measuring the arsenical keratotic nodular size of both palms before starting the treatment and after completion of the treatment. The mean (\pm SD) size of the nodule length before the study was 33.6 ± 16.8 mm, which reduced to 5.4 ± 5.2 mm after completion of the study. This change (84% reduction) was statistically significant. None of the patients reported any adverse effect during this study period. In conclusion, cock's comb extract can be used effectively as a topical treatment of the moderate palmar arsenical keratosis.

Introduction

The skin manifestations of arsenicosis develop due to the consumption of arsenic-contaminated (>50 ppb) drinking water for more than six months. The common manifestations are melanosis, leukomelanosis and keratosis. Palmar arsenical keratosis, especially in the young unmarried girl creates a social problem.

There is no specific treatment of arsenicosis. Topical application of salicylic acid (Islam et al., 2007), propylene glycol (Dina and Misbahuddin, 2010), garlic oil (Misbahuddin et al., 2013), *Nigella sativa* (Bashar et al., 2014) and neem leaf extract (Ferdous and Misbahuddin, 2014) effectively improve it. There is a clinical improvement of keratosis and melanosis after giving of spirulina extracts plus zinc in arsenicosis patients (Misbahuddin et al., 2006). Vitamin E capsule for 12 weeks also improves the palmar arsenical keratosis (Khalil et al., 2016). However, these systemic

drugs and nutritional supplements require a longer duration of treatment that may affect the compliance of the patients. Signs and symptoms may recur after discontinuation of the treatment. The topical application has some adverse effects like burning sensation and irritation of the skin. So, an investigation is required to search for a new effective drug, which can be applied topically to reduce the skin manifestations as well as no adverse effect.

In this study, cock's comb extract was used as it contains mainly hyaluronic acid with lesser amounts of sulfated glycosaminoglycans (i.e. chondroitin sulfate and dermatan sulfate) (Schiller and Dorfman, 1956). As a major component of cock's comb extract, hyaluronic acid or hyaluronan maintains hydration of the skin due to its water retaining property. It acts as an occlusive agent and prevents transepidermal water loss (Draeos, 2011).



In this study, we examined whether the cock's comb extract was effective in the treatment of moderate palmar arsenical keratosis.

Materials and Methods

Place of the study

The study was carried out at two places: a) Uttar Meher and Dakshin Meher Union of Shahrasti Upazilla, Chandpur District about 150 km from Dhaka, where a large number of people are consuming high concentration of arsenic through drinking water. Arsenicosis patients of those areas participated in this study as volunteers; b) Department of Pharmacology, Bangabandhu Sheikh Mujib Medical University, where the laboratory was used to estimate the amount of arsenic in the drinking water and nail of the participant patients to confirm arsenicosis. The collection of cock's comb extract, cytotoxicity test on the brine shrimp and ointment preparation with cock's comb extract were also done in this laboratory.

Enrolment of patients

The proposed study was carried out on total of 35 patients (27 females and 8 males) of moderate palmar arsenical keratosis from September 2016 to January 2018. Enrolment of the patients was performed according to the inclusion and exclusion criteria (Ferdous and Misbahuddin, 2014; Khalil et al., 2016).

Inclusion criteria of the patients were a) age: 18-60 years; b) both sexes; c) presence of moderate palmar keratosis; d) drinking arsenic-contaminated water (>50 µg/L) for at least more than 6 months; e) patient voluntarily agreed to participate. Exclusion criteria were a) pregnant and nursing mother; b) hypersensitivity to any drug; c) patient who received any treatment of arsenicosis within last three months.

Field procedure

List of the palmar arsenical keratosis patients and their addresses were collected from the Health Inspector of Upazilla Health complex of Shahrasti (Figure 1). With the permission of Upazilla Health and Family Planning Officer, a temporary arsenic center was established there and each patient was informed to visit that center regularly at 2 weeks interval.

Data collection procedures

After taking informed written consent, the detailed history was taken by interviewing and clinical examinations were done mainly based on arsenical keratosis of the palm of the participants and recorded in the data collection sheet.

Collection of water and nail samples

Drinking water: About 50 mL of drinking water was

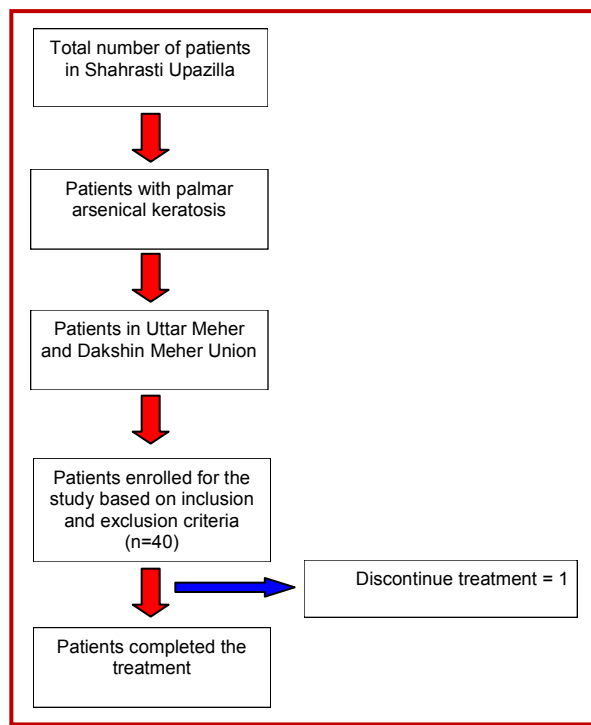


Figure 1: Summary of patient flow

obtained from the participant's tube well and stored in a plastic bottle with an ID number. All the samples were then transported to the laboratory and stored until analysis.

Nail: The participants at first washed and dried their hands and the nail samples were collected from all the fingers and were stored in a polypropylene bag with an ID number. The samples were then transported to the laboratory and stored until analysis.

Estimation of arsenic

The level of total arsenic in the water and nail was measured by the silver diethyldithiocarbamate (SDDC) method with modification (Bhuiyan et al., 2015).

Collection of cock's comb

Cock's combs (7 kg) were collected from the poultry shop of the local market. These combs were washed with tap water and stored in a container in -20°C until extraction.

Brine shrimp lethality test (Sarah et al., 2017)

Serial dilution of the cock's comb extract: Cock's comb extract of 2 mg weighted by analytical balance. Sterile test tubes were taken and labeled properly. The extract (soluble in water) dissolved in 2 mL of distilled water to prepare the stock solution. Serial dilution of the stock solution was done to prepare the concentration of 1000, 100, 10 and 1 µg/mL. About 1 mL of the prepared solution was taken into four test tubes labeled as 1-4

Box 1: Extraction procedure of cock's comb**Requirements**

Acetone, amyl alcohol, centrifuge, calcium chloride, cheese-cloth, chloroform, electric grinder, ethyl alcohol, pH meter, sodium acetate

Procedure

Step 1: Cock's combs (900 g) were washed with water, cut into small pieces and grinded twice in an electric meat grinder

Step 2: Grinded parts immersed in acetone (1 L) and kept in a refrigerator for 24 hours

Step 3: Squeezed the acetone from the combs material, fresh acetone (1 L) was added and kept in a refrigerator for the next 24 hours

Step 4: This procedure was repeated 4 times in 24 hours interval

Step 5: After the last extraction, the remaining acetone was evaporated in a stream of air

Step 6: The weight of the dried and deflated combs was 144 g weighted by the analytical balance

Step 7: The dried and deflated comb were immersed in 500 mL solution of 5% sodium acetate for 24 hours

Step 8: The viscous fluid was drawn out by using cheese-cloth

after 24 hours

Step 9: This procedure repeated 4 times in 24 hours intervals

Step 10: Frequent additional maceration of the combs materials was done in a meat grinder for complete extraction of the viscous material

Step 11: The final comb residue was then discarded

Step 12: Ethyl alcohol about was added to the aqueous extract

Step 13: The precipitate formed was pooled, centrifuged, dissolved in 5% sodium acetate solution and centrifuged

Step 14: The protein was removed from the supernatant solution by shaking it with chloroform four times and then chloroform-amyl alcohol (1:4 parts to 1:2 parts) mixture was added several times until a gel no longer formed

Step 15: Acidification to pH 4.0, the solution was precipitated with ethyl alcohol and the precipitate was dried by calcium chloride

Step 16: The final dried material was fibrous in appearance and was dissolved slowly in water

The final dried material was weighted about 850 mg that was fibrous in appearance and dissolved slowly in water. According to this procedure cock's comb extract was prepared in several times. From total 7 kg cock's comb 6 g extract was obtained.

numbers that contained 10 nauplii and 1 mL of sea-water.

Artemia salina (brine shrimp) eggs were collected from the local market. A rectangular jar was filled with 3 L of water which measured by using a measuring cylinder. Table salt about 27 g weighted by an analytical balance and mixed with the water of the rectangular jar with a spatula. Proper aeration maintained by placing the tip of an airline from an air pump into the bottom of the jar. Brine shrimp eggs about 15 g were mixed with the water of the jar. A light (60-watt bulb) was switched on and placed a few inches away from the jar. The nauplii were hatched after 72 hours. The actively moving 10 nauplii were transferred to each test tube containing a different concentration of cock's comb extract by using Pasteur pipette and motility was observed at 0, 2 and 24 hours. All the test tubes were kept in room temperature and observed the active movement of nauplii after 2 and 24 hours.

Percentage of death = $\frac{\text{No. of dead nauplii}}{\text{No. of dead nauplii} + \text{No. of live nauplii}} \times 100$

Preparation of ointment with the cock's comb extract (Block, 2000)

To prepare 100 g of cock's comb extract ointment, olive oil (90 mL) was taken in a sterile beaker. The beaker was placed in a bowl contained about 100 mL of water and heated by a gas burner up to the boiling point. Bee wax (10 g) was added with the olive oil and heated

until the bee wax melted with the olive oil. Then the mixture was allowed to cool down. The cock's comb extract (100 mg) and benzoic acid (10 mg) were added to the mixture and heated until the mixture became thick in consistency. Then, poured the mixture (25 g) into a clean airtight plastic container and stored in a refrigerator until distribution to the patients.

Distribution of ointment

The ointment was distributed to each patient in a screw cap plastic container and the patient was instructed to apply the ointment on the affected area of the skin by clean fingertip twice daily (at the morning and bedtime) and rubbed it gently on the affected area until the ointment disappeared. The ointment was distributed at every 2 weeks intervals for 12 weeks.

Periodic monitoring of patients

Compliance sheet was supplied to each patient and instructed to give a tick mark after using the ointment on the corresponding date. Regular monitoring was done by cell phone. The changes in nodular size were monitored at every visit. Photographs of both palms were taken both before and after completion of the treatment. Measurement of the arsenical palmar keratotic nodular size was taken before starting and after completion of treatment.

Statistical analysis

Statistical analysis was done by paired 't'-test to

compare the keratotic nodular size changes before and after treatment. Data were presented as mean \pm SD.

Results

Effect of extract on brine shrimp

There was 20% death of nauplii after 24 hours at zero concentration of the extract. With increasing the concentration of the extract, the percentage of death nauplii was increased (Table I). Highest concentration of the extract used (1,000 $\mu\text{g}/\text{mL}$) showed 50% death of nauplii (net death was 30%).

Table I	
Number of dead nauplii at different concentrations of cock's comb extract	
Concentration of extract ($\mu\text{g}/\text{mL}$)	% Dead nauplii (after 24 hours)
0	20
1	30
10	40
100	40
1,000	50

Data were presented as percentage

Characteristics of participants

The mean (\pm SD) age of the participants was 42 ± 14.0 years. The mean amount of arsenic in the tube well water of the participants was 626.6 ± 215.7 $\mu\text{g}/\text{L}$. The mean amount of arsenic in the nail samples of the participants was 10.7 ± 6.7 $\mu\text{g}/\text{g}$. The mean duration of the arsenic exposure of the participants was 10.9 ± 3.6 years. The mean duration of appearance of the keratotic nodules at the palm was 7.7 ± 3.4 years (Table II).

Table II	
Characteristics of the participants	
Parameter	
Age (years)	42 ± 14.0
Male	8
Female	27
Amount of arsenic in tube well water ($\mu\text{g}/\text{L}$)	626.6 ± 215.7
Amount of arsenic in nail ($\mu\text{g}/\text{g}$)	10.7 ± 6.7
Duration of arsenic exposure (years)	10.9 ± 3.6
Duration of keratosis (years)	7.7 ± 3.4

Data were presented as mean \pm SD

Measurement of arsenical keratotic nodular size

The mean (\pm SD) sizes of the nodules before the study was 33.6 ± 16.8 mm, which reduced to 5.4 ± 5.2 mm after 12 weeks of the treatment (84% reduction) (Figure

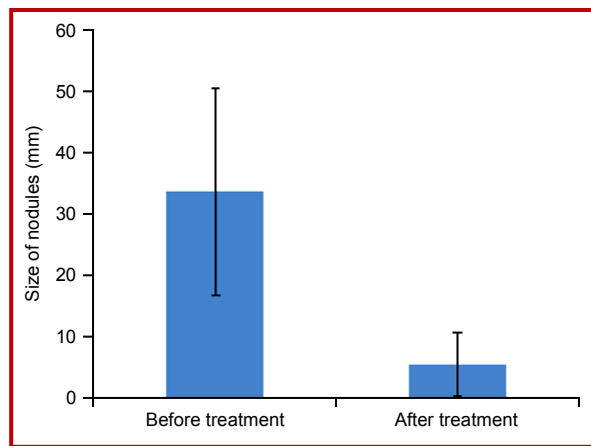


Figure 2: Bar diagram presenting clinical improvement of the patients

2). This change was statistically significant ($p=0.00001$). No adverse effect was reported by the participants.

Discussion

In the present study, topical use of cock's comb extract has shown 84% reduction of the nodular size after 12 weeks of treatment. No adverse effect was reported by the participants.

In the case of keratosis, excess deposition of the keratin occurs and the natural desquamation process is hampered. Normally corneocyte cells remain arranged on the upper layer of the hydrated stratum corneum. Desquamation of the corneocytes is regulated by the water balance and the activity of the proteolytic enzymes, which remains in the stratum corneum. As a result, the skin remains normal by the desquamation process of the corneocytes. The intracellular lipids also regulate the normal desquamation process, which is also maintained by the hydration of the stratum corneum (Egelrud, 2000).

Cock's comb is a fleshy growth on the head of a cock. It is the indicator of the maturity of a cock. Histologically, it is related to the connective tissue that is composed of glycosaminoglycan (Nakano and Sim, 1988).

In keratosis, the natural desquamation process of the skin is hampered and this desquamation process is normalized by repeated hydration of the stratum corneum (Frost et al., 1966).

The topical use of cock's comb extract mimics the role of natural hydrophilic humectants in the stratum corneum as it contains hyaluronic acid. It keeps the skin much more hydrated by retaining a large amount of water in the skin and tends to decrease the keratosis. It maintains the hydration of the skin and repeated hydration regulates desquamation process.

It can be considered that the topical application of cock's comb extract may regularize this desquamation process which can be used effectively in the treatment of arsenical palmar keratosis.

Islam et al. (2007) showed the effectiveness of the topical use of salicylic acid for the treatment of palmar arsenical keratosis. In that study, the concentration of the ointment which had been found to be more effective in the treatment of moderate palmar keratosis was 20 and 30% of salicylic acid. The study showed that 80% of the patients (120 out of 150 patients) improved after six months of topical use of salicylic acid. There were some adverse effects such as burning sensation and pruritis due to long-term use of the drug. Salicylic acid acts as a keratolytic agent which causes chemical debridement of the thickened layer of the skin

Ferdous and Misbahuddin (2014) showed the effectiveness of the extracts of leaves of neem on palmar arsenical keratosis. In that study, topical application of 6% salicylic acid showed 30% improvement. On the other hand, 10% neem with 6% salicylic acid showed 78% reduction in the nodular size after 12 weeks of completion of the treatment. Neem contains many biologically active components that are effective in the treatment of many skin diseases.

Dina and Misbahuddin (2010) evaluated the effectiveness of the topical use of propylene glycol in the treatment of palmar arsenical keratosis. In that study, improvement of the patients was assessed by perception scoring. Patient's monitoring was conducted at 1-month interval. The slight itching had found about 15% of the total patients.

Sabiha (2016) evaluated the effectiveness of neem, propylene glycol and salicylic acid in comparison with salicylic acid alone in arsenical palmar keratosis. The reduction of the nodular size in that study was 59% and 26.4% after completion of the treatment.

Conclusion

Topical use of cock's comb extract has a significant effect in reducing the keratotic nodular size in arsenical palmar keratosis.

Ethical Issue

The protocol was proved by the Institutional Review Board of Bangabandhu Sheikh Mujib Medical University (BSMMU/2017/3324). The research work was registered in the website of the clinical trials.gov (NCT03127657).

Written informed consent forms were prepared in an easily understandable language, Bangla. The objective, nature, purpose and potential risks and benefits of all procedures of the study were explained to all the participants. Written

informed consent was taken from each subject.

Conflict of Interest

Authors declare no conflict of interest.

Acknowledgements

We are grateful to the villagers of Uttar and Dakshin Meher Union of Shahrasti Upazilla, Chandpur District, for participating actively in this study. We are also grateful to Upazilla Health and Family Planning Officer and Health Inspector.

References

- Bashar T, Misbahuddin M, Hossain MA. A double-blind, randomize, placebo-control trial to evaluate the effect of *Nigella sativa* on palmer arsenical keratosis patients, Bangladesh J Pharmacol. 2014; 9: 15-21.
- Bhuiya HA, Tshering K, Misbahuddin M. Estimation of arsenic in nail using silver diethyldithiocarbamate method. Bangladesh J Pharmacol. 2015; 10: 513-17.
- Block LH. Ointments. In Remington: The science and practice of pharmacy. Gennaro, AR (eds). 20th ed. 2000, pp 845-46.
- Boas NF. Isolation of hyaluronic acid from the cock's comb. J Biol Chem. 1949; 181: 573-75.
- Dina AN, Misbahuddin M. Randomized double-blind trial to evaluate the effectiveness of topical administration of propylene glycol in arsenical palmer keratosis. Bangladesh J Pharmacol. 2010; 5: 98-102.
- Draeos DZ. A clinical evaluation of the comparable efficacy of hyaluronic acid-based foam and ceramide-containing emulsion cream in the treatment of mild-to-moderate atopic dermatitis. J Cosmet Dermatol. 2011; 10: 185-88.
- Egelrud TB. Desquamation in the stratum corneum. Acta Dermato-Venereologica. 2000; 80: 44-45.
- Ferdous J, Misbahuddin M. Effect of ethanol extract of leaves of *Azadirachta indica* on palmar arsenical keratosis: A single-blind trial. Bangladesh J Pharmacol. 2014; 9: 279-83.
- Frost P, Weinstein GD, Scott EJV. The ichthyosiform dermatoses II: Autoradiographic studies of epidermal proliferation. J Invest Dermatol. 1966; 47: 561-67.
- Islam AZM, Misbahuddin M, Sikder S, Biswas AK, Islam Z, Hadiuzzaman, Khandaker S, Mahmud I, Ahmed SA. Randomized controlled trial to evaluate the effectiveness of topical use of salicylic acid for treatment of keratosis in arsenicosis. Applied Research on Arsenic in Bangladesh, Dhaka. World Health organization (Bangladesh), Director General of Health services, Government of Bangladesh, 2007, pp 93-102.
- Khalil N, Misbahuddin M, Sattar AN. Pattern of skin bacteria in palmar arsenical keratosis. Bangladesh J Pharmacol. 2016; 11: 940-43.
- Misbahuddin M, Islam AZMM, Khandker S, Mahmud IA,

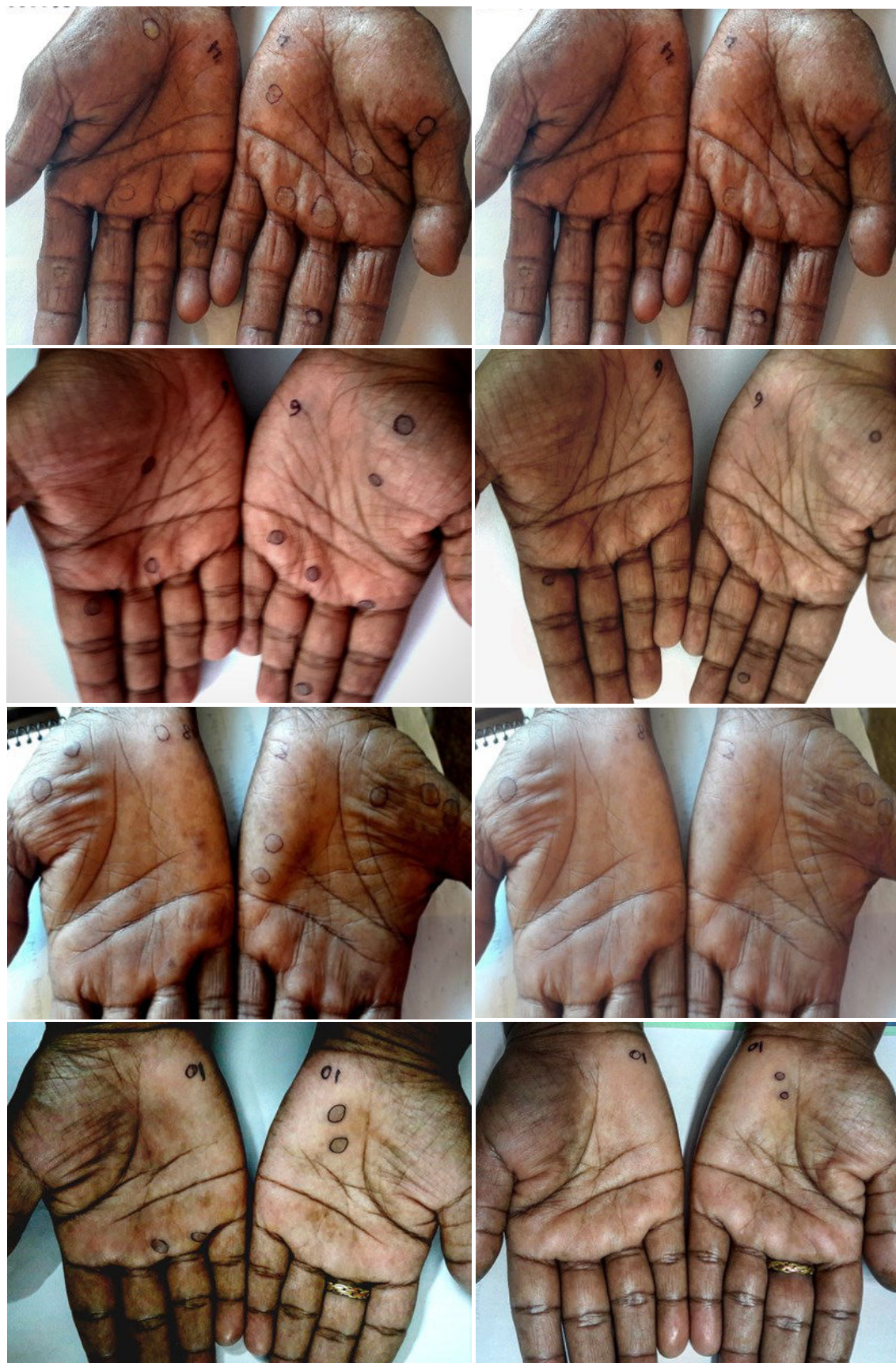
- Islam N, Anjumanara. Efficacy of Spirulina extract plus zinc in patients of chronic arsenicosis poisoning: A randomized placebo-controlled study. *Clin Toxicol (Philadelphia)*. 2006; 44: 135-41.
- Misbahuddin M, Bashar T, Hossain MA. Effectiveness of garlic oil in the treatment of arsenical palmar keratosis. *Bangladesh J Pharmacol*. 2013; 8: 22-27.
- Nakano T, Sim JS. Glycosaminoglycans from the rooster comb and wattle. *Poultry Sci*. 1988; 68: 1303-06.
- Sabiha K. Comparison of neem, propylene glycol and salicylic acid with salicylic acid alone topically in arsenical palmar keratosis. MD Thesis, Bangabandhu Sheikh Mujib Medical University, 2016, pp 40-43.
- Sarah Q, Anny F, Misbahuddin M. Brine shrimp lethality assay. *Bangladesh J Pharmacol*. 2017; 12.
- Schiller S, Dorfman A. Isolation of chondroitin sulfuric acid from the cock's comb. *Exp Biol Med*. 1956; 92: 100-01.
-

Author Info

Mir Misbahuddin (Principal contact)
e-mail: mmisbah@bsmmu.edu.bd

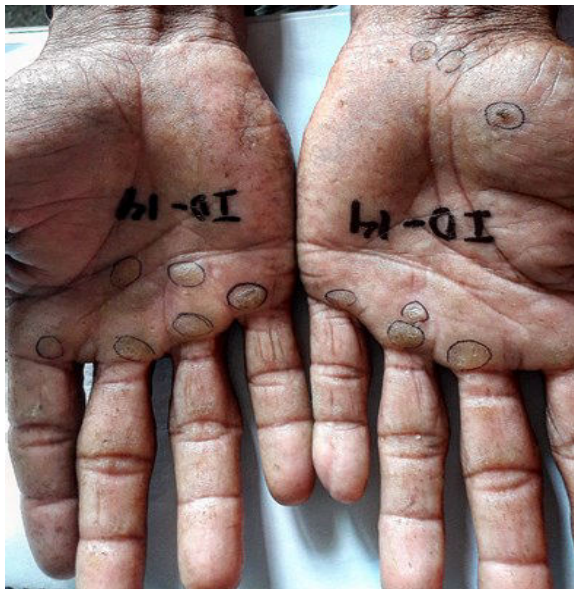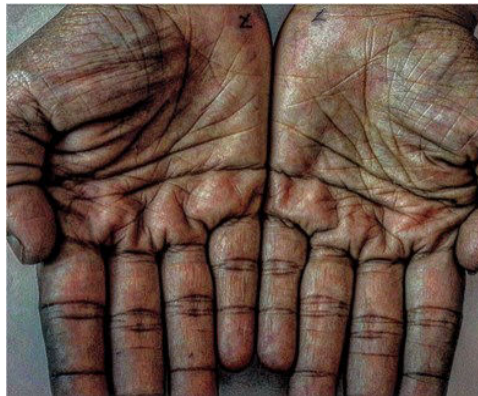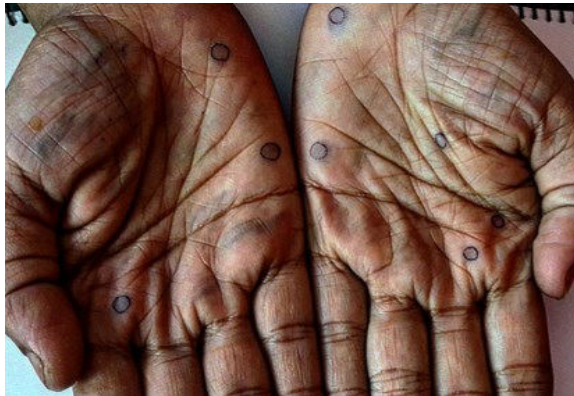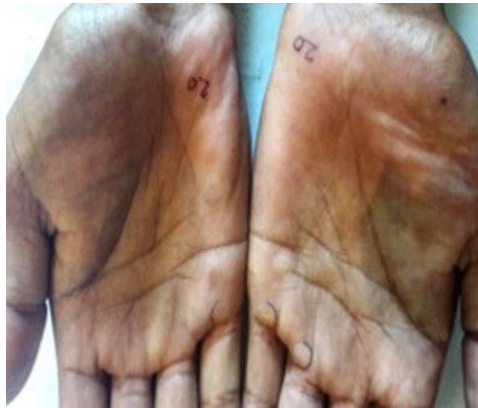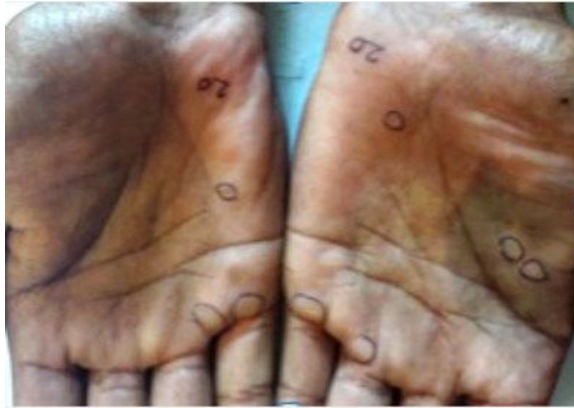Before treatment

After treatment



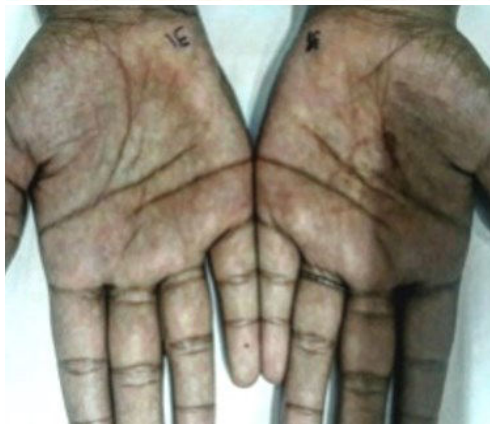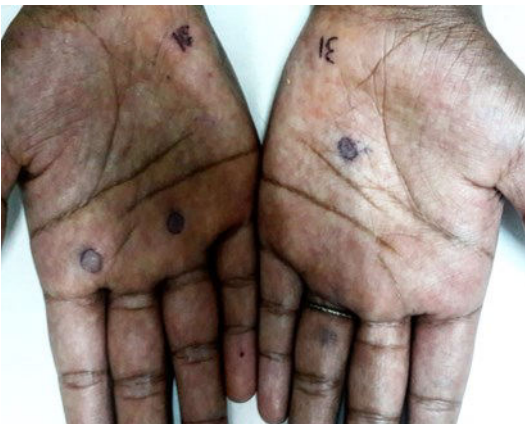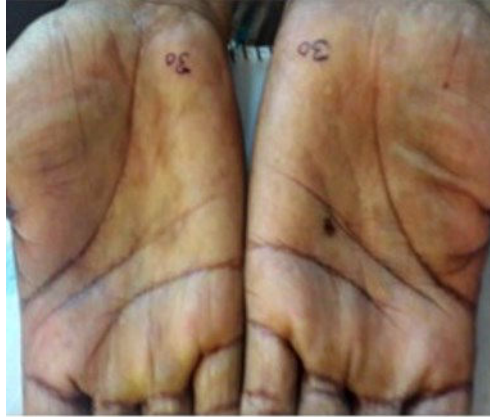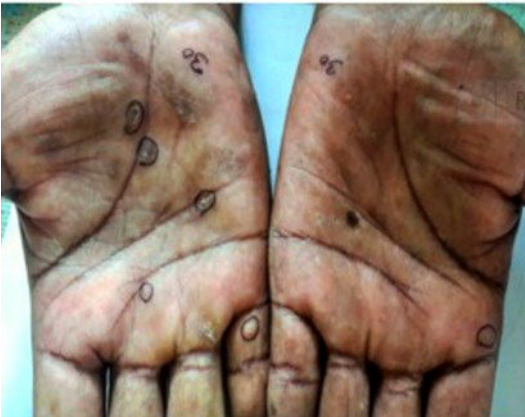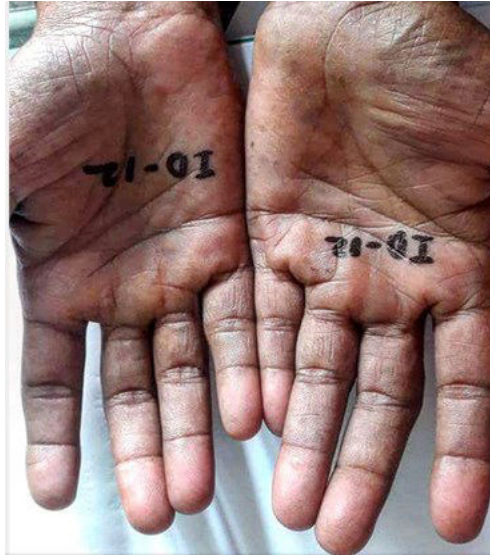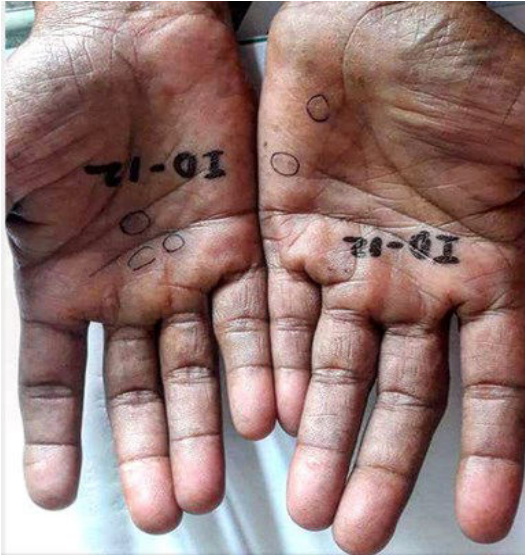Before treatment

After treatment



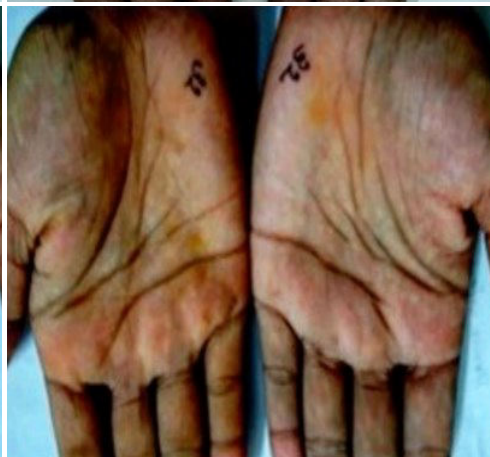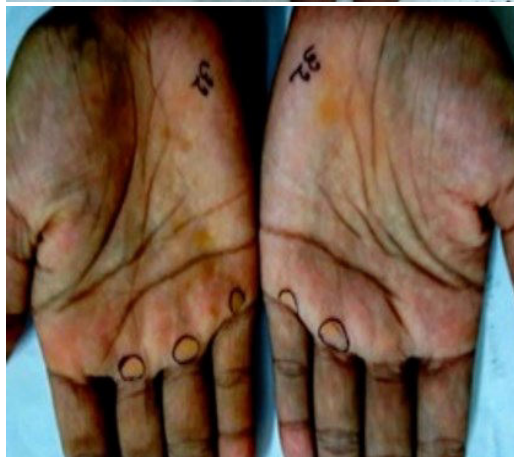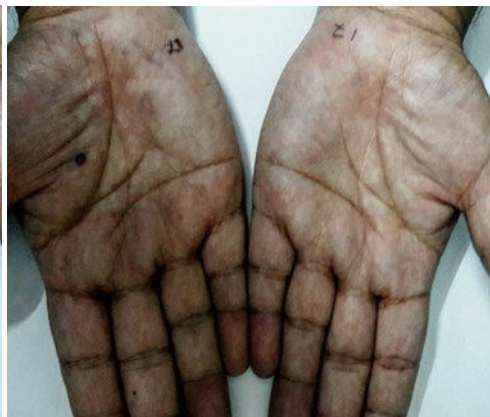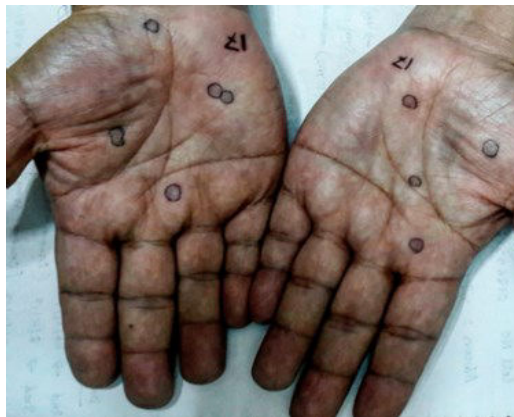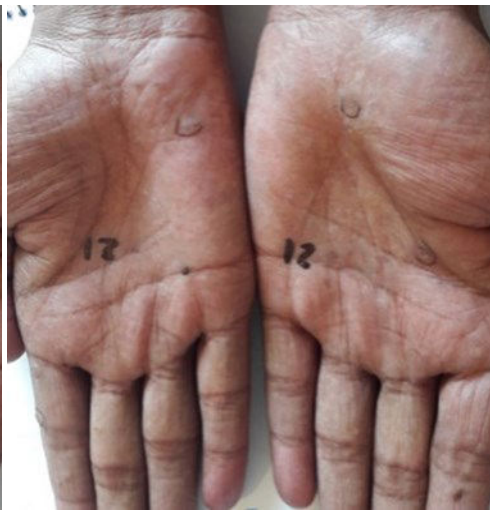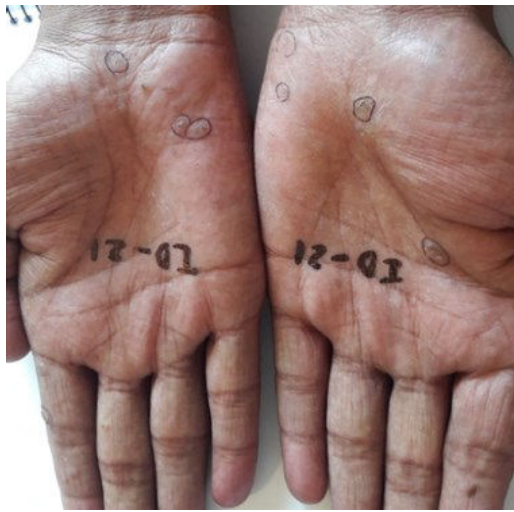Before treatment

After treatment



Before treatment

After treatment



Before treatment

After treatment

