



BJP

Bangladesh Journal of Pharmacology  
Research Article

Hepatoprotective effect of *Misopates orontium* in rats

## Hepatoprotective effect of *Misopates orontium* in rats

Shehla Akbar and Saiqa Ishtiaq

Department of Pharmacy, Punjab University College of Pharmacy, University of the Punjab, Lahore, Pakistan.

Article Info	Abstract
<p>Received: 4 February 2020            Accepted: 6 June 2020            Available Online: 22 July 2020            DOI: 10.3329/bjp.v15i3.45334</p> <p>Cite this article:            Akbar S, Ishtiaq S. Hepatoprotective effect of <i>Misopates orontium</i> in rats. Bangladesh J Pharmacol. 2020; 15: 75-81.</p>	<p>This study explores the hepatoprotective and <i>in vivo</i> antioxidant activities of <i>Misopates orontium</i>. Toxicity studies were conducted on human red blood cells and DNA. Initially, acute hepatoprotective study was done on Wistar rats by giving crude, aqueous, <i>n</i>-hexane, chloroform, ethyl acetate and <i>n</i>-butanol fractions 200 mg/kg/day for 24 hours. Liver function tests were performed. The ethyl acetate fraction was selected for 14 days study. Hepatotoxicity induced by paracetamol (350 mg/kg) orally. All the liver function tests, liver peroxidation tests i.e malondialdehyde, glutathione and histopathological study of the liver was performed at the end of study. In hepatoprotective studies, ethyl acetate fraction showed a significant decrease in the level of serum enzymes (97.6 IU/L), (101 IU/L), (145.17 IU/L) and (0.68 mg/dL). Peroxidation levels in liver homogenates of ethyl acetate-treated group decreased in malondialdehyde (42.5) while reduced glutathione level increased (106.5 nmol/g). This study shows that <i>M. orontium</i> has hepatoprotective and antioxidant effects.</p>

### Introduction

Day to day increase in exposure to chemicals has resulted in more incidence of hepatotoxicity and other liver ailments, therefore it is a need of time to find out new drugs from natural sources to protect against liver ailments (Sisein, 2014; Jurkovič et al., 2008). There are some plants which have hepatoprotective effect i.e. *Ruta montana* (Merghem et al., 2019), *Artocarpus lakoocha* (Saleem et al., 2018), *Cerriops decandra* (Gnanadesigan et al., 2017), *Alhagi maurorum* (Rehman et al., 2015), *Meconopsis integrifolia* (Maxim.) (Zhou et al., 2013), *Trichodesma sedgwickianum* (Tapadiya et al., 2013), *Ipomoea staphylina* (Mumtaz and Bag, 2013), *Zizyphus jujube* (Wang et al., 2012), *Arachniodes exilis* (Hance) (Zhou et al., 2010), *Carissa spinarum* (Hegde and Joshi, 2010).

*Misopates orontium* is commonly called snapdragon used as fodder, in medicinal preparations, as fiber, as fuel wood, as timber, in tanning industry and

preparation of gum (Jabeen et al., 2009). Traditionally it is used as diuretic, for scurvey, in liver disorder and in tumors also. Leaves and flowers were used as antiphathologic, resolvent and all kinds of inflammation (Al-Snafi 2015). *M. orontium* is claimed to be used for several therapeutically assiduities such as, it has bitter and stimulant properties, the whole plant has been employed for the treatment of tumors and ulcers (Lönning et al., 2007). The present study focused on identifying the *in vivo* hepatoprotective properties against paracetamol-induced hepatotoxicity in Wistar albino rats.

### Materials and Methods

#### Plant material collection and extraction

The plant was collected from Bhimber, Kotli, Azad Kashmir and got authenticated by Dr. Uzma Hanif, Department of Botany, Government College University,



Lahore, Pakistan. A specimen of the plant was deposited in the herbarium of Government College University under voucher No. : GC. Herb. Bot. 3458. The plant was dried under shade and powdered the whole herb. This powdered herb dipped in commercial methanol for 7 days, filtered it and evaporated by using a rotary evaporator (Heidolph, model Laborata 4000, Germany). After extraction, fractionation was done using different solvents according to polarity. The active fraction was separated by using small column chromatography and preparative TLC (Li et al., 2008). Analytical TLC was performed on Kieselgel 60 F254 (Merck) plates (silica gel, 0.25 mm layer thickness) and RP-18 F254 (Merck) plates (0.25 mm layer thickness). Spots were visualized using ultraviolet radiation (at 254 and 365 nm) and by spraying with 10% H<sub>2</sub>SO<sub>4</sub>, followed by heating with a heat gun (Li et al., 2008).

### Animals

Wistar albino rats of either sex (170-200 g) were used as animal model. These animals were fed on diet with free access of water under controlled conditions of temperature 22 ± 4°C, humidity (50-60%) and light (12 hours light/12 hours dark cycle). All animals were given standard diet and overnight fasting before sacrifice. Animals were randomly grouped as normal, paracetamol group, silymarin group and treated groups. At the end of the study, animals were sacrificed with mild ethyl ether as anesthetic.

### Toxicity studies

#### *In vitro* hemolytic activity

Fresh human blood (3 mL) was taken in EDTA vial and centrifuged for 5 min at 850 rpm. The clear supernatant was decanted and sedimented pellets were washed three times with chilled sterilized isotonic phosphate buffer saline (PBS) followed by the formation of suspension in 20 mL of chilled sterilized PBS. Cells were counted using a hemocytometer. Triton-X was used as positive control and PBS served as negative control. The reaction mixture contains 20 µL of plant extract and 180 µL of blood cells suspension. They were

incubated at 37°C for 40 min. After incubation, tubes were placed in ice cold PBS for 5 min and then centrifuged at 1,500 rpm for 5 min. The supernatant (100 µL) was collected carefully in the Eppendorf tubes and diluted with 900 µL of chilled sterilized PBS. All these samples including positive and negative control (200 µL) were loaded into 96-well plate. The absorbance was taken at 630 nm using ELISA microplate reader (Zubair et al., 2017). This activity helped us to check the toxic effect of plant extract on the mechanical strength of the cell membrane.

$$\% \text{Hemolysis} = \frac{\text{Abs}_{(\text{sample absorbance})}}{\text{Abs}_{(\text{control absorbance})}} \times 100$$

### Experimental design

The hepatoprotective activities of all derived fractions were studied using the paracetamol-induced liver injury model according to the method described elsewhere (Shenoy et al., 2002). After an adaptation period, rats were divided randomly into 9 groups of 6 animals each. Treatments were then carried.

#### Acute hepatoprotective study

Group 1: Normal control group, which received the vehicle (distilled water) only; Group 2: Received paracetamol only (1.5 g/kg); Group 3: Received the standard drug silymarin (100 mg/kg/day); Group 4: Received the total methanolic extract (500 mg/kg per day); Groups 5-9: Received the aqueous, *n*-hexane, chloroform, ethyl acetate, *n*-butanol fractions (350 mg/kg/day) respectively. Rats of Group 3-9 received paracetamol (75 mg/kg/day) 2 hours after the treatment.

#### Chronic hepatoprotective study

Group 1: Normal control group, which received the vehicle (distilled water) only; Group 2: Received paracetamol (350 mg/kg); Group 3: Received the standard drug silymarin (50 mg/kg/day); Group 4: Received ethyl acetate fraction (200 mg/kg/day). Group 3 and Group 4 received paracetamol (75 mg/kg/day) 2 hours after giving silymarin (Group 3) and ethyl acetate (Group 4).

### Box 1: DNA damage protection assay

#### Principle

In this method, DNA damage was induced by hydroxyl radicals generated from Fenton's reagent. Isolated DNA was quantified using nanodrop technique.

#### Requirements

DNA isolation kit; Electrophoresis; Human blood

#### Procedure

Step 1: Reaction mixture contained 4 µL of genomic DNA, 3 µL of Fenton's reagent and 4 µL of different fractions of plant and made up the volume up to 20 µL using deionized water.

Step 2: Positive and negative controls were also prepared.

Step 3: Reaction mixtures were incubated at 37°C for 30 min.

Step 4: Bromophenol dye was added in each sample after incubation.

Step 5: The reaction mixture (10 µL) was loaded in the wells of 1% agarose gel and electrophoresis was allowed to run horizontally for 1 hour at 100 V followed by staining with ethidium bromide.

Step 6: DNA was visualized under gel documentation system.

#### References

Bhatt et al., 2018

For induction of liver injury, each group except the control group given paracetamol dose 1.5 g/kg after 30 min of administration of the standard drug and plant extract fractions. ALT, AST, alkaline phosphatase, and total bilirubin were carried on each group blood sample (Merghem et al., 2019). After this acute study, chronic study was conducted on the ethyl acetate fraction for 14 days, on the day 15, blood samples were collected for determining enzyme serum level, and livers were taken for histopathology as well as for *in vivo* antioxidant studies.

### Biochemical study

#### Liver function tests analysis

All the animals were anesthetized with mild ether after paracetamol intoxication and blood collected by cardiac puncture method. By using Randox laboratory kits, liver function tests (serum transaminases, alkaline phosphatase, and total bilirubin) were analyzed (Abdessemed et al., 2011; Wan et al., 2013; Mallory and Evelyn, 1937).

#### Antioxidant parameter study

For *in vivo* antioxidant activity, liver homogenate of rats was used to measure level of superoxide dismutase and reduced glutathione (Hassan et al., 2013; Sumantha and Ahmed, 2008).

#### Histological study

Liver tissues were embedded in soft paraffin wax. Fine sections were cut and stained with eosin and hematoxylin, then studied under microscopic for observing pathological changes in liver tissues.

#### Statistical analysis

Results are presented as mean  $\pm$  SEM. ANOVA followed by Tukey post-hoc test during statistical analysis of data. Graph prism pad 6 is used for making curves. Value of  $p < 0.05$  was considered significant.

## Results

### Toxicity studies

In hemolytic activity, percentage hemolysis was increased with increasing the dose but all the fractions showed hemolysis less than 10% except methanol and *n*-hexane fractions which showed 12.8 and 11.5% respectively at 1,000  $\mu$ L dose (Figure 1A). In DNA damage protection assay, lane 1 showed clear band of DNA plasmid (Figure 1B), while lane 2 and 3 did not show any band because this valve contain fenton reagent which had absolute DNA damaging potential but plant extracts had such compounds which protected DNA from damaging. Then lane 4, 5, 6 contained methanol showed clear band of plasmid at all concentrations i.e (50, 100 and 200  $\mu$ g/ $\mu$ L), *n*-hexane extract in

lane 7, 8, 9 had no protective effect, did not find any band at any concentration. Lane 10, 11, 12 contained chloroform fraction doses and 13, 14 and 15 had ethyl acetate fraction doses and both show protective effect and clear plasmid band in these valves. While lane 16 to 21 were *n*-butanol and aqueous fraction containing valves and showed no protective affect and no band showed in these lanes.

### Biochemical examination

The amount of serum enzymes increased in paracetamol-induced hepatotoxicity. Levels of alanine transaminase, aspartate transaminase, alkaline phosphatase and total bilirubin in ethyl acetate-treated group were  $158.8 \pm 21.8$  (IU/L),  $95.6 \pm 10.5$  (IU/L),  $140.0 \pm 16.9$  (IU/L),  $0.8 \pm 0.0$  (mg/dL) in comparison to silymarin  $83.3 \pm 8.2$  (IU/L),  $103.8 \pm 11.7$  (IU/L),  $126.6 \pm 20.9$  (IU/L),  $0.6 \pm 0.0$  (mg/dL) respectively (Table I).

In chronic study, levels of serum enzyme in ethyl acetate-treated group were  $97.6 \pm 9.1$  (IU/L),  $101 \pm 12.6$  (IU/L),  $145.1 \pm 11.1$  (IU/L),  $0.68 \pm 0.06$  (mg/dL) in comparison to silymarin  $115 \pm 15.0$  (IU/L),  $95 \pm 6.6$  (IU/L),  $126.6 \pm 20.9$  (IU/L),  $0.7 \pm 0.0$  (mg/dL) respectively. After chronic study, all rats were sacrificed and their livers saved for *in vivo* antioxidant activity. Malondialdehyde (MDA) and glutathione (GSH) were performed on rats liver homogenate. MDA level decreased  $42.5 \pm 9.1$  (nmol/g) when it compared to toxic (paracetamol) group  $51.3 \pm 2.9$  (nmol/g) while GSH level increased  $106.5 \pm 0.9$  ( $\mu$ mol/g) in comparison with paracetamol treated group  $73.6 \pm 4.0$  ( $\mu$ mol/g) (Table II). Ethyl acetate effectively restored these changes which was similar to silymarin.

### Histopathological studies

Examination under light microscope showed the normal hepatocytes emitted from central vein and blood sinusoids with prominent nucleus in control group (Figure 2A). Paracetamol group showed disordered in hepatic articulator associated with central infiltration which led to severe necrosis. In addition, dilation, hemorrhage of sinusoids were also observed (Figure 2B). Silymarin group showed least hepatic damage and reduction of hepatic necrosis. Few activated kupffer cells and dilated blood sinusoid were observed (Figure 2C). Ethyl acetate group showed restored histological structure and found cytoplasmic vacuoles with minimum activated Kupffer cells (Figure 2D).

## Discussion

According to our knowledge, no literature is available on the cytotoxicity, hepatoprotective activity of the extract and various fractions of Snapdragon (*M. orontium*) belonging to Scrophulariaceae family. Hemolytic, DNA protection and hepatoprotective activities of



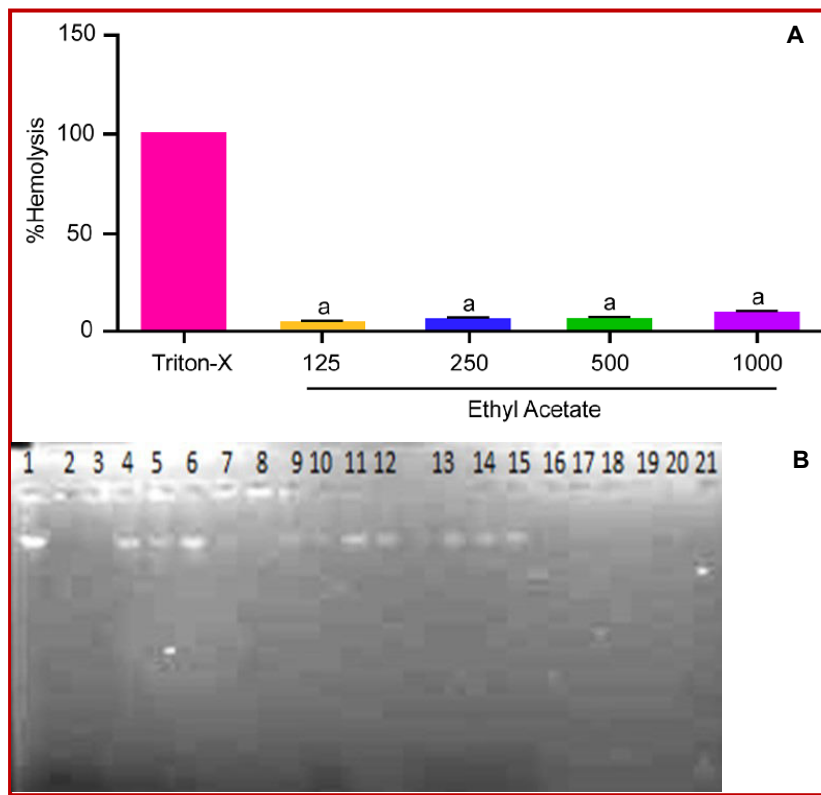


Figure 1: Effect of ethyl acetate extract of *M. orontium* on %hemolysis ( $^{*}p<0.001$ ) (A); on DNA damage protection activity (B). **Lane 1:** 4  $\mu$ L DNA + 16  $\mu$ L DW, **Lane 2:** 3  $\mu$ L FR + 17  $\mu$ L DW, **Lane 3:** 4  $\mu$ L DNA + 3  $\mu$ L FR + 13  $\mu$ L DW, **Lane 4:** 4  $\mu$ L DNA + 4  $\mu$ L methanolic extract (50  $\mu$ g/ $\mu$ L) + 3  $\mu$ L FR + 9  $\mu$ L DW, **Lane 5:** 4  $\mu$ L DNA + 4  $\mu$ L methanolic extract (100  $\mu$ g/ $\mu$ L) + 3  $\mu$ L FR + 9  $\mu$ L DW, **Lane 6:** 4  $\mu$ L DNA + 4  $\mu$ L methanolic extract (200  $\mu$ g/ $\mu$ L) + 3  $\mu$ L FR + 9  $\mu$ L DW, **Lane 7:** 4  $\mu$ L DNA + 4  $\mu$ L hexane extract (50  $\mu$ g/ $\mu$ L) + 3  $\mu$ L FR + 9  $\mu$ L DW, **Lane 8:** 4  $\mu$ L DNA + 4  $\mu$ L hexane extract (100  $\mu$ g/ $\mu$ L) + 3  $\mu$ L FR + 9  $\mu$ L DW, **Lane 9:** 4  $\mu$ L DNA + 4  $\mu$ L hexane extract (200  $\mu$ g/ $\mu$ L) + 3  $\mu$ L FR + 9  $\mu$ L DW, **Lane 10:** 4  $\mu$ L DNA + 4  $\mu$ L chloroform extract (50  $\mu$ g/ $\mu$ L) + 3  $\mu$ L FR + 9  $\mu$ L DW, **Lane 11:** 4  $\mu$ L DNA + 4  $\mu$ L chloroform extract (100  $\mu$ g/ $\mu$ L) + 3  $\mu$ L FR + 9  $\mu$ L DW, **Lane 12:** 4  $\mu$ L DNA + 4  $\mu$ L chloroform extract (200  $\mu$ g/ $\mu$ L) + 3  $\mu$ L FR + 9  $\mu$ L DW, **Lane 13:** 4  $\mu$ L DNA + 4  $\mu$ L ethyl acetate extract (50  $\mu$ g/ $\mu$ L) + 3  $\mu$ L FR + 9  $\mu$ L DW, **Lane 14:** 4  $\mu$ L DNA + 4  $\mu$ L ethyl acetate extract (100  $\mu$ g/ $\mu$ L) + 3  $\mu$ L FR + 9  $\mu$ L DW, **Lane 15:** 4  $\mu$ L DNA + 4  $\mu$ L ethyl acetate extract (200  $\mu$ g/ $\mu$ L) + 3  $\mu$ L FR + 9  $\mu$ L DW, **Lane 16:** 4  $\mu$ L DNA + 4  $\mu$ L butanol extract (50  $\mu$ g/ $\mu$ L) + 3  $\mu$ L FR + 9  $\mu$ L DW, **Lane 17:** 4  $\mu$ L DNA + 4  $\mu$ L butanol extract (100  $\mu$ g/ $\mu$ L) + 3  $\mu$ L FR + 9  $\mu$ L DW, **Lane 18:** 4  $\mu$ L DNA + 4  $\mu$ L butanol extract (200  $\mu$ g/ $\mu$ L) + 3  $\mu$ L FR + 9  $\mu$ L DW, **Lane 19:** 4  $\mu$ L DNA + 4  $\mu$ L aqueous extract (50  $\mu$ g/ $\mu$ L) + 3  $\mu$ L FR + 9  $\mu$ L DW, **Lane 20:** 4  $\mu$ L DNA + 4  $\mu$ L aqueous extract (100  $\mu$ g/ $\mu$ L) + 3  $\mu$ L FR + 9  $\mu$ L DW, **Lane 21:** 4  $\mu$ L DNA + 4  $\mu$ L aqueous extract (200  $\mu$ g/ $\mu$ L) + 3  $\mu$ L FR + 9  $\mu$ L DW; DW means deionized water; FR means Fenton reagent.

Table I				
Effect of different fractions of <i>Misopates orontium</i> on serum enzyme levels in acute hepatotoxic rat				
Treatment	Alanine transaminase (IU/L)	Aspartate transaminase (IU/L)	Alkaline phosphatase (IU/L)	Total bilirubin (mg/dL)
Normal	57.8 $\pm$ 5.5	78.8 $\pm$ 9.2	109.7 $\pm$ 1.7	0.7 $\pm$ 0.0
Paracetamol	1558.5 $\pm$ 45.1	1606.6 $\pm$ 42.7	301.0 $\pm$ 43.3	0.7 $\pm$ 0.3
Silymarin plus paracetamol	83.3 $\pm$ 8.2 <sup>a</sup>	103.8 $\pm$ 11.7 <sup>a</sup>	126.6 $\pm$ 20.9 <sup>a</sup>	0.7 $\pm$ 0.0 <sup>a</sup>
Methanol plus paracetamol	448.1 $\pm$ 64.8	347.8 $\pm$ 60.3	174.6 $\pm$ 15.0	0.7 $\pm$ 0.0 <sup>a</sup>
Aqueous plus paracetamol	502.5 $\pm$ 52.9	350.0 $\pm$ 34.1	154.5 $\pm$ 11.2 <sup>a</sup>	0.8 $\pm$ 0.0 <sup>a</sup>
n-Hexane plus paracetamol	321.6 $\pm$ 23.1	293.0 $\pm$ 37.5	208.1 $\pm$ 18.5	0.8 $\pm$ 0.0 <sup>a</sup>
Chloroform plus paracetamol	372.5 $\pm$ 37.2	197.3 $\pm$ 21.1 <sup>a</sup>	182.3 $\pm$ 24.2 <sup>b</sup>	0.8 $\pm$ 0.0 <sup>a</sup>
Ethyl acetate plus paracetamol	158.8 $\pm$ 21.8 <sup>a</sup>	95.6 $\pm$ 10.5 <sup>a</sup>	140.0 $\pm$ 16.9 <sup>a</sup>	0.8 $\pm$ 0.0 <sup>a</sup>
n-Butanol plus paracetamol	376 $\pm$ 62.6	222.1 $\pm$ 56.5	166.0 $\pm$ 14.5 <sup>a</sup>	0.7 $\pm$ 0.0 <sup>a</sup>

Data presented as mean  $\pm$  SEM, Significant at <sup>a</sup>p<0.001, <sup>b</sup>p<0.01 as compared to control group, n= 6; paracetamol dose (75 mg/kg/day) 2 hours after the treatment of the subject group

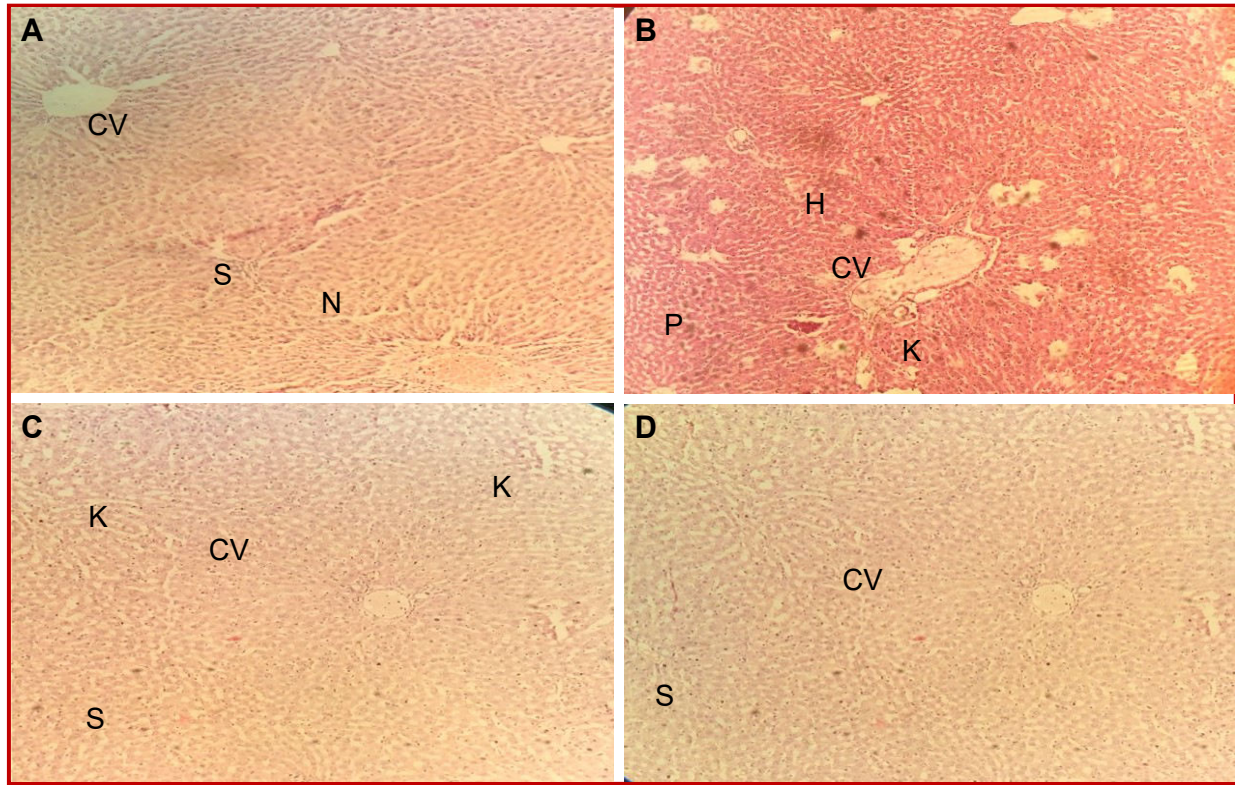


Figure 2: Liver section stained hematoxylin and eosin. A: Normal control group showing central vein (CV), hepatocyte with prominent nuclei (N) and hepatic sinusoids (S); B: Paracetamol group showing inflammatory cells infiltrating around central vein (CV), hepatocellular necrosis with hemorrhage between hepatocytes (H); C: silymarin group showing that hepatocyte (H) mostly had normal appearance less dilated blood sinusoids and activated Kupffer cells (K); D: ethyl acetate extract group showing restored hepatocytes architecture, with less dilated blood sinusoids (S) with activated Kupffer cells (K)

*M. Orontium* are reported in this research study. In hemolytic activity percentage hemolysis is increased with increasing the dose. Membrane of red blood cells have mechanical strength to cope the harmful or toxic effects of various compounds which are taken by human beings in form of herbal medicines and pharmaceutical preparations. On other side, the safe use of plant extracts in the treatment of various diseases can be proved through various *in vitro* cytotoxic assays (Uddin et al., 2011). Our findings verified the safe use of *M. orontium* fractions in hemolytic and DNA damage protection assay. In hemolytic assay all fraction showed the least toxic effect while in DNA damage protection assay only methanol, chloroform and ethyl acetate fraction showed protection of DNA plasmid. In acute and chronic hepatotoxicity ethyl acetate fraction is showing significant result.

Presence of phenolic compounds indicated its antioxidant activity, scavenging of free radical and reducing power of extracts may provide DNA protection. Treatment with *M. orontium* extracts normalized the elevated levels of serum enzymes is a clear manifestation of its hepatoprotective effect. Stabilization of the plasma membrane is one of the main cause to reevaluate its hepatoprotective effects of various plants

(Nadeem et al., 1997). Active constituents of plant extracts responsible for the inhibition of lipid peroxidation, this factor also involved in hepatoprotection (Kanchana and Sadiq, 2011). Liver injury is the result of oxidative stress induced by hepatotoxic agent.

In our study, ethyl acetate fraction showed the reduced elevated levels of serum enzymes (alanine transaminase, aspartate transaminase, alkaline phosphatase and total bilirubin) when compared to paracetamol-induced hepatotoxicity. Presence of various phytochemical constituents in plants extracts may also be related to the hepatoprotective effect of that plant (Ahsan et al., 2009). Increase in liver glutathione activity in paracetamol treated rats as observed in this study indicates the hepatic cells protection. Malondialdehyde is another cytotoxic product (Srinivasan et al., 2007). In treatment reduced level of malondialdehyde indicated that it prevent the lipid peroxidation by paracetamol induced hepatotoxicity.

The maximum amount of phenolics ( $\mu\text{g/g}$ ) was evaluated in plant (*M. majus*) is close relevant specie of *M. orontium* i.e. ferulic acid p-coumaric acid, syringic acid, chlorogenic acid (Riaz et al., 2013). Therefore, the phenolics found in Snapdragon may play a vital role in the biological activities. However, from the literature it

Table II

Effect of ethyl acetate fraction of *M. orontium* on biochemical parameters in chronic hepatotoxicity

Treatment	Alanine transaminase (IU/L)	Aspartate transaminase (IU/L)	Alkaline phosphatase (IU/L)	Total bilirubin (mg/dL)	MDA (nmol/g)	GSH ( $\mu$ mol/g)
Normal	57.8 $\pm$ 5.5	78.8 $\pm$ 9.2	109.7 $\pm$ 1.7	0.7 $\pm$ 0.0	24.9 $\pm$ 1.4	104.3 $\pm$ 7.7
Paracetamol	275.0 $\pm$ 64.3	224.7 $\pm$ 27.9	251.0 $\pm$ 15.3	0.7 $\pm$ 0.0	51.3 $\pm$ 2.9	73.7 $\pm$ 4.0
Silymarin plus paracetamol	115.0 $\pm$ 15.0 <sup>b</sup>	95.0 $\pm$ 6.6 <sup>a</sup>	126.7 $\pm$ 20.9 <sup>a</sup>	0.7 $\pm$ 0.0	34.4 $\pm$ 1.9 <sup>a</sup>	105.9 $\pm$ 2.5 <sup>a</sup>
Ethyl acetate plus paracetamol	97.7 $\pm$ 9.1 <sup>b</sup>	101.0 $\pm$ 12.6 <sup>a</sup>	145.2 $\pm$ 11.1 <sup>a</sup>	0.7 $\pm$ 0.0	42.6 $\pm$ 9.1 <sup>a</sup>	106.6 $\pm$ 0.9 <sup>a</sup>

Data presented as mean  $\pm$  SEM, Significant at <sup>a</sup>p<0.001, <sup>b</sup>p<0.01 as compared to control group, n=6; paracetamol (75 mg/kg/day) 2 hours after giving silymarin or ethyl acetate

observed that phytochemicals such as phenolic acids had the phenolic moiety which was known as a strong biological property (Weng and Gordon, 1992). The results of hepatoprotective effect of *M. orontium* was closely relevant to silymarin (Bahmani et al., 2015). These results helped to find out the clear reason how the hepatocytes maintained the membranous integrity against paracetamol hepatotoxicity (Rehman et al., 2015). It can be supposed that pretreatment with ethyl acetate fraction reduced the lipid peroxidation induced by paracetamol due to presence of natural antioxidants (Weng et al., 2011). Presence of these phenolic compounds may be cause of most effective and safe use of this fraction in comparison to other fraction. HPLC and small column chromatography are also included.

## Conclusion

*M. orontium* has hepatoprotective and antioxidant effects.

## Financial Support

Punjab University College of Pharmacy, University of the Punjab [PUCP. 73698]

## Ethical Issue

The experiments were carried out by following the rules set by Institutional Ethical Committee for Animal care and Experimentation, College of Pharmacy, University of the Punjab, Lahore, Pakistan. The experiments were carried out by Organization for Economic Co-operation and Development (OECD) (Guideline Document No. 423).

## Conflict of Interest

Authors declare no conflict of interest.

## Acknowledgements

We are thankful to our Dean and Principal of the Punjab University College of Pharmacy for their help and encouragement in all aspects regarding our research work.

## References

- Abdessemed D, Fontanay S, Duval RE, Mattar DL, Dibi A. Two new anthraquinone glycosides from *Gladiolus segetum*. Arab J Sci Eng. 2011; 36: 57-62.
- Ahsan R, Islam KM, Musaddik A, Haque E. Hepatoprotective activity of methanol extract of some medicinal plants against carbontetrachloride induced toxicity in albino rats. Global J Pharmacol. 2009; 3: 116-22.
- Al-Snafi AE. The pharmacological importance of *Antirrhinum majus*: A review. Asian J Pharm Sci Tech. 2015; 5: 313-20.
- Bhatt DR, Jethva KD, Zaveri MN. Cytotoxic activity of alcoholic extract and its fractions of *Eulophia nuda* tubers on MCF7 cell line. J Pharmacogn Phytochem. 2018; 7: 704-07.
- Bahmani M, Shirzad H, Rafieian S, Rafieian-Kopaei M. *Silybum marianum*: Beyond hepatoprotection. J Evid Based Complement Altern Med. 2015; 20: 292-301.
- Hegde K, Joshi AB. Hepatoprotective and anti-oxidant effect of *Carissa spinarum* root extract against CCl<sub>4</sub>-and paracetamol-induced hepatic damage in rats. Bangladesh J Pharmacol. 2010; 5: 73-6.
- Hassan I, Keen A, Majid S, Hassan T. Evaluation of the antioxidant status in patients of lichen planus in Kashmir valley: A hospital based study. J Saudi Soc Dermatol Dermatol Surg. 2013; 17: 13-16.
- Gnanadesigan M, Ravikumar S, Anand M. Hepatoprotective activity of *Cerriops decandra* (Griff.) Ding Hou mangrove plant against CCl<sub>4</sub> induced liver damage. J. Taib Uni. Sci. 2017; 11: 450-57.
- Jabeen A, Khan MA, Ahmad M, Zafar M, Ahmad F. Indigenous uses of economically important flora of Margallah hills national park, Islamabad, Pakistan. Afr J Biotechnol. 2009; 8: 763-84.

- Jurkovič S, Osredkar J, Marc J. Molecular impact of glutathione peroxidases in antioxidant processes. *Biochemia Medica*. 2008; 18: 162-74.
- Kanchana N, Sadiq AM. Hepatoprotective effect of *Plumbago zeylanica* on paracetamol-induced liver toxicity in rats. *Int J Pharm Pharm Sci*. 2011; 3: 151-54.
- Li S, Han Q, Qiao C, Song J, Cheng CL, Xu H. Chemical markers for the quality control of herbal medicines: An overview. *Chin Med*. 2008; 3: 1-18.
- Lönnig WE, Stüber K, Saedler H, Kim JH. Biodiversity and Dollo's Law: To what extent can the phenotypic differences between *Misopates orontium* and *Antirrhinum majus* be bridged by mutagenesis? *Biorem Biodiv Bioavail*. 2007; 1: 1-30.
- Mallory HT, Evelyn KA. The determination of bilirubin with photoelectric calorimeter. *J Biol Chem*. 1937; 119: 481-90.
- Mergheem M, Dahamna S, Khennouf S. *In vivo* antioxidant activity of *Ruta montana* L. extracts. *J Mater Environ Sci*. 2019; 10: 470-77.
- Mumtaz SF, Bag AK. Hepatoprotective and nephroprotective activity of hydroalcoholic extract of *Ipomoea staphylina* leaves. *Bangladesh J Pharmacol*. 2013; 8: 263-8.
- Nadeem MPC, Dandiya PC, Pasha M, Imran D, Balani K, Vohora SB. Hepatoprotective activity of *Solanum nigrum* fruits. *Fitoterapia* 1997; 68: 245-51.
- Rehman JU, Aktar N, Khan MY, Ahmad K, Ahmad M, Sultana S, Asif HM. Phytochemical screening and hepatoprotective effect of *Alhagi maurorum* Boiss (Leguminosae) against paracetamol-induced hepatotoxicity in rabbits. *Trop J Pharm Res*. 2015; 14: 1029-34.
- Riaz M, Rasool N, Rasool S, Rashid U, Bukhari IH, Zubair M, Noreen M, Abbas M. Chemical analysis, cytotoxicity and antimicrobial studies by snapdragon: A medicinal plant. *Asian J. Chem*. 2013; 25: 5479.
- Saleem M, Asif A, Akhtar MF, Saleem A. Hepatoprotective potential and chemical characterization of *Artocarpus lakoocha* fruit extract. *Bangladesh J Pharmacol*. 2018; 13: 90-2018.
- Shenoy KA, Somayaji SN, Bairy KL. Evaluation of hepatoprotective activity of *Ginkgo biloba* in rats. *Indian J Physiol Pharmacol*. 2002; 46: 167-74.
- Sisein EA. Biochemistry of free radicals and antioxidants. *Sch Acad J Biosci*. 2014; 2: 110-18.
- Srinivasan R, Chandrasekar MJN, Nanjan MJ, Suresh B. Antioxidant activity of *Caesalpinia digyna* root. *J Ethnopharmacol*. 2007; 113: 284-91.
- Sumantha M, Ahmed R. Antihepatotoxic and antioxidant activity of root of *Taraxacum officinale* in CCl<sub>4</sub> intoxicated rats. *Pharmacogn Mag*. 2008; 4: 188-94.
- Tapadiya GG, Saboo SS, Farooqui IA, Khadabadi SS. Free radical scavenging, *in vivo* antioxidant and hepatoprotective activity of folk medicine *Trichodesma sedgwickianum*. *Bangladesh J Pharmacol*. 2013; 8: 58-64.
- Uddin SJ, Grice ID, Tiralongo E. Cytotoxic effects of Bangladeshi medicinal plant extracts. *Evid Based Complement Altern Med*. 2011; 1-7.
- Wan TJ, Shen SM, Hwang HY, Fang HY. Soybean oil biodegradation using *Pseudomonas aeruginosa* attached on porous ceramic or polyurethane. *Arab J Sci Eng*. 2013; 38: 1025-30.
- Wang D, Zhao Y, Jiao Y, Yu L, Yang S, Yang X. Antioxidative and hepatoprotective effects of the polysaccharides from *Zizyphus jujube* cv. *Shaanbeitanzao*. *Carbohydr Polym*. 2012; 88: 1453-59.
- Weng CJ, Chen MJ, Yeh CT, Yen GC. Hepatoprotection of quercetin against oxidative stress by induction of metallothionein expression through activating MAPK and PI3K pathways and enhancing Nrf2 DNA-binding activity. *New Biotechnol*. 2011; 28: 767-77.
- Weng XC, Gordon MH. Antioxidant activity of quinones extracted from tanshen (*Salvia miltiorrhiza* Bunge). *J Agric Food Chem*. 1992; 40: 1331-36.
- Zhou G, Chen Y, Liu S, Yao X, Wang Y. *In vitro* and *in vivo* hepatoprotective and antioxidant activity of ethanolic extract from *Meconopsis integrifolia* (Maxim.) Franch. *J Ethnopharmacol*. 2013; 148: 664-70.
- Zhou DN, Ruan JL, Cai YL, Xiong ZM, Fu W, Wei AH. Antioxidant and hepatoprotective activity of ethanol extract of *Arachniodes exilis* (Hance) Ching. *J Ethnopharmacol*. 2010; 129: 232-37.
- Zubair M, Rizwan K, Rashid U, Saeed R, Saeed AA, Rasool N, Riaz M. GC/MS profiling, *in vitro* antioxidant, antimicrobial and haemolytic activities of *Smilax macrophylla* leaves. *Arab J Chem*. 2017; 10: S1460-68.

**Author Info**

Saiqa Ishtiaq (Principal contact)

e-mail: saiqa.pharmacy@pu.edu.pk