

# Analysis of Ovarian Artery Doppler - Additional Parameter for Diagnosis of Polycystic Ovary in Bangladeshi Female of Reproductive Age Group

FARZANA SHEGUFTA<sup>1</sup>, RABEYA KHATOON<sup>2</sup>, TARANNUM MORSHED<sup>3</sup>, MD. SHAHJAMAL KHAN<sup>4</sup>, NAYEMA RAHMAN<sup>5</sup>, ISHTIAQUE MD. BEHNOM<sup>6</sup>

## Abstract:

**Background:** Polycystic ovarian syndrome is a common and complex metabolic, endocrine & reproductive disorder of females of reproductive age. **Objective:** The aim of the present study was to evaluate the inherent changes in vascular flow pattern of ovarian artery in patients with endocrinologically and clinically confirmed polycystic ovaries in comparison with normal females of reproductive age having spontaneous ovulatory cycles. **Method:** Total 100 females of reproductive age (18-40 years) were included in this study, 50 of which have been diagnosed as polycystic ovarian syndrome (PCOS) and the other 50 as a control group, without any evidence of PCOS. Transvaginal Ultrasonography (TVS) was performed to evaluate ovarian morphology & Doppler indices (RI & PI) of ovarian arteries. **Results:** Ovarian artery Doppler indices were deranged in women with polycystic ovaries. The mean values of PI is  $4.08 \pm 0.36$  and RI  $0.97 \pm 0.09$ . The mean age of the patients was  $26.4 \pm 5.3$  years and 86% of the patients were obese. **Conclusion:** Despite the complexity of the pathophysiological interactions & the heterogeneity of the anatomical & clinical presentations of polycystic ovarian syndrome, the assessment of ovarian morphology & Doppler indices by TVS provide the pathological status & the degree of progression of the disease. The result of the present study demonstrated the more

significant vascular changes rather than low significant morphological changes. Hence it is possible to include this criteria as an additional marker to diagnose PCOS, which aids early therapeutic intervention, delaying the progression of the syndrome. It will also help in evaluation of the post therapeutic status of PCOS and in taking decision of extending the duration of therapy.

**Key words:** Polycystic ovary (PCO), Transvaginal ultrasonography (TVS) with color Doppler, Resistive index (RI) & Pulsatility index (PI) of ovarian arteries.

## Introduction:

Polycystic ovarian syndrome (PCOS) is a common heterogeneous endocrine disorder of females of reproductive age group<sup>1</sup>. In developed countries, the prevalence rate of PCOS is about 15-20% and it is much higher in South Asian women (52%)<sup>2</sup>. Clinical presentation of polycystic ovaries patients are obesity, hirsutism, acne, menstrual irregularities & is the most common cause of infertility (90-95%)<sup>3,4,5</sup> that affect the quality of life by medical, social, cosmetic & psychological aspects<sup>6</sup>. PCOS affected women show increased risk of gestational complications including miscarriage, gestational diabetes, hypertension, preeclampsia and premature delivery<sup>7</sup>. Definition and diagnosis of PCOS have been evolving over the past 85 years since Stein and Leventhal made their original description of the triad of amenorrhoea, polycystic ovaries and hyperandrogenism in 1935<sup>8</sup>. PCOS was defined according to Rotterdam consensus which states presence of any two of the following: a) oligomenorrhoea / anovulation (>6 menstrual

**Author of correspondence:** Dr. Farzana Shegufta, Associate professor, Department of Radiology and Imaging, Ground floor, BIRDEM, Shahbag, Dhaka, Bangladesh. E-mail-fshegufta78@gmail.com

1. Associate professor, Department of Radiology & Imaging, BIRDEM, Dhaka, Bangladesh. 2. Assistant professor, Department of Radiology & Imaging, BIRDEM, Dhaka, Bangladesh. 3. Assistant professor, Department of Radiology & Imaging, Bangladesh Medical College, Dhaka, Bangladesh. 4. Professor, Department of Endocrinology & Metabolism, Enam Medical College, Savar, Dhaka, Bangladesh. 5. Associate professor, Department of Radiology & Imaging, BIRDEM, Dhaka, Bangladesh. 6. Registrar, Department of Radiology & Imaging, BIRDEM, Dhaka, Bangladesh.

Received: 1 January 2024

Revised: 22 July 2024

Accepted: 11 February 2024

Published: 01 July 2024

cycle in the preceding year) b) signs of hyperandrogenism c) polycystic ovaries detected on Grey scale USG. Criterion of PCOS on USG first defined by Adams et al<sup>9</sup> are :-

Typical polycystic pattern, that is presence of multiple cysts (10 or more), 2-8mm in diameter distributed evenly around the ovarian periphery and/ or increased ovarian volume<sup>10</sup> with an increased amount of echogenic ovarian stroma or less commonly, multiple small cysts 2-4 mm in diameter distributed throughout the abundant stroma<sup>3,11</sup>. Recently, stromal /total ovarian area ratio has been proposed as a criterion for the sonographic evaluation of PCOS<sup>12</sup>.

So, diagnosis of PCOS include clinical features, hormonal assays and sonographic features. Hormonal assays (serum FSH, LH, testosterone) are expensive and no single criteria is sufficient to diagnose it correctly.

The Pathophysiology of PCOS usually includes excess ovarian androgen production (functional ovarian hyperandrogenism, FOH), with or without insulin resistant hyperinsulinism or functional adrenal hyperandrogenism (FAH).

FOH-Excess ovarian androgen production is present in most cases and typically arises from dysregulation of steroidogenesis that changes into estrogen by peripheral conversion. The excessive estrogen level are responsible for the disturbed pattern of luteinizing hormone secretion that stimulates ovarian thecal compartment to secrete more androgens and responsible for typical structural changes in the ovary.

FAH- In 25 to 50% of cases, primary FOH is accompanied by a functionally related primary FAH. In approximately 5% cases, FAH is present without FOH.

Insulin resistant hyperinsulinism- In approximately 50% of cases, PCOS is associated with a selective form of insulin resistance, in which muscle is resistant to the metabolic effects of insulin, while the ovaries, adrenals and adipose tissues remain relatively sensitive to insulin, thereby promoting androgen production and obesity in response to compensatory hyperinsulinemia.

Elevated LH & insulin acts synergistically to induce ovarian stromal and thecal hyperplasia, hyperandrogenism and follicular atresia.

Clinically a strong association between maternal PCOS and sonographic PCO in prepubertal offspring has been observed supporting the hypothesis of genetic transmission of syndrome<sup>13</sup>.

#### **Material and methods:**

This was a descriptive cross sectional study carried out at the department of Radiology and Imaging of BIRDEM from January 2022 to January 2024 and this study was approved by the ethical committee. In this study, 100 females of reproductive age group (18-40years) are included of which 50 are diagnosed case of PCOS according to Rotterdam criteria and other 50 are normal individuals, with no evidence of PCOS. Both the groups underwent transvaginal USG at 3<sup>rd</sup> -5<sup>th</sup> day of menstrual cycle to determine the ovarian morphology as well as Doppler indices (RI & PI) of ovarian arteries of both sides.

Patients who were receiving oral contraceptive pills, any biochemical evidence of hyperprolactinaemia, thyroid disease or adrenal hyperplasia detected on screening laboratory investigations or visible corpus luteum in USG were excluded from the study.

TVS was used to localize ovarian arteries in the ovarian hilum on both sides<sup>14,15</sup>. The optimal timing of USG to diagnose PCOS is during the follicular phase (day 3<sup>rd</sup> -5<sup>th</sup> of menstrual cycle)<sup>16</sup>. Modification of hemodynamic profile is observed in blood flow to uterus and ovaries in relation to cyclic hormonal changes and can be easily detected by using color & pulsed Doppler technology. Increased blood flow characterizes the preovulatory follicle in spontaneous cycle<sup>17</sup>, with a peak flow velocity occurring during the day of ovulation<sup>18</sup>. Control groups with normal menstrual cycle were selected according to USG findings of normal ovaries with documented ovulation and menstrual cycle duration of 26-32 days at least in the previous 3 months without any clinical presentation of hypergonadism. They were scanned between 3<sup>rd</sup> -5<sup>th</sup> day of menstrual cycle in order to avoid interference with blood flow modifications due to ovulation & corpus luteum. Philips Affiniti 50G with C9-4V probe was used for B mode & color flow imaging as well as pulsed Doppler spectral analysis. All examinations were performed by the same radiologist. A two dimensional mode scan was first performed to

evaluate ovarian morphology & to measure the ovarian volume. Ovarian artery was found lateral to the upper pole of the ovary near the infundibulopelvic ligament. After detection of blood flow and visualization of wave form of the ovarian arteries by applying pulsed Doppler range gate across the vessel, blood flow indices were automatically calculated. At least three consecutive correctly imaged blood flow velocity wave forms were analysed & mean value of RI & PI calculated<sup>18</sup>. Now attention has been paid to intraovarian stromal vessels, but the intraovarian arteries are not usually detected before 8-10 days of menstrual cycle & is difficult to obtain angle between the USG beam & ovarian stromal vessels. So blood flow velocities may be inaccurate.

### Results:

Analysis of ovarian artery Doppler-parameters for diagnosis of polycystic ovary in Bangladeshi females of reproductive age group:

Table I shows that majority patients belonged to age group 21-30 years in both groups, the mean age was 26.4±5.3 years in PCOS group and 25.9±5.2 years in control group, that was not significant between two groups. In PCOS group, majority of patients were obese (86.0%) whereas in control group (86.0%) patients were non obese, that was significant between two groups.

Table II shows that right (0.97±0.09 vs 0.78±0.04) and left (0.95±0.08 vs 0.79±0.04) ovarian artery of resistance index was significantly higher in PCOS group than control group.

**Table I**  
*Socio-demographic characteristics of the study patients (n=100)*

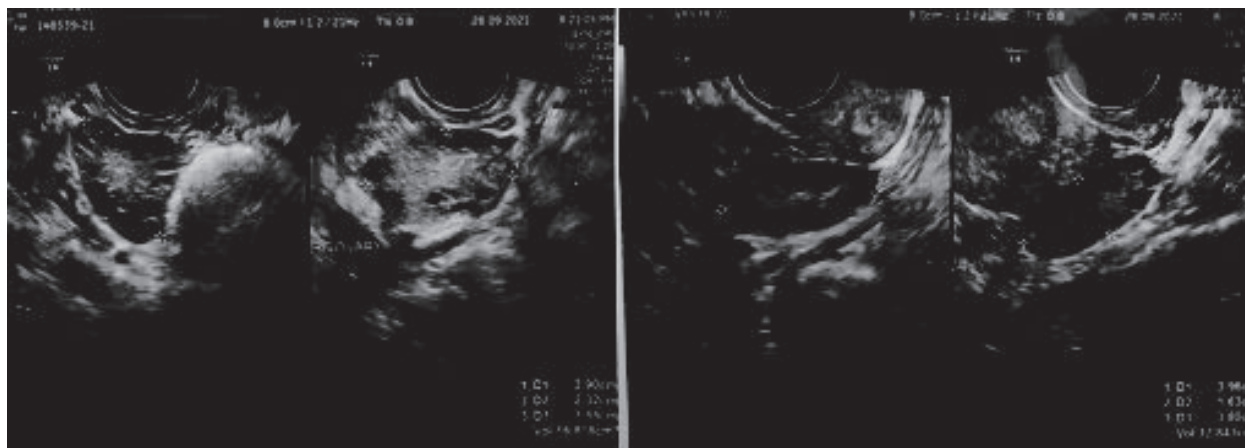
		PCOS(n=50)		Control(n=50)		P value
		N	%	N	%	
Age (years)	≤20	8	16.0	8	16.0	
	21-30	32	64.0	34	68.0	
	31-40	10	20.0	8	16.0	
Mean±SD	26.4	±5.3	25.9	±5.2	0.663 <sup>ns</sup>	
Range (min-max)	19.0	-40.0	19.0	-40.0		
BMI (kg/m <sup>2</sup> )	Non obese	7	14.0	43	86.0	0.001 <sup>s</sup>
	Obese	43	86.0	7	14.0	

s= significant; ns= not significant; P value reached from unpaired t-test & chi square test

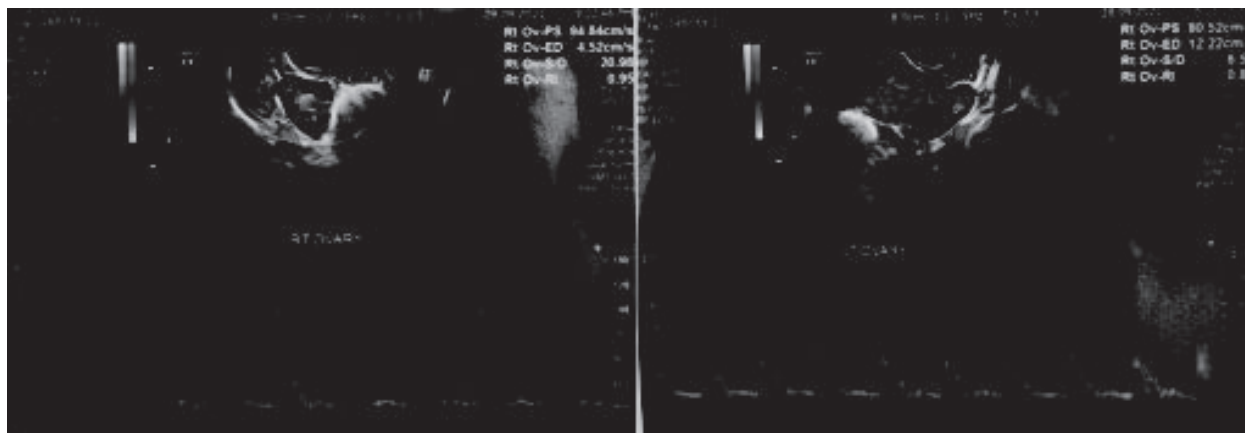
**Table-II**  
*Ovarian artery of resistive index of the study patients (n=100)*

Ovarian artery of resistive index	PCOS(n=50)		Control(n=50)		P value
	Mean	±SD	Mean	±SD	
Right	0.97	±0.09	0.78	±0.04	0.001 <sup>s</sup>
Range (min-max)	0.82	-1.13	0.64	-0.88	
Left	0.95	±0.08	0.79	±0.04	0.001 <sup>s</sup>
Range (min-max)	0.81	-1.13	0.69	-0.89	

s= significant; P value reached from unpaired t-test



**Fig-1:** TVS showing multiple small peripherally oriented follicles with thickened echogenic stroma, typical for PCOS.



**Fig-2:** Ovarian artery Doppler showing raised Doppler indices in both ovaries.

### Discussion:

Polycystic ovary syndrome (PCOS) is extremely prevalent and probably constitutes to be the most frequently encountered endocrinopathy in women of reproductive age worldwide that affects 1 in 10 women. This syndrome is associated with significant morbidity in terms of both reproductive and nonreproductive aspects. In reproductive concern, the majority of women with PCOS have anovulation, infertility and dysfunctional bleeding. In non-reproductive concern, it may be psychological effects due to hirsutism, obesity, increased chances of diabetes, hypertension and coronary artery disease. The obesity in PCOS is android type (central type). Our study shows, in PCOS group, 86% are obese and 14% are non-obese whereas in control group, 86% non-obese. No gold standard diagnostic test can predict it alone. However, the ultrasonographic evaluation ( TVS

is considered more accurate except in children & sexually inactive adolescent girls) is essential in establishing or solidifying the diagnosis. In the present study, the mean age of the patients with PCOS was 26.4±5.3years. Similar mean ages of 27.2±5.9 years has been reported by Ameenah et al and 26.7±4.8 years by Akram et al. Similar observations were also reported by Chaudhari et al of 27.7±7.6years . The mean age range was 28.6±6.3 years in a study conducted by Kumar et al, 27.2±4.8years by Artani et al and 27±5.2 years by Wahab et al.

In the present study, the mean resistive index was 0.97± 0.09(0.82-1.13) and 0.95±0.08 (0.81-1.13) in right and left ovarian arteries respectively whereas pulsatility index was 4.01±0.41 (3.2-4.8) and 4.08±0.36(3.2-4.6) in women with PCOS respectively. Ozkan et al conducted study shows

the mean RI & PI of ovarian artery were 1.73 & 0.76 in right and 1.49 & 0.6 in left ovary in PCOS patients. Similar results have been reported in study by Ameena et al, where mean RI of PCOS patient was  $0.87 \pm 0.03$  and PI was  $3.28 \pm 0.68$  in 84.5% women. Bano et al observed mean RI & PI was  $0.93 \pm 0.10$  &  $3.89 \pm 0.76$  respectively among 84.2% PCOS patients. Our observation is in line with that of Maciolek- Blewniewska et al who found mean RI( $0.87 \pm 0.04$ ) & PI( $3.19 \pm 0.52$ ) in PCOS patients and RI( $0.86 \pm 0.02$ ) with PI ( $3.39 \pm 0.18$ ) in 88% women by Aleem et al . RI ( $0.90 \pm 0.50$ ) & PI ( $3.32 \pm 0.70$ ) was observed in the study conducted by Orakazi ZJ et al and shows that 84.8% patient of PCOS have deranged ovarian artery indices. Our study is in line with the study conducted by Aleem et al who involved 40 patients with confirmed PCOS ,where RI( $0.86 \pm 0.02$ ) & PI ( $3.34 \pm 0.18$ ) respectively in 88% women .The deranged ovarian artery Doppler indices play a putative role in diagnosis of PCOS in suspected patients.

#### Conclusion:

Doppler analysis of ovarian artery is not a part of Rotterdam criteria for ultrasonographic diagnosis of polycystic ovaries but evaluating the changes in vascular pattern in PCOS may allow a better understanding of its pathophysiology. TVS Doppler examination is non-invasive, available, less time consuming method & also sensitive in diagnosis of PCOS.

#### References:

1. Sirmans SM, Pate KA. Epidemiology, diagnosis, and management of polycystic ovary syndrome. *Clinical epidemiology*. 2013 Dec 18;1-3.
2. Akram M, Roohi N. Endocrine correlates of polycystic ovary syndrome in Pakistani women. *J Coll Physicians Surg Pak*. 2015 Jan 1;25(1):22-6.
3. Battaglia C. The role of ultrasound and Doppler analysis in the diagnosis of polycystic ovary syndrome. *Ultrasound in Obstetrics & Gynecology*. 2003 Sep;22(3):225-32.
4. Boyle J, Teede HJ. Polycystic ovary syndrome: an update. *Australian family physician*. 2012 Oct;41(10):752-6.
5. Teede H, Deeks A, Moran L. Polycystic ovary syndrome: a complex condition with psychological, reproductive and metabolic manifestations that impacts on health across the lifespan. *BMC medicine*. 2010 Dec;8:1-0.
6. Khan A, Qasmi IM, Mirza TM, Kubra KT. Frequency of ovarian artery doppler indices in patients of polycystic ovarian syndrome. *Pak J Radiol*. 2019 Oct 1;29(4):218-.
7. Hajam YA, Kumar R, Thakur DR, Rai S. Polycystic ovarian syndrome (PCOS): Signs, symptoms, epidemiology, environmental stress, management strategies and current therapies. In *Herbal Medicine Applications for Polycystic Ovarian Syndrome 2023* (pp. 1-17). CRC Press.
8. Azziz R. How polycystic ovary syndrome came into its own. *F&S Science*. 2021 Feb 1;2(1):2-10.
9. Adams J, Polson DW, Abdulwahid N, Morris DV, Franks S, Mason HD, Tucker M, Price J, Jacobs HS. Multifollicular ovaries: clinical and endocrine features and response to pulsatile gonadotropin releasing hormone. *The Lancet*. 1985 Dec 28;326(8469-8470): 1375-9.
10. Rotterdam EA. Rotterdam ESHRE/ASRM-Sponsored PCOS Consensus Workshop Group. Revised 2003 consensus on diagnostic criteria and long-term health risks related to polycystic ovary syndrome. *Fertil Steril*. 2004 Jan;81(1):19-25.
11. Parisi L, Tramonti M, Derchi LE, Casciano S, Zurli A, Rocchi P. Polycystic ovarian disease: ultrasonic evaluation and correlations with clinical and hormonal data. *Journal of clinical ultrasound*. 1984 Jan;12(1):21-6.
12. Fulghesu AM, Ciampelli M, Belosi C, Apa R, Pavone V, Lanzone A. A new ultrasound criterion for the diagnosis of polycystic ovary syndrome: the ovarian stroma/total area ratio. *Fertility and sterility*. 2001 Aug 1;76(2):326-31.
13. Battaglia C, Regnani G, Mancini F, Iughetti L, Flamigni C, Venturoli S. Polycystic ovaries in childhood: a common finding in daughters

- of PCOS patients. A pilot study. *Human Reproduction*. 2002 Mar 1;17(3):771-6.
14. Goswamy RK, Steptoe PC. Doppler ultrasound studies of the uterine artery in spontaneous ovarian cycles. *Human Reproduction*. 1988 Aug 1;3(6):721-6.
  15. Kurjak A, Kupesic-Urek S, Schulman H, Zalud I. Transvaginal color flow Doppler in the assessment of ovarian and uterine blood flow in infertile women. *Fertility and sterility*. 1991 Nov 1;56(5):870-3.
  16. Maslovitz S, Jaffa A. The ultrasonographic appearance of polycystic ovaries and ovarian hyperstimulation syndrome. *Polycystic Ovary Syndrome*. Anshan Ltd, Kent. 2007:57-67.
  17. Campbell S, Bourne TH, Waterstone J, Reynolds KM, Crayford TJ, Jurkovic D, Okokon EV, Collins WP. Transvaginal color blood flow imaging of the periovulatory follicle. *Fertility and sterility*. 1993 Sep 1;60(3):433-8.
  18. Kupesic S, Kurjak A. Uterine and ovarian perfusion during the periovulatory period assessed by transvaginal color Doppler. *Fertility and sterility*. 1993 Sep 1;60(3):439-43.
  19. Pellizzari P, Esposito C, Siliotti F, Marchiori S, Gangemi M. Colour Doppler analysis of ovarian and uterine arteries in women with hypoestrogenic amenorrhoea. *Human Reproduction*. 2002 Dec 1;17(12):3208-12.
  20. Battaglia C, Regnani G, Mancini F, Iughetti L, Flamigni C, Venturoli S. Polycystic ovaries in childhood: a common finding in daughters of PCOS patients. A pilot study. *Human Reproduction*. 2002 Mar 1;17(3):771-6.