



## Spontaneous Nephrocutaneous Fistula: A Rare Case Report and Our Experience

Shiba Prasad Nandy<sup>1</sup>, Anirban Ghose<sup>2</sup>, Shahanaj Khandokar Nisha<sup>3</sup>, Shib Sankar Saha<sup>4</sup>, Md. Monowar-Ul-Hoque<sup>5</sup>

### Abstract

Received: 01 - 09 - 2021  
Accepted: 09 - 12 - 2021  
Conflicts of interest: None

**Keywords:** Nephrocutaneous fistula, pyonephrosis, pyelonephritis, XGP, Partial nephrectomy, PCN

*Spontaneous nephrocutaneous fistula is a very rare entity. The majority of causes are: post operative, calculus pyonephrosis, chronic pyelonephritis, renal infection, perinephric abscess, trauma. Renal tumor, xanthogranulomatous pyelonephritis (XGP) and renal tuberculosis.*

*A case of spontaneous nephrocutaneous fistula in a 32 years young lady complaining of seropurulent discharge from the fistula over the right lumbar flank for last 8 months is presented and discussed here. Brief history, physical examination. Ultrasonography. CT fistulogram were performed which revealed an active fistula tract from skin to pelvic/colic system of right kidney with a large impacted stone at right pelviureteric junction (PUJ). Patient was nondiabetic and negative for renal tuberculosis whereas renogram showed 32% relative renal function of the affected side. We performed exploration along with excision of the fistula tract, partial nephrectomy, pyelolithotomy with DJ stenting and percutaneous nephrostomy (PCN). Follow up period was grossly uneventful.*

*Currently, the occurrence of these types of spontaneous fistula is extremely rare except in patient with uncontrolled DM, neoplasia or immunosuppression in general.*

### Introduction

Spontaneous renal fistula to the adjacent internal organ (colon, duodenum, jejunum) is not very uncommon.<sup>1</sup> But spontaneous renocutaneous fistula is quite rare and very few cases are reported till now.<sup>2</sup> The main causes of this condition are post operative, trauma, renal tuberculosis chronic urinary tract infection (UTI) with stone, chronic pyelonephritis and pyonephrosis, XGP.<sup>3</sup> Maximum cause yet reported in literatures are associated with chronic UTI and nephrolithiasis.<sup>1</sup> Affected kidney in these cases are usually poorly functioning or nonfunctioning.<sup>3</sup> Open nephrectomy

along with excision of the fistula tract is advocated as well as proper medical therapy of the underlying causes (TB, infection).<sup>4</sup>

In this case, we suggested partial nephrectomy along with excision of the fistula tract and pyelolithotomy as peroperative clinical assessment and relative function of the affected kidney was satisfactory.

### Case report

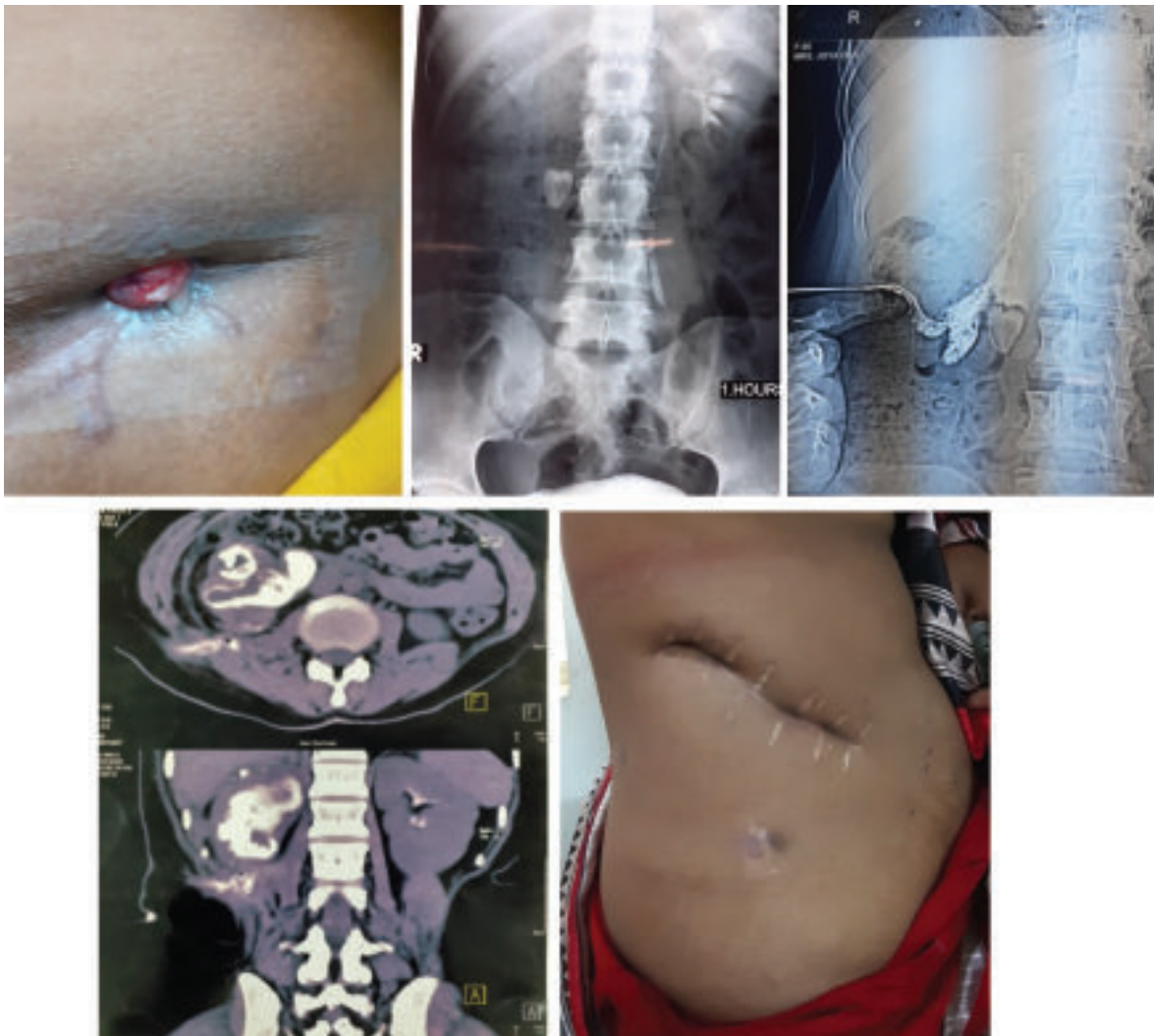
A 28 years old lady from very low socioeconomic condition presented with painless seropurulent discharge from a chronic sinus in the right flank for last

1. Resident Surgeon, Department of Urology, Chittagong Medical College Hospital.
2. Resident, Department of Urology, Chittagong Medical College.
3. Resident, Department of Urology, Chittagong Medical College.
4. Professor of Surgery, General and Laparoscopic Surgeon.
5. Associate professor and head, Department of Urology, Chittagong Medical College.

**Correspondence:** Dr. Shiba Prasad Nandy, Resident Surgeon, Department of Urology, Chittagong Medical College Hospital, Email: [emoncm38@gmail.com](mailto:emoncm38@gmail.com) Cell number: 01818608840

10 months. During presentation she was relatively free but gave history repeated episodic attack of severe right loin pain, high graded fever with rigor, nausea and vomiting and hazy urine with dysuria since last 10 years. She used to treat these problems from village doctor with different antibiotics. On April 2019, she noticed a parietal abscess over right loin with high fever followed by spontaneous burst which was treated locally and conservatively. She was referred to higher center for specific management but she failed to attend. Till then, continuous discharge going on. There was no history of previous surgery, trauma, diabetes mellitus or immunosuppression status. Clinical examination revealed, tender right renal angle, no palpable lump. Patient was mildly anemic, normotensive,

normothermic and undernourished. Serum creatinine and urea level were normal, hemoglobin 9gm/dl, WBC count normal. Urine routine examination and culture showed plenty pus cells and growth of E. Coli. Urine AFB was negative and PCR of discharge also negative for tuberculosis. X-Ray of KUB region showed a large radio opaque shadow at L3 level of right lumbar region. Ultrasonography revealed hydronephrotic right kidney, impacted large right PUJ stone, renocutaneous fistula?. CT fistulogram showed an active right nephrocutaneous fistula, right pyonephrosis with impacted large PUJ stone, grossly dilated right PC system with debris filled the renal calyces. DTPA/ DMSA renogram revealed 36% relative function on right kidney with low perfusion and parenchymal radiotracer uptake whereas contralateral one was normal.



**Figures:** Active right loin fistula, IVU: Right PUJ stone with normal excretion on left side, CT- Fistulogram: Right nephrocutaneous fistula, Healed wound and fistula opening

Finally we decided to explore, went through a virgin area (Right intercostal incision, through 10 and 11 ribs) after injecting methylene blue through the fistula opening. Right kidney was found grossly dilated with satisfactory renal parenchyma, calices were filled with debris, a large impacted stone at PUJ, fistula tract was opened through the lower calyx. Gross adhesion was noticed along with duodenum, ascending colon and right renal pelvis. Partial nephrectomy with total excision of the fistula tract, pyelolithotomy and DJ stenting and percutaneous nephrostomy (PCN) carried out. Fistula tract was laid open, a retroperitoneal drain was kept in situ and closed by layers. Post operative period was grossly uneventful, we discharged the patient on 5<sup>th</sup> POD. SSI noticed on 8<sup>th</sup> POD for which surgical dressing and secondary closure done. Histopathology of the fistula tract reported no tuberculosis or malignancy. Chronologically we removed PCN, drain and DJ stent. Patient claimed no complains upto her last follow up almost 7 months after surgery.

### Discussion

Renal fistulas usually are complications of surgical procedures on the kidney, renal trauma, tumors and chronic urinary tract infections with formation of perirenal abscess.<sup>5</sup> Cutaneous fistula from the urinary tract may arise from the kidney, ureter, bladder or urethra. Nephrocutaneous fistula may occur as a result of chronic infection especially in the setting of calculus diseases. Such abscesses can derive from organs that are adjacent to the kidney, as well as from the kidney itself, by extension of urinary infection to the adjacent tissues, either by contiguity or by lymphatic route. In other occasions, abscesses can originate from an urinoma or urinary pseudocyst, that arise as result of external or surgical trauma on the kidney, promoting loss of continuity between it and the surrounding tissues.<sup>2</sup>

Currently, the occurrence of renal and perirenal abscesses is rare, except patients with diabetes, with neoplasm or immunosuppression in general. Fistulas can develop between the kidney and the pleural cavity, lungs and bronchia, bowel, and skin. However, renocutaneous fistulas are rare and whenever they occur, they typically involve patients with a past history of renal surgery or stone disease.<sup>6</sup>

The majority of fistulas present with spontaneous drainage through the lumbar region following those points with lowest resistance, such as the lumbar

triangle (Petit) and the lumbar quadrilateral (Grynfeld), establishing a fistulous pathway that communicates the perirenal tissues and collecting system with the external environment.<sup>7</sup> The formation of renal abscess has been described as an initial step in formation of spontaneous fistula. However, renal surgery or trauma can lead to formation of such fistula without passing through this stage. The association with infectious renal stones is frequent and has occurred in all cases described in the literature (1-3). Our review of the literatures revealed, XGP to be the most common cause of nephrocutaneous fistula, followed closely by tuberculosis of kidney. Fistula formation after surgery is the next leading cause whereas spontaneous fistula in case of nephrolithiasis is very uncommon.<sup>8</sup> In our case, the patient had an impacted PUJ stone in the involved kidney. Therapeutic approaches must be based on the renal function and on the patient's ability to tolerate the surgical procedure which can include total nephrectomy, partial nephrectomy or isolated antibiotic therapy.<sup>2</sup>

### Conclusion

Fistula formation due to distal obstruction is typically treated with relieve of obstruction. Spontaneous nephrocutaneous fistula is very uncommon diagnosis. Open surgical approach, as undertaken in our case, is recommended for such condition rather than minimally invasive technique. Clinical diagnosis of such fistula is difficult as there are no specific symptoms. Therefore high degree of suspicion of this condition in such patients is much more important. Early surgical intervention in the form of partial/ total nephrectomy, removal of the fistula tract along with specific management of the underlying cause can prevent morbidity and mortality.

### Conflict of interest

None

### References

1. Rovner ES, Urinary tract fistulae. In; Wein AJ, Kavoussi LR, Novick AC, et al. Editors, Campbell-Walash Urology. 11<sup>th</sup>ed: Saunders, an imprint of Elsevier Inc; 2015. 77, P, 2261
2. Singer AJ. Spontaneous nephrocutaneous fistula, *Urology*, 2002; 60: 1109- 1110
3. Prof. (Dr.) Rajesh Kumar Abbey and Dr. Anantbir Lubana, 2016. Spontaneous Nephrocutaneous Fistula- A rare case report and review of literature,

*International Journal of Current Research*, 8 (08), 36357- 36361

4. Sharma A, Ahmed Z, Choudhury A, Songra M, 2013. Spontaneous Nephrocutaneous Fistula in Tuberculosis Pyelonephritis: An unusual occurrence, *Int J Med Res*. 3 doi: 10.5958/j.2319-5886.3.1.044acc13/12/2013
5. Bryniak SR, Primary spontaneous renocutaneous fistula. *Urology*, 1983; 21: 516- 517
6. Alazab R, Ghawanmeh HM, Abushamma F, Ababnesh O, Al-Karasneh Al: Spontaneous nephrocutaneous fistula: Rare complication of xanthogranulomatous pyelonephritis. *Urol Case Rep*. 2017 (<https://dx.doi.org/10.1016/j.eucr.2016.10.019>)
7. Alberto A, Adriano AC, Evandro F, 2004. Spontaneous Nephrocutaneous Fistula, *Int Braz J Urol*, 30(4): 316- 318
8. Tanwar R, Rathore KV, Rohilla MK. Nephrocutaneous fistula as the initial manifestation of asymptomatic nephrolithiasis: A call for radical management. *Urol Ann* 2015; 7: 94- 96.