

## REVIEW ARTICLE

# HOLMIUM LASER IN UROLOGY - A REVIEW ARTICLE

MS ISLAM<sup>1</sup>, H RASHID<sup>2</sup>, S WAHEED<sup>3</sup>, MA RAKIB<sup>4</sup>, CM ASHIF<sup>5</sup>

### Introduction:

The Laser (an acronym for light amplification by the stimulated emission of radiation) is a device of producing a highly directional beam of coherent (monochromatic and in phase) electromagnetic radiation, which may or may not be visible over a wide range of power outputs. The special qualities of laser light make it ideal for a variety of applications<sup>1</sup>. In 1966, Parsons, using a ruby laser in a pulse mode, was the first urologist to experiment with laser light in canine bladder. Mulvane attempted to fragment urinary calculi 2 years later, again using the ruby laser. Subsequently, researchers tested many new substrates or lasing materials leading to diversity in their clinical application<sup>2</sup>.

### Basic principle:

When a photon of light energy of the same wavelength strikes an excited atom, that photon of light that is released are discharged simultaneously and will therefore be identical in frequency and phase. This is the concept of stimulated emission used in the creation of a laser<sup>2</sup>. In medical applications, only light that is absorbed is useful, when laser light is incident on tissue, four things can happen:

- Some light is reflected .
- Some of the remaining transmitted light is scattered inside the tissue which in some cases lead to damage far beyond the area where the beam would seem to propagate through the tissue.
- Some of the remaining light is absorbed, either by water in the tissue or by some other absorber, known as a chromophore, such as haemoglobin and melanin.
- Finally, some of the light may be transmitted all the way through the tissue. The basic point is that only the third item-absorption, is of interest in almost all medical applications<sup>3</sup>. Absorption is the most important interaction of laser light with tissue. A chromophore is required in order to achieve absorption. Body chromophores accessible for laser light include blood, water and melanin. Absorbed laser light is converted to heat and depending on the amount of heat, the clinical effect will be tissue coagulation or vaporization. Absorption depth is dependent on the

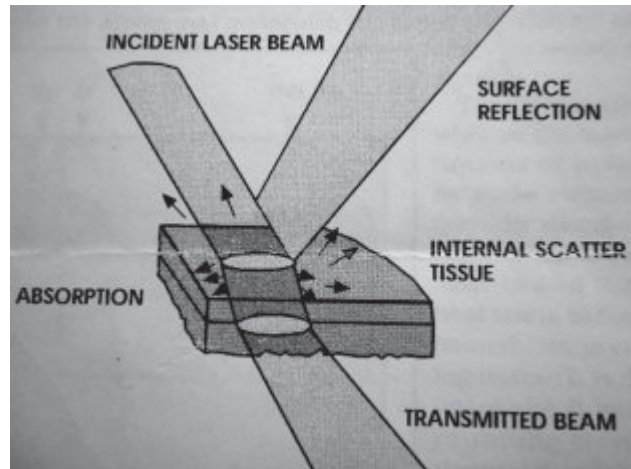


Fig.-1: The primary interactions of laser light with tissue

wave length of the laser<sup>2</sup>. The above four mechanisms are illustrated schematically in figure 1

### Kinds of laser:

There are four main types of laser.

1. Solid state lasers
  - Nd:YAG laser
  - Ho:YAG laser
2. Semiconductor lasers
  - Diode lasers
3. Gas lasers
  - Co<sub>2</sub> laser
  - Argon laser
4. Dye lasers

### Types of commonly used lasers in urology:

Over the course of the last four decades, many possible application of laser in urology have been investigated. This trial and error era of the 1980s was a crucial step in the process of evaluation of this technology. Every imaginable use was explored and varying degrees of success was gained. To improve its safety an effectiveness it is constantly being refined.

Today, the types of lasers most commonly used in urology include

- For stone disease
- Ho:YAG,Pulsed dye,Alexandrite

- For Bladder malignancies
- Nitrogen laser
- For soft tissue incisions (urethral stricture, PUV, Bladder neck contracture, Endopyelotomy)
- Nd:YAG , Ho:YAG, or KTP
- For resection and ablation (eg, BPH, condylomata, penile carcinoma, bladder haemangioma)
- Nd:YAG, Ho:YAG, KTP:YAG,Co2
- For tissue welding (e.g., Vasovasotomy, Urethral reconstruction for hypospadias, Stricture, Diverticula, or Fistulas.
- Diode, KTP, Nd:YAG , or Co2

The Ho:YAG laser is currently the principal urological laser. It has a wavelength of 2140 nm and is highly absorbed by water and therefore by tissues which are composed mainly of water. The majority of the holmium laser energy is absorbed superficially, resulting in a superficial cutting or ablation effect. The depth of the thermal effect is no longer greater than 1 mm. The Ho:YAG laser produces a cavitations bubble that generates only a weak shock wave as it expands and collapses. Holmium laser lithotripsy occurs primarily through a photothermal mechanism that causes stone vaporization<sup>4,5</sup>.

**Uses of the Ho:YAG laser :**

- Laser lithotripsy.
- Resection of the prostate
- Division of urethral strictures
- Division of ureteric strictures including PUJO
- Ablation of small TCC.

**Advantages :**

- The holmium laser energy is delivered via a laser fibre, which is thin enough to allow its use down a flexible instrument. It can access to otherwise inaccessible part of the kidney.
- Zone of thermal injury adjacent to the tip of the laser fibre is limited to no more than 1 mm.
- Can be used for all stone types.
- Minimal stone migration due to minimal shock wave

For resection of prostate, irrigant is normal saline. So the risk of TUR syndrome is avoided.

**Disadvantages:**

- High cost
- Produces a dust cloud during stone fragmentation, which temporarily obscure the views.

- Can irreparably damage endoscopes if inadvertently fired near or within the scope
- Relatively slow stone fragmentation
- The laser fibre must be painted over the surface of the stone to vaporize it

**Ho:YAG laser in prostatectomy:**

Several different techniques of laser prostatectomy evolved during the 1990s. Essentially in the year 2009 we are left just two – Holmium laser prostatectomy and the green light laser<sup>6</sup>. Ho:YAG laser enucleation of the prostate (HoLEP) combined with mechanical morcellation represents the latest refinement of Ho:YAG laser surgical treatment for BPH<sup>7</sup>. In this technique prostatic lobes are dissected off the surgical capsule and then pushed back in to the bladder. The laser fibre is analogous to the index finger of a surgeon during an open prostatectomy. Generally three whole lobes are enucleated, two lateral and one median. A transurethral soft tissue morcellator was developed contemporaneously which allowed these lobes to be evacuated from the bladder. The operative time has been shortened considerably compared with HoLRP. In absence of morcellator mashroom technique can be applied. Where the last attachment of prostatic tissue that is not detached, dissected by conventional TURP.

HoLEP is technically more difficult to master than laser vaporisation and has a longer learning curve, but the overall results are at least equivalent to TURP with fewer associated risks. At short-term follow up , HoLEP has proven equivocal results to TURP, however the HoLEP group had shorter catheterisation times and hospital stays, and a larger volume of prostatic tissue was removed<sup>8</sup>. Long term follow up ( 7years) demonstrates sustained significant improvements in symptom scores and flow rates<sup>9</sup>. In a direct comparison with open prostatectomy, HoLEP has also demonstrated equivalent improvement in symptom scores and flow rates at 3 years follow-up<sup>10</sup>.

**Holmium laser ablation of the prostate(HoLAP)**

A side firing dual wave length fibre is used in a near contact mode to vaporise prostate tissue circumferentially to produce a satisfactory channel. Original techniques 60 watts laser, however lasers up to 100W are now available. Symptom improvements are sustained in the long term<sup>11</sup> , and when directly compared with TURP, similar efficacy was in the HoLAP group, and less bleeding than for TURP<sup>12</sup> . Both the study suggest over all it is most effective for smaller prostate glands.

**Holmium laser resection of the prostate (HoLRP):**

This technique copies that of TURP, where by the precise cutting ability of the holmium laser is used to remove pieces of prostate down to the capsule, to create a large and relatively bloodless channel. It can be used on prostate glands of all sizes. Again, it has short catheterisation times and hospital stays, and is associated with minimal post operative dysuria<sup>13</sup>.

**Advantages of Ho:YAG Laser in Prostatectomy :**

- i. HoLEP is superior to TURP in reliving the BOO urodynamically .Catheter time , hospital stay is lesser <sup>14,15</sup> .
- ii. For larger Prostate there is no fear of TUR syndrome as saline is using as irrigation fluid.
- iii. Blood transfusion is hardly necessary as bleeding is minimal<sup>16</sup>
- iv. Stopping of anticoagulant is not mandatory<sup>16</sup>

**Ho:YAG laser in lithotripsy :**

The Ho:YAG laser is one of the safest , most effective and most versatile intracorporeal lithotripter.It produces significantly smaller fragments in comparison to other lithotrites. This small fragments are easily irrigated out so extraction by grasper and baskets are reduced<sup>17</sup>. The Retropulsion of the stone is minimum as it produces minimum shock waves.

**Ho:YAG laser in Stricture:**

For Stricture disease results are mixed. It is not known of lasers after a significant advantage over electrocautery or cold knife incision techniques<sup>18</sup>.

**Ho:YAG laser in Bladder Tumour:**

Ho:YAG laser ablates tissue by cutting (Vaporization) .Thus have limited applicability due to lack of deep coagulation <sup>19</sup>.

**Other uses:**

Ho:YAG laser can be used in ureteral stricture, ablation of TCC, BNI, Condylomata, penile carcinoma.

**Conclusion:**

*'A splendid light has dawn on me...'*

*Albert Einstein.*

The introduction of laser in urology was met with great excitement and enthusiasm.

With the Widespread use of small diameter endoscopic instrument, urology has been drastically and positively influenced by this laser technology. Ho:YAG laser is

one of the widely used technology in this regard . So far in the management of stone diseases Ho:YAG is better and effective than any other available lithotrite.From published reports the role of the holmium laser in the management of urolithiasis and BPH is well established. Besides other techniques Ho LEP Has Shown the Procedure to be a safe and effective alternative for the surgical treatment of BPH<sup>20</sup> .The procedure has been shown to have superior short and long term outcomes to transurethral resection of the prostate (TURP) and suprapubic prostatectomy. Benifits of the HoLEP procedure include complete removal of the adenoma to the level of the prostate resecting in a less than 2% retreatment rate, lack of surgical incision, and no effect on erectile function. Furthermore, HoLEP can be performed on prostate of any size<sup>21</sup>.The erbium: yttrium-aluminium-garnet( Er:YAG ) laser has been studied for urologic application. Studies have suggested that the Er:YAG laser may be superior to the Ho:YAG laser for precise ablation of strictures with minimal peripheral tissue damage and for more efficient laser lithotripsy<sup>22</sup>.The thulium:YAG laser has recently been investigated in an attempt to improve on some of the shortcomings of the Ho:YAG laser.This new laser more closely matches the water absorption peak in soft tissue to minimize collateral tissue damage. It has also been studied as a new endoscopic lithotrite, with promising initial results. Clinical experience with this laser is limited and reflects technical issues with the fibre delivary systems<sup>23</sup>At present no user friendly delivary system that allows for endoscopic use exists. Further developments are anticipated eagerly. New lasing mediums are the subjects of intense reaserch and development worldwide. Plastic conjugated polymers are one of the most promising mediums under study.

**References**

1. Islam MS, Akbar MA, Rashid H, Waheed S, Nahar N. Medical lasers : An update. JAFMC 2006; 2:11-16.
2. Mark AJ, Teichman JM. Laser in Urology. World J Urol 2007 Jun; 25(3):227-33.
3. Yarbrough JM. The photonics design and applications handbook, 1996.
4. Vassar GT, Teichman GM, Glickman RD. YAG lithotripsy efficiency varies with energy.J Urol 1998;160-471.
5. Floratos DL, Delarosette JJ. Laserin Urology. BJU Int1999 July; 82(2):204-11.

6. Reynard J, Brewster S, Biers S. Invasive surgical alternatives to TURP: Oxford Handbook of Urology. Oxford University Press 2009 ;2<sup>nd</sup> ed: 96-97.
7. Kuo RL, Paterson RF, Kim SC, Siqueira TM, Elhilali MM, Lingeman JE. Holmium laser enucleation of the prostate: A technical update. World Journal of surgical oncology 2003;1(6): 1-9
8. Wilson LC, Gilling PJ, Williams A, et al. A randomised trial comparing holmium laser enucleation versus transurethral resection in the treatment of prostates larger than 40 gm: results of 2 years follow-up. Eur Urol 2006 ;50:569-73.
9. Elazayat EA, Habib EI, Elhilali MM. Holmium laser enucleation of the prostate: A size –independent new “gold standard”. Urology 2005; 66:108-13.
10. Kuntz RM, Ahyai S, Lehrich K). Transurethral holmium laser enucleation of the prostate compared with transvesical open prostatectomy : 3 years follow-up of a randomised trial. Proc SPIE 2006; 6078:11.
11. Tan AHH, Gilling PJ, Kennett KM, et al.. Long term results of high power holmium laser vaporisation (ablation) of the prostate. BJU Int 2003; 92:707-9.
12. Mottet N, Bourdon O, et al. A randomised comparison of transurethral electroresection and Ho: YAG laser vaporisation for symptomatic benign prostatic hyperplasia. J Endourol 1999;13:127-30.
13. Gilling PJ, Cass CB, Cresswell MD, et al. The use of holmium laser in the treatment of benign prostatic hyperplasia. J Endo Urol 1996; 5:459-61.
14. Tan AHH, Gilling PJ, Kennett KM, Westenberg AM, Frampton L, Fraundorfer MR. A randomized trial comparing holmium laser enucleation of the prostate (HoLEP) with transurethral resection of the prostate (TURP) for the treatment of bladder outflow obstruction secondary to benign prostate. J Urol 2003; 169:1465.
15. Gilling PJ, Kennett KM, Westenberg AM, et al. Holmium laser enucleation of the prostate (HoLEP) is superior to TURP for the relief of bladder outflow obstruction (BOO): A randomized trial with 2 years follow-up. J Urol 2003; 169:1465.
16. Tan AHH, Gilling PJ. Holmium laser prostatectomy: Mini reviews. BJU international 2003; 92: 527– 530.
17. Matlaga BR, Lingeman JE. Surgical management of upper urinary tract calculi. Campbell 9<sup>th</sup> ed 2007; 1383-1385.
18. Wolf JS. Urologic laser surgery. Smiths General Urology, McGraw Hill Int 2000; 451-462.
19. Das A, Gilling P, Fraunder M: Holmium laser resection of bladder tumours (HOLRBT) Techn Urol 1998; 4:12 .
20. Kuo RL, Paterson RF, Kim SC, Siqueira TM, Elhilali MM, Lingeman JE. Holmium laser enucleation of the prostate: A technical update. World Journal of surgical oncology 2003; 1(6): 1-9
21. Amy E, Krambeck, MD: Advantages and outcomes for Holmium laser Enucleation of the prostate performed for BPH Jan 2010, mayo clinic-physician update.
22. Friod NM. Potential applications of the erbium: YAG laser in endourology. J Endo Urol Nov 2001; 15(9) : 889-94.
23. Friod NM, Mrray KE. High power thulium fibre laser ablation of urinary tissues. J Endo Urol Jan –Feb 2005; 19(1): 25-31.

**Authors:**

1. MCPS, FCPS(surgery), FCPS(urology), Senior Urologist, CMH Dhaka.
2. FCPS(surgery). FRCS(edin), FRCS(glasgow), Dip(urol), Consultant surgeon general of Bangladesh Armed Forces.
3. FCPS (surgery), FCPS(urology), Urologist, CMH Dhaka
4. MCPS, FCPS (surgery) Trainee in Urology, CMH Dhaka
5. FCPS(surgery), MRCS(edin) Trainee in Urology, CMH Dhaka