

# OUTCOME OF NON-CLOSURE OF BUCCAL MUCOSAL GRAFT HARVEST SITE IN COMPARISON TO PRIMARY CLOSURE

MUHAMMAD HUMAYUN KABIR<sup>1</sup>, MOHAMMAD KHAIRUZZAMAN<sup>1</sup>, TANVIR AHMED<sup>1</sup>, MUHAMMAD HOSSAIN<sup>1</sup>

<sup>1</sup>Department of Urology, Bangabandhu Sheikh Mujib Medical University, Dhaka

## Abstract

**Objective:** To compare prospectively the outcome of non-closure of buccal mucosal graft harvest site in comparison to its' primary closure.

**Methods:** Patients who underwent BMG harvest for urethroplasty were randomized into 2 groups; in group 1 donor site was closed and in group 2 it was left open. Pain at BMG harvest site was the primary variable. Postoperative resumption to regular diet and difficulty in mouth opening were 2 other variables. After buccal mucosal graft harvesting, donor area was either closed (group 1) or left open and allowed to heal by second intention. In the postoperative period, visual analog score was to evaluate pain at donor area. Self made questionnaires were used to assess limitation to mouth opening and the time to resumption of liquid and solid diet.

**Results:** Thirty two patients were studied, 16 in each group from December 2012 to June 2014. Mean age among the two groups were almost same (closure group, 42.37 years Vs 41.26 years in nonclosure group). Mean stricture length was 4.75 cm in closure group and 7.53 cm in non-closure group. In closure group, BMG was harvested from single cheek in most of the patients but in non closure group, graft was harvested from both cheeks and also from lower lips in few patients. Mean post operative pain score was 5.06 and 3.68 at day 1 in group 1 and group 2, respectively ( $P < 0.008$ ) but as the days progressed, pain score in both groups became comparable. Return to oral intake in terms of liquid and solid diet was comparable between the groups. Difficulty with mouth opening was maximal during the first week with no difference among the two groups.

**Conclusion:** Pain appears to be worse in the immediate post operative period with suturing of the harvest site. There is no difference in long term morbidity whether the graft site is closed or left open. It may be best to leave buccal mucosa harvest sites unsutured.

**Keywords:** Buccal mucosa harvest, post operative morbidity.

Bangladesh J. Urol. 2017; 20(1): 26-30

## Introduction

The use of buccal mucosa grafts (BMG) for substitution urethroplasty is an established technique with durable long-term efficacy. Patients with both congenital and Although as early as 1941, Humby combined oral mucosa with a full-thickness graft for penoscrotal fistula closure<sup>1</sup> and observed success with only the buccal mucosa. Currently, buccal mucosa grafts are the

preferred tissue for substitution urethroplasty because of their physical characteristics and the avoidance of unnecessary genital dissection. Success rates for BMG urethroplasty range from 87% to 96%<sup>2</sup>. Buccal mucosa is most commonly harvested from the cheek, unilateral or bilateral, depending upon the length of graft required. An alternative to cheek is mucosa from the lower lip but its width limits the size of the graft, so it is used along with cheek mucosa when required length is more. Although the technique of harvesting buccal mucosa is straightforward and its efficacy in urethroplasty is beyond

**For correspondence:** Dr. Muhammad Humayun Kabir, Resident, Department of Urology, Bangabandhu Sheikh Mujib Medical University, E-mail: salim.hk@gmail.com

question, the optimal method for managing the intraoral defect is yet to be determined. Options include primary closure, closure by secondary intent, and defect coverage by some artificial means such as AlloDerm<sup>3</sup>. Conventionally the donor areas were used to be closed after the graft harvesting mainly because of concerns about the hemostasis and adequate healing of the raw area. Closure of the donor area may result in increased pain due to the stretching of the mucosal edges and poor cosmesis especially in lower lip. Closure of lip mucosa may also lead to eversion of vermillion and lip contracture<sup>4</sup>. For these reasons, many centers now routinely keep buccal mucosal graft donor area open and allow healing by secondary intention. The aim of this study was to compare the postoperative outcome between closure and nonclosure of the buccal mucosal graft harvest site.

**Materials and methods:**

It was a hospital based prospective clinical trial which was conducted at Department of Urology, BSMMU, Dhaka from the period of December 2012 to June 2014. All the male patients with stricture urethra attending the outpatient department of BSMMU hospital who were treated with oral mucosal graft urethroplasty were included in this study. Patients who had cognitive impairment, had history of oral malignancy and the patients who refused to participate in the study were excluded.

Total 32 patients were included in the study, 16 in each groups. Detailed history was taken and clinical examination was done. Demographic patient profile, stricture related characteristics like etiology, site, length of stricture and type of surgery performed were noted. Pain at BMG harvest site was the primary variable. Interval to resume a regular diet and interval to full mouth opening were two other variables..

The aims and objectives of the study along with its procedure, risks and benefits of this study were explained to the study subjects in an easily understandable local language. A written informed consent was taken from all the study subjects. Under G/A with endo-tracheal intubation, buccal mucosa was harvested from inner cheeks and lower lip depending upon the length required following standard protocol. Perfect hemostasis was achieved with electrocautery and an adrenalin soaked gauge piece was left over the harvest site for about 4 to 6 h. (adrenalin solution 1 in 100,000). After harvesting the graft, the decision to close or leave open the donor harvest site to heal by secondary intention was left to

individual surgeon preference. In group 1 patients, the mucosal edges were approximated with continuous interlocking sutures using 3 ‘O’ vicryl. In this group of patients, during initial dissection submucosal dissection was extended at least 0.5 cm beyond the superior and inferior wound edges to release tension during primary closure. In group 2, after achieving adequate hemostasis, graft harvest area was left open packing with adrenaline soaked gauge pack which was removed few hours later. The harvested tissue was then inspected and measured. It was prepared by vigilantly removing any muscle, salivary gland, or subcutaneous adipose tissue remnants from the underside of the graft using sharp scissors. Care was taken to avoid accidental perforations and to maintain uniformity of the thickness of the tissue during this process. All patients were prescribed chlorhexidine oral rinses in the postoperative period to control microbiologic colonization. A second-generation cephalosporin was administered intravenously before starting operation and continued postoperatively.

Patients were given self-made questioners to assess pain at donor site. Pain score was recorded for initial 5 days once daily using visual analog score. Return to liquids and then semi solid to solid diet and any difficulty in mouth opening in post-operative period starting from day 1 were also noted. Same parameters were noted at follow up at 3 months follow up visit.

**Result and observation:**

**Table-I**  
*Distribution of the patients by age (n=32)*

Age	Closure group (n=16)	Non closure group (n=16)
Mean age (Years)	42.37	41.62
Std. Deviation	10.53	13.03
Minimum age (Years)	29.00	16.00
Maximum age (Years)	63.00	67.00

**Table-II**  
*Comparison of stricture length between the study groups (n=32)*

Stricture length (cm)	Closure group (n=16)	Non closure group (n=16)
Mean	4.75	7.53
Std. Deviation	1.05	2.42
Minimum	3.5	3.7
Maximum	7	12

Outcome of Non-closure of Buccal Mucosal Graft Harvest site in Comparison to Primary Closure

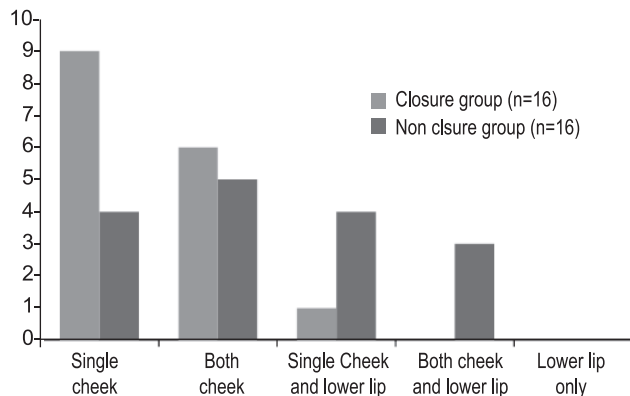


Fig-1: Graft harvest site between two groups

**Table-II**  
Comparison of postoperative pain scores between the two groups (n=32)

Pain score	Closure group (n=16)		Nonclosure group (n=16)		P value
	Mean	Std. deviation	Mean	Std. deviation	
POD 1	5.06	1.12	3.68	1.08	.008
POD 2	4.18	0.98	3.31	0.60	.014
POD 3	3.5	0.73	2.50	0.82	.002
POD 4	2.56	0.81	2.00	0.63	.070
POD 5	1.5	0.73	1.56	0.63	.817
At 3 months	0.12	0.34	0.19	0.10	.669

**Table-IV**

Comparison of postoperative resumption to regular diet (n=32)

Characteristics	Closure group (n=16)	Nonclosure group (n=16)	P value
Tolerates liquid diet at POD 1	14	15	.719
Tolerates solid diet at POD 3	14	14	.598

Paired t- test

**Table-V**

Comparison of difficulty in postoperative mouth opening (n=32)

Characteristics	Closure group (n=16)	Nonclosure group (n=16)	P value
No of patients with difficult mouth opening at POD 1	15	12	.083
No of patients with difficult mouth opening at POD 3	12	10	.164
No of patients with difficult mouth opening at POD 5	3	2	.333
No of patients with difficult mouth opening at 3 months	1	0	.333

Paired t- test

**Discussion:**

For many years, oral mucosa has been used for reconstructing oral and maxillofacial defects, repairing the conjunctival mucosa of the eye, oral pharyngeal reconstructive surgery and reconstructing vaginal defects[5]. Buccal mucosal graft currently enjoys widespread use as a viable and highly applicable source of tissue for reconstruction of long segment urethral strictures. Advantages of buccal mucosa as a free graft are that it is hairless, has a thick elastin rich epithelium making it tough and easy to handle and also having thin and highly vascular lamina propria that facilitates inosculation and imbibition[8]. Although the buccal

mucosa is the graft of choice in many circumstances, only few data about the morbidity of the harvest site are available. Traditionally many centers perform donor site closure to reduce the wound size and eliminate the potential complications related to bleeding. After buccal mucosa harvest patient experiences some pain and discomfort both in the donor area and also in the perineum but this usually resolves within 3 weeks postoperatively[7,8].

During this study, no major perioperative complications occurred in either group with respect to the graft harvest site. One patient developed minor bleeding from the graft harvest site which was controlled by compression for few minutes in the postoperative ward.

Muhammad Humayun Kabir et al

Discrepancy regarding the stricture length and consequently, harvested graft length and graft surface area were noted among the two groups. In closure group, mean stricture length was 4.75 ( $\pm$  1.04) cm (range 3.5 - 7 cm) and harvested graft length was 6.58 ( $\pm$  1.42) cm (range 3.5 - 7 cm) where as in nonclosure group, mean stricture length was 7.53 ( $\pm$  2.42) cm (range 4 - 8.8 cm) and mean graft length was 9.65 ( $\pm$  3.01) cm (range 5-15.2 cm). Consequently, harvested graft surface area was significantly more in non closure group (24.31  $\pm$  9.38 Sq. cm vs 14.99  $\pm$  3.72 Sq. cm, P value 0.002). The cause of this discrepancy was paucity of study subjects and that all these operations were not done by a single surgeon. Patient with short stricture length in whom harvested graft length was small was donor area closed. In contrast, patients with panurethral stricture or with long stricture length where graft harvest was larger were donor area left open and allowed for healing by secondary intention. This discrepancy obviously has an impact on the study result.

When assessing early postoperative pain, it was noted that pain was maximal at first post operative day in both the groups. Mean pain score was significantly higher in the group 1 in which donor site was closed i.e., 5.06 as compared to 3.6 in group 2 where the graft donor site was left open ( $P < 0.008$ ). This significance in pain score in closure group persisted for first 3 postoperative days after which it became insignificant. This is in spite of the fact that the mean area of the graft harvested in group 2 was significantly more than in group 1 and six patients in group 2 had the graft harvested from lower lip also. This shows that not suturing the donor area leads to lesser pain whether larger grafts were harvested or graft harvested from lower lip. Patient in whom donor site is closed may complain of more pain due to tight approximating sutures. In the prospective study by Wood et al, the mean pain score for patients with donor site closure was significantly higher than that for patients without donor site closure ( $P < 0.01$ ) [9]. But in that study the improved pain scores experienced by the nonclosure group in the early postoperative period were followed by an increase in pain midway through the first week and became statistically greater than the closure group until day 7 postoperatively. They explained that in patients with nonclosure of the donor area might require more time to accumulate the wound tension necessary to incite significant pain.

At 6 months, no difference was found in the pain scores between the 2 study groups [9]. A study by

Muruganandam K et al<sup>4</sup>. found a similar outcome in the early and late postoperative period. Jang et al<sup>8</sup> did a retrospective comparison assessing postoperative intraoral morbidity between lower lip and inner cheek buccal mucosal harvests in 40 patients, with a total 50 buccal mucosa graft harvests. All but 2 of the cheek harvests were closed primarily, while all lower lip harvests were left to heal by secondary intent. The author used a similar 10-point analog pain scale like us and concluded that closure by secondary intent to be preferable. It should, however be emphasized that this nonclosure pertains to the lower lip rather than the inner cheek. Greenwell *et al.* [10] assessed the morbidity of buccal mucosa graft and the effect of non-suture of the graft site on postoperative pain. They concluded that the donor site can be left unsutured to lessen pain. This contrasts with the findings of Dublin and Stewart, where all the donor sites were closed and about 32% of the patients had tightness of the mouth. Another prospective study by Barbagliet al [11]. on 350 patients who underwent oral mucosa harvest from single cheek concluded that harvesting oral graft from a cheek with wound closure is a safe procedure with a high patient satisfaction rate. They also recommended harvesting the graft in an ovoid-shaped fashion, and the size of the graft should not exceed 4 cm in length and 2.5 in width. Steinhauser<sup>12</sup> had earlier observed that techniques involving full-thickness mucosal grafts leave a defect that must be closed by sutures, and this can cause scarring and contraction with decreased mouth opening.

Measurement of postoperative pain is not an exact science as each patient has different pain thresholds and perceptions. It is difficult to comment as to whether the statistically significant reduction in pain after nonclosure of the harvest site is clinically significant but it can be assumed that donor site suture and consequent tightness are the major causes of postoperative pain in graft harvest site.

Restriction of mouth opening seems to be a common problem in the early postoperative period. The majority of patients in both groups had difficulty in opening the mouth at post operative day 1. On postoperative day 1, 15 (93.5%) of 16 patients in the closure group reported some difficulty in mouth opening compared with 12 (75%) of 16 patients in the non closure group ( $P = .083$ ). In postoperative day 3, 12 (75%) patients reported difficult mouth opening in the closure group whereas in the non closure group, it was 10 (62.5%) ( $P = .164$ ). All patients, except 1 in closure group, reported full mouth opening

by the end of the 3-month study period. Tolstunov et al<sup>7</sup> measured the preoperative mouth opening preoperatively, and then after 1 week, 2-3-6 weeks and 6 months. Almost all patients had difficulties with mouth opening the first week postoperatively, but all patients returned to their preoperative mouth opening; by the third month, no patients in the study of Tolstunov et al. had restriction of mouth opening.

Immediate resumption to liquid diet was seen in all except two patients in closure group and one patient in nonclosure group. All patients except two in both the groups were able to resume normal diet by the end of third post operative day. Similar observations have been reported by others. In an study by Wood et al<sup>9</sup>. showed that after oral mucosal graft harvest for urethroplasty, irrespective of closure or non closure 90% patients were able to consume oral fluids within 24 hours, with all reporting oral fluid consumption within 1 week, and 88% were able to eat soft solids within 2 days and 100% within 2 weeks. Resumption of normal diet was achieved by 77% patients within 1 week, although return to normal diet was delayed up to 3 weeks in the remainder.

#### Limitations of the study

1. Baseline characteristics like stricture length, harvested graft surface area could not be standardized in both the groups which may have affected the study result.
2. The use of a nonvalidated scale to measure the secondary outcomes (return to a regular diet, full mouth opening in the postoperative period) was also a limitation of this current study.

#### Conclusions

Oral mucosal graft harvesting is a safe procedure with minimal morbidity. After harvesting the graft, donor site can either be closed or laid open. Primary closure of the donor area can lead to an increased early postoperative pain perception though long term results are the same. So it is our conclusion that keeping the donor area unsutured and allowing it to heal by secondary intention is better.

#### References:

1. Humby G: (1941) A one-stage operation for hypospadias. *Br J Surg* 29: 84.

2. Jamal JE, Kellner DS, Fracchia JA, et al. (2010) A randomized prospective trial of primary versus AlloDerm closure of buccal mucosal graft harvest site for substitution urethroplasty. *Urology*;75: 695-700.
3. St. Martin BA, Rourke K. (2009) Closure vs non-closure of buccal mucosal graft harvest site: a randomized controlled trial. *J Urol*; 181(suppl):15 [abstract: 39].
4. Muruganandam K, Dubey D, Gulia AK, et al (2009) Closure versus nonclosure of buccal mucosal graft harvest site: a prospective randomized study on postoperative morbidity. *Indian J Urol*; 25:72-75.
5. Markiewicz MR, Lukose MA, Margarone JE 3rd, Barbagli G, Miller KS, Chuang SK. (2007) The oral mucosa graft: A systematic review. *J Urol*;178: 387-94.
6. Duckett JW, Coplen D, Ewalt D, et al.( 1995) Buccal mucosal urethral replacement. *J Urol*;153:1660-3.
7. Tolstunov L, Pogrel A, McAninch JW. (1997) Intraoral morbidity following free buccal mucosal graft harvesting for urethroplasty. *Oral Surg Oral Med Oral Pathol Oral Radiol Endod*;84:480-2.
8. Jang TL, Erickson B, Medendorp A, Gonzalez CM.( 2005) Comparison of donor site intraoral morbidity after mucosal graft harvesting for urethral reconstruction. *Urology*;66:716-20
9. Wood DN, Allen SE, Andrich DE, Greenwell TJ, Mundy AR.(2004) The Morbidity of buccal mucosal graft harvest for urethroplasty and the effect of nonclosure of the graft harvest site on postoperative pain. *J Urol*;172:580-3.
10. Greenwell TJ, Venn SN, Mundy AR.( 1999) Changing practice in anterior urethroplasty. *BJU Int*;83:631.
11. Barbagli G, Vallasciani S, Romano G, Fabbri F, Guazzoni G, and Lazzeri M. (2010) Morbidity of Oral Mucosa Graft Harvesting from a Single Cheek. *European Urology*; 58: 33 – 41.
12. Steinhäuser EW.( 1969) Free transplantation of oral mucosa for improvement of denture retention. *J Oral Surg*; 27:955-61.