

# MODIFIED ILEAL NEOBLADDER: EXPERIENCE OF 37 CASES

MIR EHTESHAMUL HAQUE<sup>1</sup>, IBRAHIM KAISAR<sup>2</sup>, NELSON TAPOSH MONDAL<sup>3</sup>, MD. FAZLUL HAQ SIDDIQUE<sup>4</sup>, MOHAMMAD AFZALUR RAHMAN<sup>5</sup>

## Abstract

*Bladder cancer is the second most common malignancy of genitourinary tract. About 20% cases are muscle invasive and most of the non-muscle invasive bladder cancer progressed to muscle invasion with time. The standard care for organ confined muscle invasive bladder cancer is radical cystectomy followed by urinary diversion. Orthotopic bladder substitution is considered standard urinary diversion after radical cystectomy in patients who have no urethral malignancy and intact external urethral sphincter.*

*Neobladder constructed from ileum as described by Studer is considered standard and followed by most centers worldwide since 1985. We modified the procedure to improve the outcome and minimize post-operative complications by reducing the length of ileum used for construction of neobladder in 37 patients. Voiding, storage function and complications were evaluated during follow-up period up to 24 months after surgery. Three patients died during follow-up period of which 2 from metastatic disease and one from unrelated cause. Daytime and night-time continence rates were 86.49% and 78.38% respectively. Average functional capacity (437ml), maximum flow rate(15.7ml/s) and mean post void residual urine (44ml) during the period of evaluation. Clean intermittent self-catheterization needed in 67.57% patients due to incomplete emptying during early postoperative period but after 3 months most of the patients learnt to void without any aid. Upper tract dilatation found in one patient due to stricture at urethrovesical junction and required endoscopic incision and dilatation later. 12 patients had an urodynamic study at 12 months after surgery and found low pressure reservoir with small residual urine in all cases.*

*Modified ileal neobladder is a safe and reliable procedure with satisfactory short-term result.*

*Bangladesh J. Urol. 2019; 22(1): 20-24*

## Introduction

Urothelial carcinoma of urinary bladder is one of the commonest genitourinary malignancy. Although most of the urothelial carcinoma of urinary bladder are superficial in nature, about 20% are muscle-invasive and require radical cystectomy to control the local disease followed by urinary diversion. Incontinent urinary diversion like ileal conduit are relatively simple

procedure with minimal complications rate but most patients prefer continent urinary diversion in terms of psychological benefits and near normal body image of the patients. Orthotopic neobladder is the best form of continent urinary diversion in terms of near normal voiding by preserving the natural continence mechanism. Neobladder constructed from ileum as described by Studer is considered the best till now and followed by most centers worldwide since 1985. Although Studer's ileal neobladder can be constructed easily with good functional outcome and relatively low complication rates, many modifications of the procedure have been performed by Studer and other urologists of different centers worldwide to minimize the complications and for better functional outcome<sup>1,2,3,4</sup>. We modified the procedure by reducing the length of ileum used for construction of neobladder and evaluate the short-term result of the procedure.

1. Consultant-Urology; Apollo Hospitals Dhaka
2. Consultant; Urology and Transplantation Foundation of Bangladesh, Dhaka
3. Associate Professor (Department of Medicine); Rangpur Community Medical College, Rangpur
4. Assistant Professor (Department of Urology), Mymensingh Medical College and Hospital; Mymensingh
5. Assistant Professor (Department of Urology), Mymensingh Medical College and Hospital; Mymensingh

**Correspondences:** Mir Ehteshamul Haque, Consultant-Urology; Apollo Hospitals Dhaka

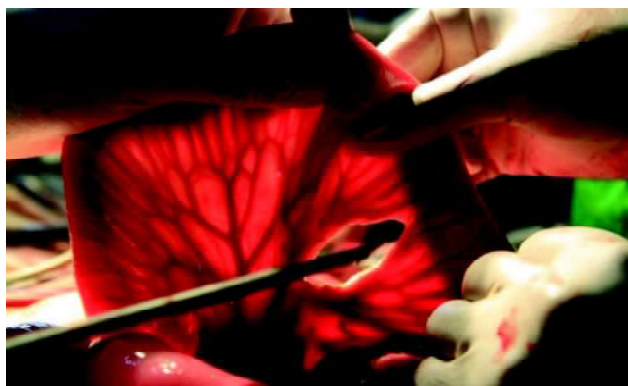
**Received:** 05 August 2018

**Accepted:** 15 November 2018

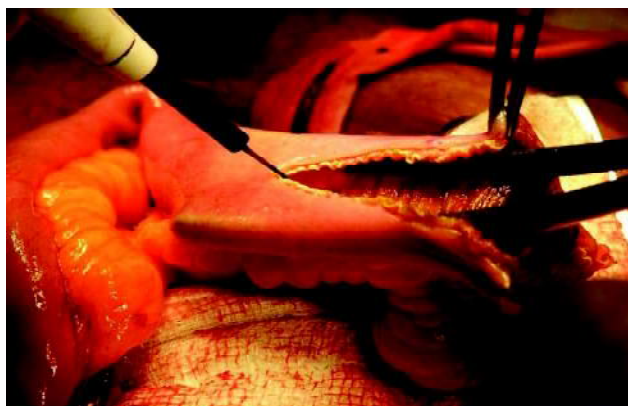**Materials and methods**

The study was conducted in a private medical hospital of Dhaka, Bangladesh between the periods of January 2004 to December 2015. All patients underwent a radical cystectomy for muscle-invasive bladder cancer followed by construction of ileal neobladder using 40 cm of ileum according to Studor’s ileal neobladder with some modifications and were followed up for at least 3 months after surgery were included in the study. Voiding, storage function and complications were evaluated. An open radical cystectomy and pelvic lymphadenectomy were performed by lower midline incision according to standard procedure. Every effort was made to preserve the maximum length of both ureters for easy implantation into the neobladder. The distal margin of ureters sent for histopathology. The technique of neobladder construction described briefly as follows. To construct the reservoir, a 40 cm of ileal segment about 20-25 cm proximal from the ileocaecal valve was isolated and washed with normal saline (Figure 1 and 2). Ileal continuity was reestablished with extramucosal interrupted sutures with 5/0 monocryl or vicryl. Mesenteric window was closed properly to minimize the chance of internal herniation. The whole isolated ileum was detubularized along the

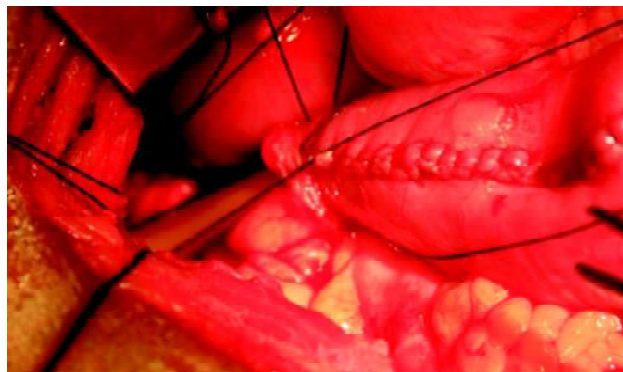
antemesenteric border without keeping any afferent loop. Opened up bowel loops were joined by suturing the margins with 4/0 vicryl or dexon to make a pouch (figure 2 and 3). The ureters were implanted on the either upper corner of the neopouch separately keeping ureteral stents in situ. Apex of the neobladder was anastomosed with urethra over a 20/22 Fr Tri-channel Foleys catheter with 6 interrupted sutures using 2/0 vicryl (Figure 3). A tube drain was inserted in the retropubic space and kept for 2-3 days. Urethral catheter was kept for 2-3 weeks. Liquid diets were allowed from 3<sup>rd</sup> post-operative day followed by normal diet. Follow-up of patients were performed by voiding habits and urinary continence (questionnaire), USG of urinary tract, Renal function tests, Urine R/E and C/S, Uroflowmetry and urodynamic studies and Retrograde urethrography and micturating cystourethrography.



**Fig.-1:** A 40 cm ileum dissected for the neobladder



**Fig.-2:** Isolated Ileum opened in antimesenteric border



**Fig.-3:** Neobladder anastomosed with urethra over a trichannel Foley’s catheter

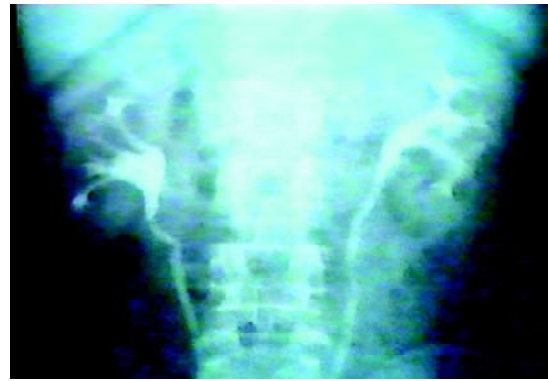**Results:**

**Table-I**  
*Demographic and clinical variables with bladder cancer*

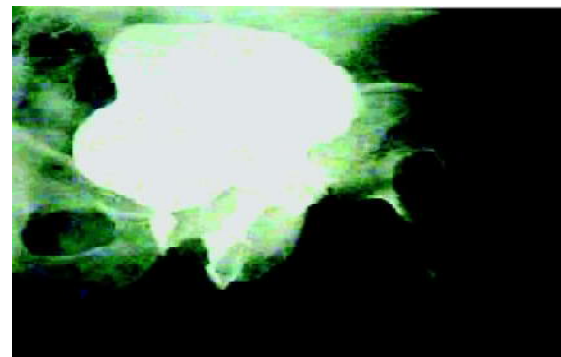
Characters	Number
Total number of patients	37
Male: female	36:1
Median age with range	55(39-74) years
Median follow-up periods	22(13-57) months
Pathological stage after surgery	
pT1	0(00%)
pT2	21(56.75%)
pT3	16(43.25%)
Pathological N stage	
pN0	32(86.5%)
pN1	5(13.5%)
Co-morbidities	
DM	9(24.3%)
HTN	4(10.8%)

**Table -II**  
*Outcomes after surgery*

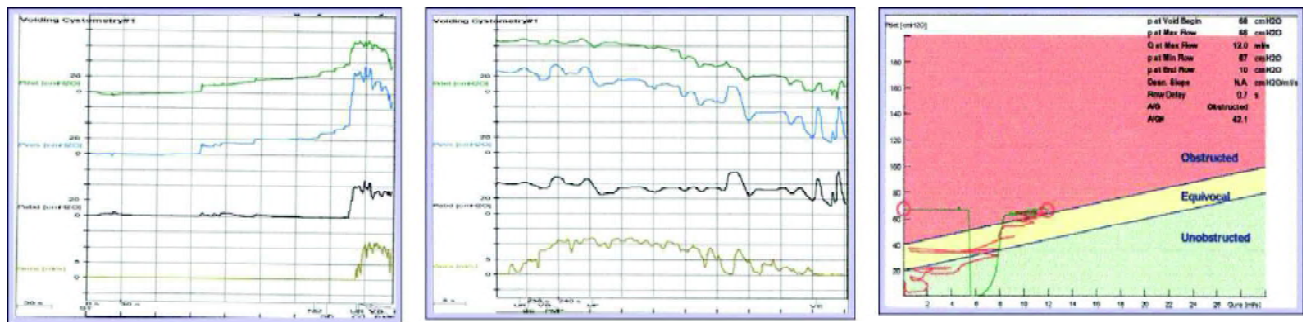
Characters	Number (%)
<b>Urodynamic outcomes</b>	
• Average neobladder capacity	250-500ml
• Average voided urine volume	150-400ml
• Post void residual urine volume	50-320ml
• Average maximum urine flow rate	12-30ml/s
<b>Urinary continence</b>	
• Day time continence	32(86.5%)
• Nighttime continence	29(78.4%)
Clean Intermittent Self Catheterization (CISC) required	25(67.6%)
<b>Complications</b>	
• Wound infection	9(24.3%)
• Upper Urinary tract dilatation	1(2.7%)
• Urinary leakage	2(5.4%)
• Acute MI	1(2.7%)



**Fig.-4:** Post-operative IVU film showing normal renal excretion



**Fig.-5:** Post-operative MCU showing good capacity bladder with no VUR



**Fig.-6:** Urodynamic study showing low pressure system

During last 10 years we preformed 37 cases of radical cystectomy as a single surgical team. Among the 37 patients 36 were male patients and one female patient. The median age of the patients was 55 years (range 39-74). The median follow-up period was 22 months (range 13-57) (Table 1). All male patients underwent Radical cystoprostatectomy and bilateral pelvic lymphadenectomy and in female patients anterior exenteration was performed. All patients had muscle invasive urothelial carcinoma clinical T stages were T2 and T3. Eighteen patients had diabetes mellitus, 6 had

hypertension and 4 patients had other comorbidities. None had bad physical or mental dexterities. Pathological T2 stage was found in 21 patients and T3 stage was found in 16 patients. Pathological N0 stage was found in 32 patients and in 5 cases were in N1 stage. None had preoperative neoadjuvant chemotherapy or radiotherapy. Three patients died during follow-up period, one was due to disease progression and the other 2 were due to other comorbid diseases. 8 patients had lost follow-up as we failed to keep contact with them. Eighteen patients were

evaluated with urodynamic study at 12 months after surgery (Figure 6). All showed good capacity neobladder with small amount of post void residual urine (Figure 5). All patients followed up with USCD (Ultrasound cystodynamogram) 6 monthly. Neobladder capacity was found 250-500ml, voided urine volume was 150-400ml, and post void residual urine volume was 50-320ml. Average maximum flow rate was 12-30ml/sec. Day time continence was found in 86.5% (32) and Nighttime continence found in 78.4% (29) patients. Although most of the patients were happy with passing urine through normal urethral passage, CISC was required in 67.6% (25) patients sometimes during follow-up period. Severe wound infection requiring surgical intervention had occurred in 5.4% (2) patients. Minor wound infection occurred in 3 patients which were managed with conservative measures and wound dressing. Although overall patients' acceptance found satisfactory, upper urinary tract dilatation was found in 2.7% (1) patient. Urinary leakage causing collection in retroperic space found in 5.4% (2) patients which were managed by keeping the drain for prolonged period. 2.7% (1) patient developed myocardial infarction in postoperative period and survived with conservative treatment (Table 2).

#### Discussion:

Urothelial carcinoma is a common malignancy of urinary bladder. For non-muscle invasive tumors, bladder preservation is possible but for muscle-invasive tumors Radical cystectomy is the best surgical modality as a curative measure<sup>5,6</sup>. The main problem comes after Radical cystectomy. Since 1900 many surgeons were searching for the best option to replace the bladder. Ureterosigmoidostomy was the oldest form of urinary diversion introduced by Simon in 1852 and considered the diversion of choice until late 1950s although it has got many complications and comorbidities<sup>7,8,9</sup>. In 1950 Bricker introduced Ileal conduit which was much better, technically simple and reliable form of urinary diversion and soon became widely accepted form of urinary diversion till now<sup>10,11</sup>. Although Ileal conduit was considered gold standard in 1980s, it's a form of incontinent diversion which is not very acceptable for the patients<sup>12</sup>. In 1950, Gilchrist and coworkers introduced caecal reservoir as a form of continent catheterizable pouch, later modified by Koch and associates in 1982 Many forms of incontinent and continent urinary diversions are available till now but with the cost of impaired body image and patients have to use urine collection bags or draining tubes to drain

urine<sup>13,14</sup>. Overall quality of life deteriorates and sometimes totally unacceptable for patients and their spouses.

The introduction of orthotopic neobladder is a great option for the urologists to offer their patients and it has become "gold standard" reconstructive approach after radical cystectomy. In 1979, Camey and Le Duc first reported their experience with orthotopic bladder substitute using intact segment of ileum which was associated with high pressure system. Later Camey, Hautmann and Skinner introduced many modifications of neobladder<sup>15,16,17</sup>.

With carefully selected patients and proper perioperative care orthotopic bladder can be offered almost all patients after radical cystectomy. The absolute contraindications are patients with urethral involvement by the tumor, severe renal or hepatic insufficiency, compromised gastrointestinal function and severe inflammatory bowel disease. Orthotopic neobladder may not be very suitable for patients with impaired mental and physical dexterity. Orthotopic neobladder is also a very good substitute in female patients after anterior exenteration.

Orthotopic neobladder made of ileum, introduced by Studer and associates was established in 1984 and now the most popular technique worldwide. The advantages of this technique are relatively simple procedure. In Studer bladder about 65 cm ileum was used initially but overtime the lesser length of ileum used to minimize longtime complications rate. The longer the intestinal segment is used the larger the pouch can be constructed to hold more urine. The afferent loop used by Studer and associates to overcome the reflux nephropathy. But later it was observed that the detubularized ileum does not produce high pressure to cause reflux nephropathy and afferent loop did not prevent those complications. Moreover, longer intestinal loop is associated with more metabolic complications as the absorptive area increases with longer loop of bowel. In our institute, we have modified the procedure by using 40 cm of ileum and omitting the proximal afferent loop. These two modifications have made the operative procedure even simpler and the two ureters implanted in either corner of the neobladder without need to mobilize the ureters which can be kept on the same native side of the body. 37 cases were performed in our institute by a same surgical team between the periods of 2004 to 2015. Although we could not follow-up all patients regularly

for proper metabolic evaluation due financial and other communication problems, our results have shown promising outcome with the technique.

### Conclusion:

Modified ileal neobladder using short segment of ileum is a safe and reliable procedure with satisfactory short-term results. Randomized study with large number of patients and longtime follow-up are required to establish the procedure.

### References:

1. Studer UE, Ackermann D, Cassanova GA, Zingg EJ. Three years' experience with an ileal low-pressure bladder substitute. *Br J Urol* 1989; 63: 43–52
2. Kock NG, Ghoneim MA, Lycke KG, Mahran MR. Replacement of the bladder by the urethral Kock pouch: functional results, urodynamics and radiological features. *J Urol* 1989; 141: 1111–6
3. Melchior H, Spehr C, Knop-Wagemann I, Persson MC, Junemann KP. The continent ileal bladder for urinary tract reconstruction after cystectomy: a survey of 44 patients. *J Urol* 1988; 139: 714–8
4. Hautmann RE, Miller K, Steiner U, Wenderworth U. The ileal neobladder: 6 years of experience with more than 200 patients. *J Urol* 1993; 150: 40–5
5. Singh V., Yadav R., Sinha R. J., Gupta D. K. Prospective comparison of quality-of-life outcomes between ileal conduit urinary diversion and orthotopic neobladder reconstruction after radical cystectomy: a statistical model. *BJU International*. 2014;113(5):726–732. doi: 10.1111/bju.12440.
6. Cerruto M. A., D'Elia C., Siracusano S., et al. Systematic review and meta-analysis of non RCT's on health-related quality of life after radical cystectomy using validated questionnaires: better results with orthotopic neobladder versus ileal conduit. *European Journal of Surgical Oncology*. 2016;42(3):343–360.
7. Goodwin WE, Scardino PT. Ureterosigmoidostomy. *J Urol*. 1977 Jul;118(1 Pt 2): 169–174.
8. Macfarlane MT, Lattimer JK, Hensle TW. The unheralded hazard of ureterosigmoidostomy. *Pediatrics*. 1979 Nov;64(5):668–671
9. Arakawa K, Ishihara S, Kawai K, et al. Asynchronous bilateral anastomosis site sigmoid colon cancer after ureterosigmoidostomy: a case report. *World Journal of Surgical Oncology*. 2016; 14:180. doi:10.1186/s12957-016-0934-1.
10. Lee RK, Abol-Enein H, Artibani W, et al. Urinary diversion after radical cystectomy for bladder cancer: options, patient selection, and outcomes. *BJU Int* 2014; 113:11–23.
11. Colombo R, Naspro R. Ileal conduit as the standard for urinary diversion after radical cystectomy for bladder cancer. *Eur Urol Suppl* 2010; 9:736–744.
12. Joung K-W, Kong Y-G, Yoon S-H, et al. Comparison of postoperative acute kidney injury between ileal conduit and neobladder urinary diversions after radical cystectomy: A propensity score matching analysis. *Mubarak. M, ed. Medicine*. 2016;95(36): e4838. doi:10.1097/MD.0000000000004838.
13. Ashken MH. Continent ileocaecal urinary reservoir. *Journal of the Royal Society of Medicine*. 1978;71(5):357-360.
14. Urh A, Soliman PT, Schmeler KM, et al. Postoperative outcomes after continent versus incontinent urinary diversion at the time of pelvic exenteration for gynecologic malignancies. *Gynecologic oncology*. 2013;129(3):580-585. doi: 10.1016/j.ygyno.2013.02.024.
15. Chang DTS, Lawrentschuk N. Orthotopic neobladder reconstruction. *Urology Annals*. 2015;7(1):1-7. doi:10.4103/0974-7796.148553.
16. Aleksic P, Bancevic V, Milovic N, Kosevic B, Stamenkovic DM, Karanikolas M, et al. Short ileal segment for orthotopic neobladder: A feasibility study. *Int J Urol*. 2010; 17:768–73.
17. Ahmadi H, Skinner EC, Simma-Chiang V, Miranda G, Cai J, Penson DF, et al. Urinary functional outcome following radical cystoprostatectomy and ileal neobladder reconstruction in male patients. *J Urol*. 2013; 189:1782–8.