

# INFECTED URACHAL CYST IN A YOUNG FEMALE: A CASE REPORT

SHAFIQR RAHMAN<sup>1</sup>, MOHAMMAD ABDUL AZIZ<sup>1</sup>, MIRZA MAHBUBUL HASAN<sup>1</sup>

## Abstract:

*The urachus is a tubular structure that is patent during gestation. The lumen normally closes at about the twelfth week of gestation and obliterates completely. Patent urachal anomalies are usually detected in childhood<sup>2,3</sup>. In adults they occur very rarely and the presentation and diagnosis may be occasionally challenging. We present and discuss the case of an infected urachal cyst found in a 25 year old female.*

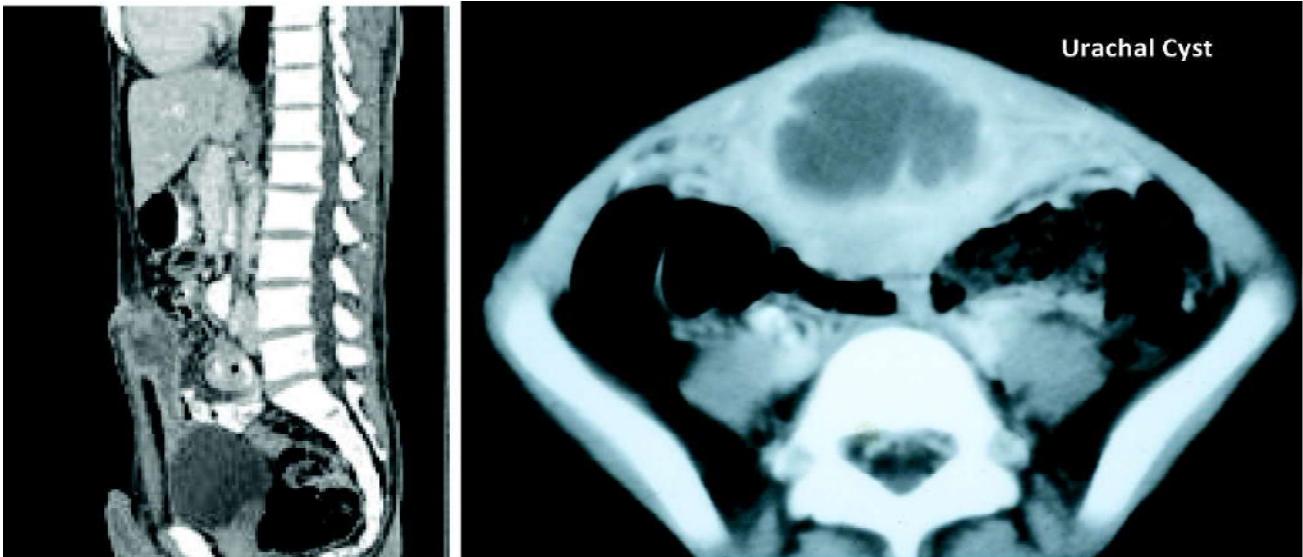
*Bangladesh J. Urol. 2019; 22(1): 100-102*

## Case Report:

A 25 year old female presented with lower abdominal pain and fever which lasted for a few days. Her physical examination revealed periumbilical tenderness, erythema. The laboratory tests showed neutrophilic leukocytosis. Ultrasound scan suggested the presence of an abscess within the anterior abdominal wall below umbilicus. A CT scan confirmed the presence of an

infected cyst in the midline of the abdominal wall, with no communication with the bladder. The patient was given antibiotics and prepared for surgery. During laparotomy, a urachal cyst with the cuff of the bladder dome were removed. Recovery was unremarkable. The patient was discharged four days after surgery. Histopathology revealed benign urachal cells with no signs of malignancy.

## Urachal Cyst



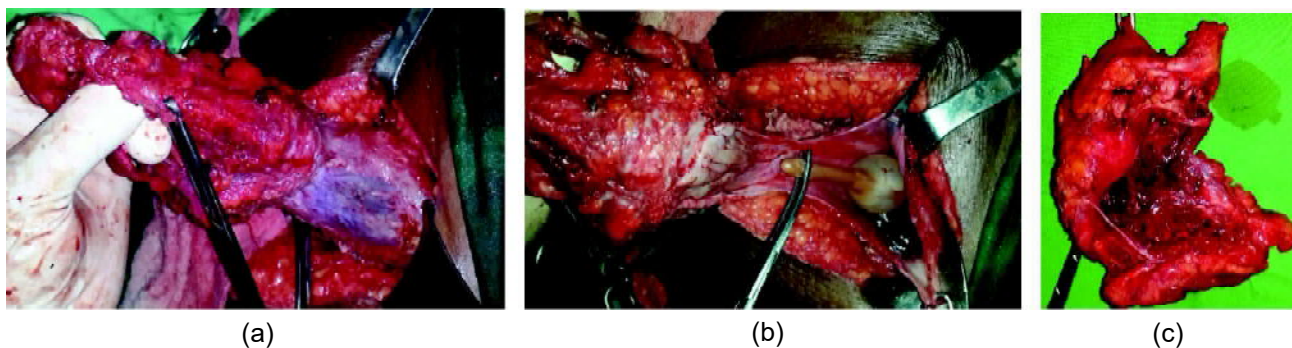
**Fig.-1: CT scan of KUB**

1. Department of Urology, BIRDEM General Hospital, Dhaka

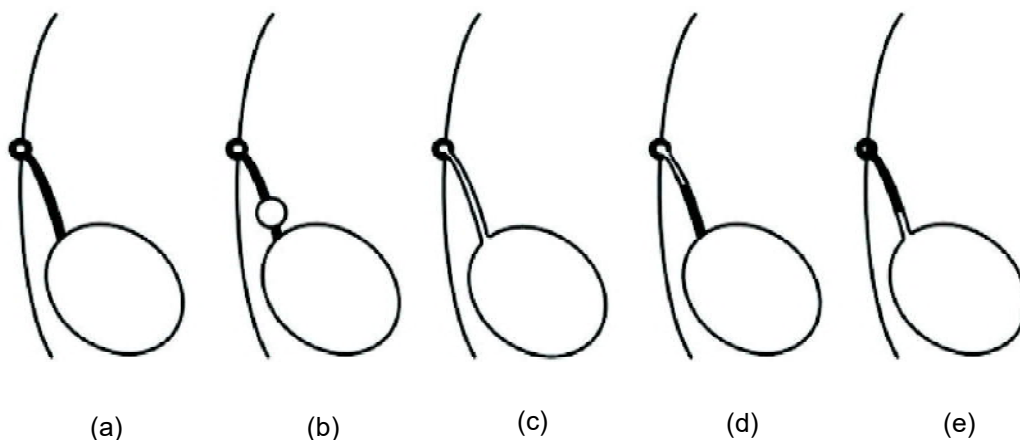
**Address of Correspondence:** Dr. Shafiqur Rahman, Associate Professor, Department of Urology, BIRDEM General Hospital, Dhaka. E-mail: shafiqur04@gmail.com

**Received:** 05 August 2018

**Accepted:** 15 November 2018



**Fig.-2:** Per-operative pictures of urachal cysts



**Fig.-3:** Diagram illustrating different types of urachal anomalies. A- Normal obliteration of the urachal lumen. B- Urachal cyst. C- Patent urachus. D- Urachal sinus. E- Urachal diverticulum<sup>3</sup>.

**Discussion**

The urachus is a fibrous remnant of the cloaca that in adult, connect the dome of the bladder with anterior abdominal wall. The cloaca, in the fetal life, is an extension of the urogenital sinus and allantois, and is derived from the yolk sac<sup>1,2</sup>. After birth it obliterates, forming the median umbilical ligament. Otherwise, it may present variably: a urachal cyst, a part of the urachal canal without any patent connection with the bladder or the umbilicus, a patent urachus communicating the bladder with the umbilicus, a urachal sinus which is a form of a cyst communicating with the umbilicus or a urachal diverticulum, a structure which opens within the bladder<sup>3-5</sup>.

Those found in older patients require management because of a greater risk for infection, and an increased risk of neoplastic differentiation<sup>6</sup>. The most commonly observed and managed urachal anomalies in children are: urachal cyst (54%), urachal sinus (30%), patent urachus or vesicourachal diverticulum. Modes of

presentation differ from those seen in children. Urachal cancer (51%) and urachal cyst (35%), which is usually infected, are the most frequent modalities diagnosed in adults<sup>7</sup>. Some patients with urachal remnants are asymptomatic, but still carry a high risk for infection or cancer. Abdominal pain can be the only symptom of disease, and can mimic an acute abdomen due to appendicitis or Meckel’s diverticulum<sup>9</sup>. Ultrasound can be helpful, but not sufficient. CT is the most important in the diagnostic work-up. It reveals the type of urachal anomaly with a sufficient degree of accuracy. However, differentiation between the benign urachal remnant and urachal cancer may be difficult due to unclear contrast enhancement during CT, even though the presence of calcifications is suggestive of malignancy<sup>10</sup>. Sixty seven percent of adults who presented with a urachal mass at the time of diagnosis had cancer. Among them, 57% had calcifications seen on imaging<sup>4,8</sup>. Ashley et al. found that patients older than 55, who experienced an episode of hematuria, were at greatest risk of having

urachal malignancy, most commonly an adenocarcinoma<sup>9</sup>. In our case, there was no suspicion for malignancy due to the patients' ages, negative history suggestive of malignancy (hematuria) and CT scans. Therefore, cystoscopy was not performed. When urachal cancer cannot be excluded (hematuria and mass seen at the bladder dome on imaging) cystoscopy with biopsy and urine cytology should be done. Cytology is positive in 38% of patients with urachal carcinoma and is correlated with an increased tumor grade. If urachal pathology appears with signs of infection, a two-stage treatment is recommended<sup>11</sup>. Initially administration of antibiotics and resolution of inflammation followed by surgical removal. In benign urachal anomalies complete excision with or without the cuff of the bladder is sufficient. It is not necessary to remove the umbilicus<sup>12</sup>.

### Conclusions

Urachal anomalies may present in various forms. Often its presentation is nonspecific and as such may cause many diagnostic problems. The patient's history and physical examination are crucial for the correct diagnosis. Although now-a-days many methods are available for diagnosing pathology of urachal remnants, but CT scan can diagnose urachal pathology almost accurately.

### References

- Galati V, Donovan B, Ramji F, Campbell J, Kropp BP, Frimberger D. Management of urachal remnants in early childhood. *J Urol*. 2008; suppl 4: 1824–1826.
- Henly DR, Farrow GM, Zincke H. Urachal cancer: role of conservative surgery. *Urology*. 1993; 42: 635–639.
- Ashley RA, Inman BA, Routh JC, Rohlinger AL, Husmann DA, Kramer SA. Urachal anomalies: a longitudinal study of urachal remnants in children and adults. *J Urol*. 2007; 178: 1615–1618.
- Copp HL, Wong IY, Krishnan C, Malhotra S, Kennedy WA. Clinical presentation and urachal remnant pathology: implications for treatment. *J Urol* 2009; 182:1921-1924.
- Tian J, Ma JH, Li CL, Xiao ZD. Urachal mass in adults: clinical analysis of 33 cases. *Zhonghua Yi Xue Za Zhi*. 2008; 88: 820–822.
- Patrzyk M, Glitsch A, Schreiber A, von Berstorff W, Heidecke CD. Single-incision laparoscopic surgery as an option for the laparoscopic resection of an urachal fistula: first description of the surgical technique. *Surg Endosc* 2010; 24:2339-2342.
- Qureshi K, Maskell D, McMillan C, Wijewardena C. An infected urachal cyst presenting as an acute abdomen – A case report. *Int J Surg Case Rep*. 2013; 4: 633–635.
- Nimmonrat A, Na-Chiang Mai W, Muttarak M. Urachal abnormalities: clinical and imaging features. *Singapore Med J*. 2008; 49: 930–935.
- Thali-Schwab CM, Woodward PJ, Wagner BJ. Computed tomographic appearance of urachal adenocarcinomas: review of 25 cases. *Eur Radiol*. 2005; 15: 79–84.
- Ashley RA, Inman BA, Sebo TJ, Leibovich BC, Blute ML, Kwon ED, Zincke H. Urachal carcinoma: clinicopathologic features and long-term outcomes of an aggressive malignancy. *Cancer*. 2006; 107: 712–720.
- Yoo KH, Lee SJ, Chang SG. Treatment of infected urachal cysts. *Yonsei Med J*. 2006; 47: 423–427.
- Colombo Jr JR, Desai M, Canes D, Frota R, Haber GP, Moinzadeh A, et al. Laparoscopic partial cystectomy for urachal and bladder cancer. *Clinics (Sao Paulo)*. 2008; 63: 731–734.