

# ANTENATAL HYDRONEPHROSIS

MAHMOOD HASAN<sup>1</sup>, FAZAL NASER<sup>2</sup>, SHAFIQL AZAM<sup>2</sup>, ABUL HOSSAIN<sup>2</sup>, SHOHRAB HOSSAIN<sup>3</sup>*Bangladesh J. Urol. 2019; 22(2): 194-203*

## Introduction

Detection of antenatal hydronephrosis (ANH) now a day has been increased significantly with the use of prenatal ultrasound. Garrett et al in 1970 first reported about genitourinary abnormalities during prenatal ultrasonography (USG) [1]. Currently it comprises about 20% of all antenatally detected fetal anomalies [2]. One of the most commonly detected anomalies is hydronephrosis and found in approximately 1% to 5% of all pregnancies [3]. According to the report of Bangladesh Sample Vital Statistics, the Crude Birth Rate was 18.3 per 1000 live birth in 2018 [4]. It means that, there are probable burden of approximately 30,000 - 150,000 new cases of ANH in our health care system. Although there is a wide spectrum of etiologies of ANH (Table 1), 12%-88% of these children will have significant pathology that needs a thorough postnatal evaluation of the upper and lower tracts postnatally [5]. The rationale of prenatal detection and postnatal evaluation is to early identification of pathology prior to the development of complications such as urinary tract infection (UTI), urinary stone formation and renal dysfunction. On the other hand, 88%-12% of the children with ANH will have no demonstrable pathology postnatally as various studies shows that most common cause of antenatally detected hydronephrosis is transient or non obstructive dilatation of the pelvicalyceal system [6,7]. Not evaluating any child with ANH could avoid an initial costs but might delay the diagnosis of significant uropathies such as PUV and consequently, incur higher long-term health and financial costs. Thus it creates a dilemma and challenge of predicting which children will have a clinically significant uropathy and would benefit from postnatal imaging. This article reviews the primary literatures and consensus

statements pertaining to ANH and management of infants with this finding.

**Table-I**  
*Etiology of ANH*

Etiology	Incidence
1. Transient hydronephrosis	41-88%
2. UPJ obstruction	10-30%
3. VUR	10-20%
4. UVJ obstruction / Megaureter	05-10%
5. Multicystic dysplastic kidney	04-06%
6. PUV / Urethral atresia	01-02%
7. Ureterocele / Duplex system / Ectopic ureter	05-07%
8. Others / Cystic kidney disease, congenital ureteric stricture, megalourethra	Uncommon

Adopted from Nguyen et al., 2010 [3]

## Defining and grading ANH

The parameters used to define ANH and determine what will be clinically significant are controversial. Continuous efforts have been made to develop a more objective classification system of hydronephrosis, but it still remains somewhat subjective. The grading system currently used are descriptive (mild-moderate-severe), the quantitative (antero-posterior renal pelvis diameter, APD), or the semi quantitative (Society for Fetal Urology (SFU) grading system) [5].

### 1. Descriptive classification:

In the most basic and traditional grading system, the grade of hydronephrosis is characterized as mild, moderate, or severe. The utility of this system has been improved by the use of the terms pelviectasis (dilation of the renal pelvis), pelvicaliectasis (dilation of the renal pelvis and calyces), and caliectasis (dilation of the calyces) to describe the extent of the hydronephrosis.

1. Assistant Professor, Department of Urology, Shaheed Suhrawardy Medical College & Hospital, Dhaka
2. Associate Professor, Department of Urology, Shaheed Suhrawardy Medical College & Hospital, Dhaka
3. Professor, Department of Urology, Dhaka Central International Medical College & Hospital, Dhaka

**Correspondences:** Mahmood Hasan, Assistant Professor, Department of Urology, Shaheed Suhrawardy Medical College & Hospital, Dhaka

The highly subjective nature of this system that causes poor inter-rater reliability is the major drawback of this system.

## 2. APD classification:

One common method of diagnosing ANH is by measuring the anterior–posterior diameter (APD) of the renal pelvis using USG (Table 2). It is a more objective measurement of the degree of hydronephrosis. Several authors have assessed the threshold of APD for diagnosing ANH associated with abnormalities of the urinary tract. The currently accepted standard for APD considered to be of clinical significance is based on the original work by Corteville et al. [8] and further evaluated by other studies [9–11]. In the Corteville series, an APD of >4 mm at 33 weeks gestational age (GA) or of >7 mm at 40 weeks GA demonstrated a sensitivity of 100% for the identification of those patients with abnormal renal function or those who required subsequent intervention postnatally, suggesting an upper limit threshold of ANH that requires postnatal evaluation. Although there is much debate about these threshold levels, there is near uniform agreement that an APD greater than 15 mm represents severe or significant hydronephrosis, and most would agree that a value of 4–5 mm is an appropriate threshold for

considering the APD to be abnormal [12, 13, 14, 15]. Taking this into account, ANH can be classified in the 2nd and 3rd trimester using APD thresholds given in the Table 2 which has the best available evidence. Limitations of APD as a tool of ANH are as follows, (1) it is single measurement of collecting system, (2) there would be the inter- and intra-observer reliability, and (3) APD does not consider calyceal dilation or renal parenchymal thinning that may indicate more severe obstruction [16].


















**Table-II**  
Definition of ANH by APD

Degree of ANH	Second trimester	Third trimester
Mild	4 to <7 mm	7 to <9 mm
Moderate	7 to 10 mm	9 to 15 mm
Severe	>10 mm	>15 mm

Adopted from Nguyen et al., 2010 [3]

## 3. SFU classification:

Society of Fetal Urology classification of ANH was first described in 1993 [17] describing the renal pelvis dilatation along with the dilatation of the calyces and hence its effect on the parenchyma (Fig 1).

SFU Grading of Infant Hydronephrosis					
	Pattern of renal sinus splitting	IVP Appearance	Ultrasound Variants		
SFU Grade 0	No splitting				
SFU Grade 1	Urine in pelvis barely splits sinus				
SFU Grade 2	Urine fills in renal pelvis				
SFU Grade 2	Urine fills extra renal pelvis major calyces Dilated				
SFU Grade 3	SFU Gr 2 and minor calyces uniformly dilated and parenchyma preserved				
SFU Grade 4	SFU Gr 3 and parenchyma thin				

**Fig.-1:** The Society for Fetal Urology Hydronephrosis Grading System ([http://www.uab.edu/images/peduro/SFU/sfu\\_grading\\_on\\_web/sfu\\_grading\\_on\\_web.htm](http://www.uab.edu/images/peduro/SFU/sfu_grading_on_web/sfu_grading_on_web.htm)).

It has been observed that the SFU grade of hydronephrosis correlates with the potential for postnatal resolution of the hydronephrosis. SFU grade 1 hydronephrosis resolves in approximately 50% of patients, whereas grades 2, 3, and 4 hydronephrosis resolve in 36, 16, and 3% of cases, respectively [18]. However this grading system is not universally followed and due to the discrepancy in inter and intra observer agreement especially in grade 3 and grade 4 hydronephrosis. The Japanese Society of Pediatric Urology has also proposed a (minor) modification of the SFU grading system in an effort to improve inter-rater reliability [19]. Even this modification have not gained universal acceptance.

### **Additional USG finding**

In addition to characterizing the grade of the hydronephrosis, the antenatal USG usually document amniotic fluid level, urinary bladder, visualization of a ureter, presence of bilateral kidneys, characterization of renal cysts if any, and the presence of other organ system abnormalities [20]. These additional findings often contribute to establishing the postnatal diagnosis and correlations with outcomes.

### **The natural history of ANH**

On literature search scarcity of prospective studies [21-25] and meta-analyses were found to display the natural history of ANH. The following facts could be retrieved.

Most of the cases of hydronephrosis diagnosed at second trimester have been found to resolve during follow-up imaging in the third trimester. Additionally, the cases where hydronephrosis resolved or improved from the second to third trimester usually did not developed clinically significant postnatal pathology. On the other hand, cases in which the hydronephrosis was stable/persistent or worsened during pregnancy showed a variable outcome.

The timing of diagnosis of ANH can be used as a predictor of its outcome. Children diagnosed in the first trimester with hydronephrosis were found to have a poor outcome. In comparison, those diagnosed during the second trimester experienced an overall favorable prognosis. The hydronephrosis resolved or improved in the majority (approximately 80%), and few ultimately required surgical intervention (<5%). But, those diagnosed in the 3rd trimester appeared to have higher rates of postnatally confirmed pathology that may require operative intervention.

Regarding resolution of hydronephrosis it was found that about 20-40% of ANH persisted postnatally, and

ultimately resolved spontaneously at approximately same frequency. The timing of resolution is quite variable. The milder grades of hydronephrosis were found to have resolution earlier, with the majority of SFU grade 1-2 hydronephrosis resolving by 18 months of age [26]. Operative repair, mostly due to UPJ obstruction, required in approximately 25% of cases, with a range from 5% to 50% depending on the study [27-29]. Not as always the trend, multiple studies have also shown that some milder degrees of hydronephrosis required surgical intervention [30].

### **Antenatal monitoring and fetal intervention**

Currently, there is no agreed upon protocol for the antenatal evaluation and its follow up. The first anomaly scan is done usually between 18-20 wk, this should reliably diagnose antenatal hydronephrosis. The subsequent frequency of follow up ultrasound is often based on the severity of findings and the pathology suspected. There is usually no added advantage of doing very frequent ultrasound examinations for it adds very little to the diagnosis and subsequent management and only aggravates parental anxiety. Sairam et al., found that, although 88% cases with mild ANH resolved in neonatal period, one in three neonates with moderate to severe hydronephrosis persisted even in the third trimester and ultimately a good proportion of them required postnatal surgery [31]. So, once the diagnosis is made then the next ultrasonography should be done in the third trimester between 28-32 wk. However more frequent ultrasounds, usually in every 4-6 wk, will be needed in cases having bilateral hydronephrosis, posterior urethral valves, and severe hydronephrosis in a solitary kidney. Ultrasound findings in these clinical scenarios have an important bearing on the decision making in deciding the obstetric course of the patient.

Studies have shown that urinary obstruction can cause renal dysplasia and relief of that obstruction can prevent dysplasia if performed early enough [32]. The goal of fetal intervention would be to relieve this obstruction and allow for normal renal development. This in turn would maintain the amniotic fluid levels to allow for normal lung development. Fetal intervention is usually done for those with documented lower tract obstruction, the commonest cause being posterior urethral valves, where intervention would significantly benefit the overall fetal prognosis. Vesico-amniotic shunt, renal pelvis aspiration, vesicocentesis, fetoscopic fulguration of posterior urethral valves etc have been tried. These interventions carry considerable

risk of fetal loss, chorioamnionitis, and preterm labor. It is also unfortunate enough that, an intervention can only be done later during gestation, which is frequently too late to prevent renal dysplasia. So, does it alter the prognosis significantly and does the benefit outweigh the risks should be evaluated diligently. Currently, fetal intervention is recommended in cases of a second trimester fetus with significant oligohydramnios, suspected good renal function, and the absence of other life-threatening congenital abnormalities only in a specialized center [33]. But termination of pregnancy is not recommended in fetuses with unilateral or bilateral ANH, except in presence of extra renal life threatening abnormality.

### Postnatal evaluation

There is a general consensus regarding postnatal USG evaluation of all antenatally detected hydronephrosis. Common classifications for diagnosis and grading of postnatal hydronephrosis are based on measurement of renal pelvic APD and that proposed by the SFU. But there is significant controversy as to which infants with ANH and when they require radiological evaluation.

Since infants are relatively dehydrated at birth, the initial postnatal ultrasonography should be performed after 48 h of birth as by this time adequate hydration usually established after delivery [34]. The exceptions to this practice: (1) Suspected lower tract obstruction e.g., Posterior urethral valves; (2) Severe bilateral hydronephrosis with or without hydroureter; and (3) Solitary kidney with hydronephrosis especially if the APD is > 15 mm or it is SFU grade 2 or more in the third trimester. Early sonography in these situations has obvious bearing on further management [35].

A normal ultrasound finding in the first week of life might not be adequate because by this time period all abnormalities of the kidneys or urinary tract might not be detectable. This may be due to low urine flow secondary to dehydration and low glomerular filtration rate (GFR). An ultrasound at 6 week is more sensitive and specific for obstruction, than that in the first week of life [36]. All newborns with ANH and a normal ultrasound at first week postnatally, therefore, should undergo a repeat study at 4-6 week [3]. The presence of two normal postnatal renal ultrasounds reasonably excludes presence of significant renal disease including VUR [37].

The frequency of subsequent monitoring in patients with persistent postnatal hydronephrosis depends on its severity, and includes evaluation for increasing pelvicalyceal or ureteric dilatation and cortical thinning. Since progression might occur in the first 2-years of life, and occasionally until 5-6 years [38].

Follow-up studies should be scheduled at 3-6 months, and then 6-12 monthly until resolution [39].

Micturating cystourethrogram (MCU) is a widely used tool for postnatal evaluation of ANH. The recommendation regarding a (MCU) is to be performed in patients with unilateral or bilateral hydronephrosis with renal pelvic APD > 10 mm, SFU grade 3-4 or ureteric dilatation at 4-6 weeks of age. If the ANH is reasonably seemed to be due to lower urinary tract obstruction (most commonly posterior urethral valves), as evidenced by USG findings of bladder change, an early MCU (within 1-3 days of life) should be performed [40]. Since these patients are at risk for progressive kidney disease and recurrent UTI. Physicians should be aware that this investigation itself is associated with risks of UTI [41] and exposure to radiation [41].

A diuretic renogram is performed as a functional study in the management pathway of ANH. It should be performed in the infants with moderate to severe unilateral or bilateral hydronephrosis (SFU grade 3-4, APD > 10 mm) with or without dilated ureter who do not show VUR. It is recommended to perform the test at 6-8 weeks of age since the newborn kidneys are immature and may be unable to respond adequately to the diuretic. It may be repeated after 3-6 months in infants where ultrasound shows progressive worsening of pelvicalyceal dilatation. The preferred radiopharmaceuticals are Tc-mercaptoacetyl triglycine (Tc-MAG3), or Tc-diethylene triamine pentaacetic acid (DTPA) [42, 43].

### Postnatal intervention

Infants with lower urinary tract obstruction, most commonly with posterior urethral valves require early urethral catheterization, correction of electrolyte abnormalities, and cystoscopic ablation of the urethral valves as early as possible is recommended [44, 45].

Regarding upper urinary tract obstruction, most commonly due to PUJO, most experts suggest that pyeloplasty be considered in patients showing obstructed renogram with prolonged t > 20 min. and differential function below 35-40% [46, 47]. Conservative management is appropriate for infants with an obstructive pattern on diuretic renography and differential function exceeding 40% [48]. Serial ultrasonography is recommended [3, 49] and repeat Renography should be done if there is persistent or progressive hydronephrosis or parenchymal thinning [50, 51]. A reduction of differential renal function by more than 5-10% correlates with declining renal function, and the need for pyeloplasty [52]. Other indications for surgery include presence of pain, palpable renal lump or recurrent febrile UTI [53]. Surgery allows preservation of renal function

in the majority; predictors of unsatisfactory outcome include baseline differential function <30% [54] and renal APD >50mm with dilated calyces [55].

**Antibiotic prophylaxis**

In a meta-analysis including 3876 infants, it was demonstrated that neonates with high grade hydronephrosis receiving antibiotic prophylaxis have a significantly lower rate of UTI when compared to untreated neonates (14.6% versus 28.9%; *P* <0.01), while the rates of UTI were low for neonates with low grade hydronephrosis, regardless of status of antibiotic prophylaxis (2.2% on prophylaxis versus 2.8% without) [56]. So, prophylactic antibiotic is not recommended for patients with mild degree of hydronephrosis because of the low risk of developing a urinary tract infection or need for subsequent surgery. But, chemoprophylaxis is indicated in those with moderate or severe degree of hydronephrosis and VUR. Antibiotics that are preferred include cephalexin (10 mg/kg/d) during the first 3 months of life, and cotrimoxazole (1-2mg/kg/d) or nitrofurantoin (1 mg/kg/d) later on [57].

**Risk of radiation exposure**

Radiocontrast and radionuclide studies are associated with considerable risk of radiation exposure. The exposure following these studies is several-fold higher than a chest radiograph. An IVU, MCU, CT-Abdomen and DTPA renogram cause exposure to radiation equivalent to about 150, 120, 400 and 60 chest X-rays respectively [58-61]. A large cohort of patients undergoing repeated CT scans were associated with 3-fold increased risk of leukemia and brain cancer [62]. So, physicians should be aware of the risks associated with investigations that cause considerable amount of radiation exposure. Repeat radionuclide and radiocontrast studies should be done only if these are

likely to provide clinically relevant information that cannot be obtained by USG. Intravenous urography should not be used as an alternative to radionuclide scans.

Recent risk based approach to ANH (The UTD classification system)

Eight societies with a special interest in the diagnosis and management of fetuses and children with urinary tract dilation (UTD), (The American College of Radiology (ACR), the American Institute of Ultrasound in Medicine (AIUM), the American Society of Pediatric Nephrology (ASPN), the Society for Fetal Urology (SFU), the Society for Maternal-Fetal Medicine (SMFM), the Society for Pediatric Urology (SPU), the Society for Pediatric Radiology (SPR), and the Society of Radiologists in Ultrasound (SRU)) agreed to collaborate on the development of a unified grading system for perinatal UTD and propose a standardize scheme for follow up evaluation. The consensus conference took place on March, 2014. The principal goals for the Consensus Panel were: 1. to propose a unified description of UT dilation that can be applied both prenatally and postnatally with consistent terminology, 2. to propose a standardized scheme for the perinatal evaluation of these patients based on sonographic criteria.

**Consensus Panel recommendation:**

Because of the apparent confusion associated with the implied meanings of various terminologies for UT dilation, the Consensus Panel recommended avoiding the use of nonspecific terms in describing UT dilation (e.g. hydronephrosis, pyelectasis, pelviectasis, uronephrosis, UT fullness or prominence, and pelvic fullness). The panel recommends the consistent use of the term “UT dilation” (UTD).

The panel concluded that the following sonographic features are important factors in characterizing the severity of the UTD (Table 3).

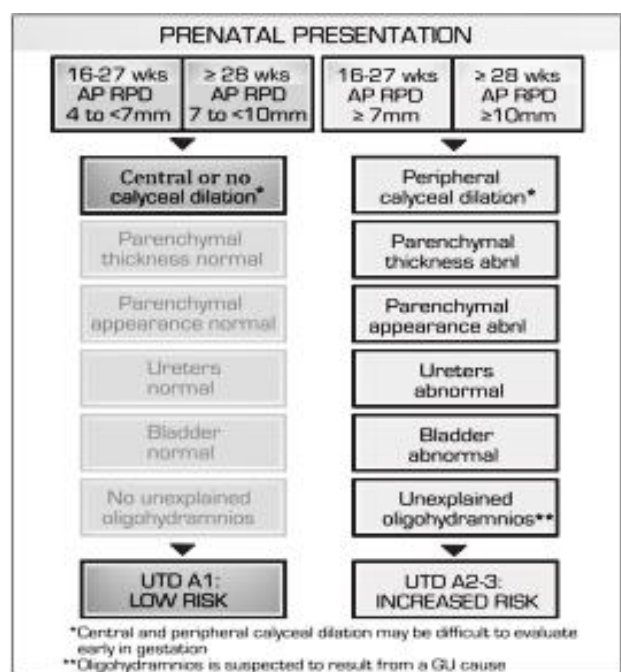
**Table-III**  
*US parameters included in the Urinary Tract Dilation Classification System.*

US parameters	Measurement/ findings	Notes
APRPD	(mm)	Measured on transverse image at the maximal diameter of intrarenal pelvis
Calyceal dilation	Central (major calyces) Peripheral (minor calyces)	Yes/No Yes/No
Parenchymal thickness		Normal/Abnormal
Parenchymal appearance		Normal/Abnormal
Ureter		Normal/Abnormal
Bladder		Normal/Abnormal
		Subjective assessment
		Evaluate echogenicity, corticomedullary differentiation
		Dilation of ureter is considered abnormal
		Evaluate wall thickness, for the presence of ureterocele, and for a dilated posterior urethra

APRPD = Anterior-Posterior Renal Pelvic Diameter Adopted from Nguyen et al., 2014 [63]

Regarding reporting system of UT dilation, the panel recommends that a description of the above seven imaging parameters (Table 3, Figs. 2 and 3) should be reported in the written report. In the Impression section, the specific UTD category (Normal, UTDA1, UTD A2e3, UTD P1, UTD P2, or UTD P3) should be reported along with the suggested management scheme. Ideally, representative images should be provided with thereport.

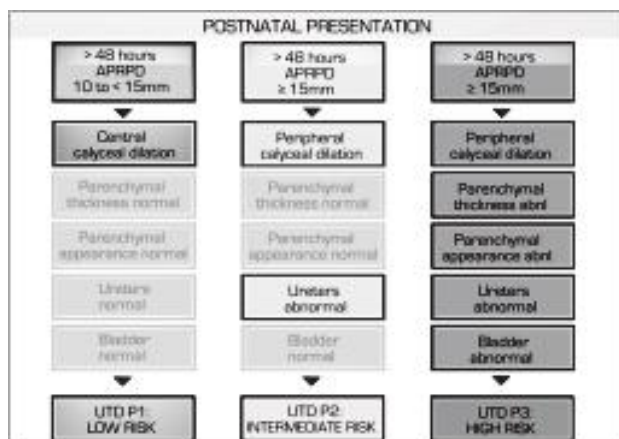
When the UT dilation is detected prenatally (denoted as A for antenatally), the panel suggest stratifying the findings into alow risk group (UTDA1) and an increased risk group (UTD A2-3). Criteria for UTD A1 and A2-3 have been shown in figure 2. The panel noted that, based on the literature and clinical experience, it was often difficult to distinguish between central (UTD A2) and peripheral calyceal dilation (UTD A3) on prenatal US. Consequently, the panel recommends combining the intermediate and high-risk groups to create one category of increased risk (UTD A2-3).



**Fig.-2:** Urinary Tract Dilation (UTD) risk stratification: Prenatal Presentation for UTD A1 (low risk) and UTD A2–3 (increased risk), (Adopted from Nguyen et al., 2014 [63]).

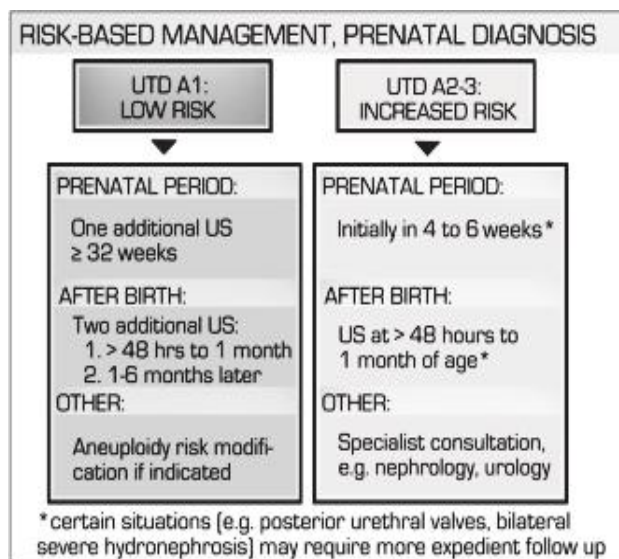
When UT dilation is detected postnatally (denoted as P), the panel recommend stratification of risk into three groups: lowrisk (UTD P1); intermediate risk (UTD P2);

and high-risk (UTD P3) groups. Criteria have been delineated in Figure 3.




**Fig.-3:** Urinary Tract Dilation (UTD) risk stratification: Postnatal presentation for UTD P1 (low risk), UTD P2 (intermediate risk), and UTD P3 (high risk). (Adopted from Nguyen et al., 2014 [63]).

The panel emphasized about the timing of the first postnatal USG to be done more than 48 h after birth to ensure it does not underestimate dilation, and be repeated once to ensure the appropriate management. Based on the suggested UTD classification system's risk stratification, the panel also proposed a follow-up management scheme (Figs 4 and 5).



**Fig.-4** Management schema based on UTD classification system's risk stratification of UTDA1 and UTD A2–3. (Adopted from Nguyen et al., 2014 [63])



**Fig.-5:** Management schema based on Urinary Tract Dilation (UTD) classification system risk stratification of UTD P1, UTD P2, and UTD P3. (Adopted from Nguyen et al., 2014 [63])

### Conclusion

ANH is a common condition with a wide variety of aetiologies and clinical outcomes. The most common type of ANH is transient mild dilation that requires routine outpatient ultrasound evaluation. It is very important to identify the group of patients who require extended prenatal and postnatal evaluation, as these patients are at higher risk for poor outcomes and often need specialized care. Ultrasound has remained a routine part of evaluation and follow-up. VCUG and diuretic renography should be used more selectively to avoid overuse. The newly adopted risk based UTD classification system may help the urologists to take appropriate and effective decision in different scenario of ANH.

### References

- Garrett WJ, Grunwald G, Robinson DE. Prenatal diagnosis of fetal polycystic kidney by ultrasound. *Aust N Z J Obstet Gynaecol.* 1970; 10: 7-9.
- Elder JS. Antenatal hydronephrosis. Fetal and neonatal management. *Pediatr Clin North Am.* 1997; 44: 1299-1321.
- Nguyen HT, Herndon CD, Cooper C, Gatti J, Kirsch A, Kokorowski P, Lee R, et al. The Society for Fetal Urology consensus statement on the evaluation and management of antenatal hydronephrosis. *J Pediatr Urol.* 2010; 6: 212-231.
- Report on Bangladesh Sample Vital Statistics 2018. Bangladesh Bureau of Statistics. May 2019. [online]
- Lee RS, Cendron M, Kinnamon DD, Nguyen HT. Antenatal hydronephrosis as a predictor of postnatal outcome: a metaanalysis. *Pediatrics* 2006; 118: 586-593.
- Asserotti CC, Kalish LA, Chow J, Passerotti AM, Recabal P, Cendron M, et al. The predictive value of the first postnatal ultrasound in children with antenatal hydronephrosis. *J Pediatr Urol.* 2011; 7: 128-136.
- Damen-Elias HA, Luijnenburg SE, Visser GH, Stoutenbeek PH, de Jong TP. Mild pyelectasis diagnosed by prenatal ultrasound is not a predictor of urinary tract morbidity in childhood. *Prenat Diagn.* 2005; 25: 1239-1247.
- Corteville JE, Gray DL, Crane JP. Congenital hydronephrosis: correlation of fetal ultrasonographic findings with infant outcome. *Am J Obstet Gynecol* 1991; 165:384-388.
- Wollenberg A, Neuhaus TJ, Willi UV, Wisser J. Outcome of fetal renal pelvic dilatation diagnosed during the third trimester. *Ultrasound Obstet Gynecol.* 2005; 25:483-488.
- Coelho GM, Bouzada MC, Lemos GS, Pereira AK, Lima BP, Oliveira EA. Risk factors for urinary tract infection in children with prenatal renal pelvic dilatation. *J Urol.* 2008; 179:284-289.
- Coelho GM, Bouzada MC, Pereira AK, Figueiredo BF, Leite MR, Oliveira DS, Oliveira EA. Outcome of isolated antenatal hydronephrosis: a prospective cohort study. *Pediatr Nephrol.* 2007; 22:1727-1734.
- Coplen DE, Austin PF, Yan Y, Blanco VM, Dicke JM. The magnitude of fetal renal pelvic dilatation can identify obstructive postnatal hydronephrosis, and direct postnatal evaluation and management. *J Urol.* 2006; 176:724.
- Ismaili K, Hall M, Donner C, Thomas D, Vermeylen D, Avni FE. Results of systematic screening for minor degrees of fetal renal pelvis dilatation in an unselected population. *Am J Obstet Gynecol.* 2003; 188:242.
- Ahmad G, Green P. Outcome of fetal pyelectasis diagnosed antenatally. *J Obstet Gynaecol.* 2005; 25: 119.

15. Coelho GM, Bouzada MC, Pereira AK, Figueiredo BF, Leite MR, Oliveira DS, et al. Outcome of isolated antenatal hydronephrosis: a prospective cohort study. *Pediatr Nephrol.* 2007; 22:1727.
16. Nguyen HT, Herndon CD, Cooper C, Gatti J, Kirsch A, Kokorowski P, et al. Society for Fetal Urology consensus statement on the evaluation and management of antenatal hydronephrosis. *J Pediatr Urol.* 2010; 6:212-31.
17. Fernbach SK, Maizels M, Conway JJ. Ultrasound grading of hydronephrosis: Introduction to the system used by the Society for Fetal Urology. *Pediatr Radiol.* 1993; 23: 478-480.
18. Lim DJ, Park JY, Kim JH, Paick SH, Oh SJ, Choi H. Clinical characteristics and outcome of hydronephrosis detected by prenatal ultrasonography. *J Korean Med Sci.* 2003; 18:859–862.
19. Shimada K, Kakizaki H, Kubota M, Taki M, Takeuchi H, Hiramatsu Y, et al. Standard method for diagnosing dilatation of the renal pelvis and ureter discovered in the fetus, neonate or infant. *Int J Urol.* 2004; 11:129.
20. Kleiton G. R. Yamaçake & Hiep T. Nguyen. Current management of antenatal hydronephrosis. *Pediatr Nephrol.* 2013; 28:237–243.
21. Wollenberg A, Neuhaus TJ, Willi UV, Wisser J. Outcome of fetal renal pelvic dilatation diagnosed during the third trimester. *Ultrasound Obstet Gynecol.* 2005; 25:483.
22. Coelho GM, Bouzada MC, Pereira AK, Figueiredo BF, Leite MR, Oliveira DS, et al. Outcome of isolated antenatal hydronephrosis: A prospective cohort study. *Pediatr Nephrol.* 2007; 22:1727.
23. Bouzada MCF, Oliveira EA, Pereira AK, Leite HV, Rodrigues AM, Fagundes LA, et al. Diagnostic accuracy of fetal renal pelvis anteroposterior diameter as a predictor of uropathy: A prospective study. *Ultrasound Obstet Gynecol* 2004; 24:745.
24. Jaswon MS, Dibble L, Puri S, Davis J, Young J, Dave R, et al. Prospective study of outcome in antenatally diagnosed renal pelvis dilatation. *Arch Dis Child. Fetal Neonatal Ed.* 1999; 80: F135.
25. Upadhyay J, McLorie GA, Bolduc S, Ba'gali DJ, Khoury AE, Farhat W. Natural history of neonatal reflux associated with prenatal hydronephrosis: long-term results of a prospective study. *J Urol.* 2003; 1837: 169.
26. Mallik M, Watson AR. Antenatally detected urinary tract abnormalities: More detection but less action. *Pediatr Nephrol.* 2008; 23:897.
27. Herndon CDA. Antenatal hydronephrosis: differential diagnosis, evaluation, and treatment options. *ScientificWorld Journal.* 2006; 1:50.
28. Ransley PG, Dhillon HK, Gordon I, Duffy PG, Dillon MJ, Barratt TM. The postnatal management of hydronephrosis diagnosed by prenatal ultrasound. *J Urol.* 1990;144:584.
29. Thornburg LL, Pressman EK, Chelamkuri S, Hulbert W, Rabinowitz R, Mevorach R. Third trimester ultrasound of fetal pyelectasis: Predictor for postnatal surgery. *J Pediatr Urol.* 2008; 4:51.
30. Noe HN, Magill HL. Progression of mild ureteropelvic junction obstruction in infancy. *Urology.* 1987; 30:348.
31. Sairam S, Al-Habib A, Sasson S, Thilaganathan B. Natural history of fetal hydronephrosis diagnosed on mid-trimester ultrasound. *Ultrasound Obstet Gynecol.* 2001;17:191–6.
32. Holmes N, Harrison MR, Baskin LS. Fetal surgery for posterior urethral valves: Long-term postnatal outcomes. *Pediatrics.* 2001;108: E7.
33. Herndon CD, Ferrer FA, Freedman A, McKenna PH. Consensus on the prenatal management of antenatally detected urological abnormalities. *J Urol.* 2000;164:1052–1056.
34. Dejter SW, Gibbons MD. The fate of infant kidneys with fetal hydronephrosis but initially normal postnatal sonography. *J Urol.* 1989; 142: 661-662; discussion 667-668.
35. Herndon CD. Antenatal hydronephrosis: differential diagnosis, evaluation, and treatment options. *ScientificWorld-Journal.* 2006; 6: 2345-2365.
36. Clautice-Engle T, Anderson NG, Allan RB, Abbott GD. Diagnosis of obstructive hydronephrosis in infants: Comparison sonograms performed 6 days and 6 weeks after birth. *AJR Am J Roentgenol.* 1995;164:963–7.
37. Lidelfelt KJ, Herthelius M. Antenatal hydronephrosis: Infants with minor postnatal



- dilatation do not need prophylaxis. *Pediatr Nephrol.* 2008; 23:2021–4.
38. Gatti JM, Broecker BH, Scherz HC, Perez-Brayfield MR, Kirsch AJ. Antenatal hydronephrosis with postnatal resolution: How long are postnatal studies warranted? *Urology.* 2001; 57:1178.
  39. Hafez AT, McLorie G, Bagli D, Khoury A. Analysis of trends on serial ultrasound for high grade neonatal hydronephrosis. *J Urol.* 2002; 168: 1518–21.
  40. Finnell SM, Carroll AE, Downs SM. Subcommittee on Urinary Tract Infection. Technical report-Diagnosis and management of an initial UTI in febrile infants and young children. *Pediatrics.* 2011; 128:749–70.
  41. Ismaili K, Avni FE, Hall M. Brussels Free University Perinatal Nephrology (BFUPN) Study Group. Results of systematic voiding cystourethrography in infants with antenatally diagnosed renal pelvis dilation. *J Pediatr.* 2002; 141: 21–4.
  42. Gordon I, Piepsz A, Sixt R. Auspices of Paediatric Committee of European Association of Nuclear Medicine. Guidelines for standard and diuretic renogram in children. *Eur J Nucl Med Mol Imaging.* 2011; 38:1175–88.
  43. Conway JJ, Maizels M. The well tempered diuretic renogram: A standard method to examine the asymptomatic neonate with hydronephrosis or hydroureteronephrosis. A report from combined meetings of The Society for Fetal Urology and members of The Pediatric Nuclear Medicine Council-The Society of Nuclear Medicine. *J Nucl Med.* 1992; 33:2047–51.
  44. Yohannes P, Hanna M. Current trends in the management of posterior urethral valves in the pediatric population. *Urology.* 2002; 60:947–53.
  45. Sarhan O, Zaccaria I, Macher MA, Muller F, Vuillard E, Delezoide AL, et al. Long-term outcome of prenatally detected posterior urethral valves: Single center study of 65 cases managed by primary valve ablation. *J Urol.* 2008; 179: 307–12.
  46. Madden NP, Thomas DF, Gordon AC, Arthur RJ, Irving HC, Smith SE. Antenatally detected pelviureteric junction obstruction. Is non-operation safe? *Br J Urol.* 1991; 68:305–10.
  47. Thomas DF. Prenatal diagnosis: What do we know of long-term outcomes? *J Pediatr Urol.* 2010; 6:204–11.
  48. Chertin B, Pollack A, Koulikov D, Rabinowitz R, Hain D, Hadas-Halpren I, et al. Conservative treatment of ureteropelvic junction obstruction in children with antenatal diagnosis of hydronephrosis: Lessons learned after 16 years of follow-up. *Eur Urol.* 2006; 49:734–8.
  49. Ransley PG, Dhillon HK, Gordon I, Duffy PG, Dillon MJ, Barratt TM. The postnatal management of hydronephrosis diagnosed by prenatal ultrasound. *J Urol.* 1990; 144: 584–7.
  50. Heinlen JE, Kropp BP, Frimberger DC. Progression of hydronephrosis correlates with worsening renal function in children. Conference: 2009 American Urological Association (AUA) Annual Meeting Chicago, IL United States. Conference Publication. *J Urol.* 2009; 181: 443.
  51. Chertin B, Rolle U, Farkas A, Puri P. Does delaying pyeloplasty affect renal function in children with a prenatal diagnosis of pelvi-ureteric junction obstruction? *BJU Int.* 2002; 90:72–5.
  52. Josephson S. Antenatally detected, unilateral dilatation of the renal pelvis: A critical review. 1. Postnatal non-operative treatment 20 years on—Is it safe Scand? *J Urol Nephrol.* 2002; 36: 243–50.
  53. Finnell SM, Carroll AE, Downs SM. Subcommittee on Urinary Tract Infection. Technical report-Diagnosis and management of an initial UTI in febrile infants and young children. *Pediatrics.* 2011; 128:749–70.
  54. Dhillon HK. Prenatally diagnosed hydronephrosis: The Great Ormond Street experience. *Br J Urol.* 1998; 81:39–44.
  55. Koff SA, Campbell KD. The nonoperative management of unilateral neonatal hydronephrosis: Natural history of poorly functioning kidneys. *J Urol.* 1994; 152: 593–5.
  56. Braga LH, Mijovic H, Farrokhyar F, Pemberton J, DeMaria J, Lorenzo AJ. Antibiotic prophylaxis for urinary tract infections in antenatal hydronephrosis. *Pediatrics.* 2013; 131: 251–61.
  57. Indian Society of Pediatric Nephrology. Vijayakumar M, Kanitkar M, Nammalwar BR,

- Bagga A. Revised statement on management of urinary tract infections. *Indian Pediatr.* 2011; 48:709–17.
58. Roth CC, Hubanks JM, Bright BC, Heinlen JE, Donovan BO, Kropp BP, et al. Occurrence of urinary tract infection in children with significant upper urinary tract obstruction. *Urology.* 2009;73:74–8.
59. Brenner DJ, Hall EJ. Computed tomography: An increasing source of radiation exposure. *N Engl J Med.* 2007; 357:2277–84.
60. Mettler FA, Jr, Huda W, Yoshizumi TT, Mahesh M. Effective doses in radiology and diagnostic nuclear medicine: A catalog. *Radiology.* 2008; 248: 254–63.
61. Smith T, Gordon I. An update of radio-pharmaceutical schedules in children. *Nucl Med Commun.* 1998;19:1023–36.
62. Pearce MS, Salotti JA, Little MP, McHugh K, Lee C, Kim KP, et al. Radiation exposure from CT scans in childhood and subsequent risk of leukaemia and brain tumours: A retrospective cohort study. *Lancet.* 2012; 380:499–505.
63. Nguyen HP et al. Multidisciplinary consensus on the classification of prenatal and postnatal urinary tract dilation (UTD classification system). *J Pediatr Urol.* 2014;10:982-99.