



Mini Percutaneous Nephrolithotomy in Ectopic Lumbar Kidney: A Case Report

Tohid Md. Saiful Hossain¹, Sk Nazibul Islam²

Abstract

Received: 13 - 02 - 2022
Accepted: 20 - 03 - 2022
Conflicts of interest: None

The chance of the development of hydronephrosis and the formation of stones is more in the ectopic kidney. Treatment of stones in ectopic kidneys is challenging for urologists due to abnormal location and rotation of the kidney and unfavourable local anatomy. We herein report a case of stone in a lumbar kidney successfully managed by mini percutaneous nephrolithotomy (PCNL) in a prone position. A 55-year-old male presented with right lower abdominal pain. His CT scan of the KUB reveals the right kidney is in an ectopic location and has a hyperdense structure measuring about 15 mm in length, seen in the right renal pelvis with mild dilatation of the pelvicalyceal system. The patient underwent right-sided prone mini PCNL under the subarachnoid block (SAB), and complete stone clearance was achieved. There was no adverse event during or after surgery or post-operative blood transfusion.

Keywords: Ectopic Kidney stone, Lumbar Kidney, Mini PCNL

Introduction

With the advancement of extracorporeal shock wave lithotripsy (ESWL) and endourology, renal lithiasis treatment has greatly advanced. The presence of anatomical anomalies, such as the ectopic kidney, imposes limitations on such therapeutic procedures¹. According to Campbell's Urology 12th edition, when a mature kidney cannot reach its normal location, it is known as renal ectopia. Among autopsy series, the reported incidence of renal ectopia varies from 1 in 500 to 1 in 1200, with an average occurrence of about 1 in 900, there is no significant gender difference, and the left side is slight, more than the right side². The chance of the development of hydronephrosis and the formation of stones is more in the ectopic kidney³. Renal lithiasis in the ectopic kidney can be managed through open surgery, ESWL, percutaneous nephrolithotomy (PCNL), and retrograde intrarenal surgery (RIRS). Open surgery is associated with higher morbidity, is less aesthetic due to the incision, and

causes more pain postoperatively. Only 54% stone clearance is reported in ESWL in such cases⁴. Percutaneous surgery can be done, but it is not conducted in a conventional way⁵. There are some differences from conventional PCNL, such as patient position and renal access; for the patient's position, a supine position is usually required, and for the access, fluoroscopy with ultrasonographic or laparoscopic guidance is used to protect the bowel or prevent major blood vessels injury⁶.

We herein report a case of stone in a lumbar kidney successfully managed by mini PCNL in a prone position.

Case Report

A 55-year-old male presented with right lower abdominal pain. The pain was dull aching, mild to moderate in intensity, non-radiating, and associated with nausea. There was no aggravating or relieving factor except analgesics. He has no history of

1. Professor, Department of Urology, Bangabandhu Sheikh Mujib Medical University, Shahbag, Dhaka, Bangladesh

2. Resident, Department of Urology, Bangabandhu Sheikh Mujib Medical University, Shahbag, Dhaka, Bangladesh

Correspondence : Dr. Tohid Md. Saiful Hossain, Professor, Department of Urology, Bangabandhu Sheikh Mujib Medical University, Shahbag, Dhaka, Bangladesh

hematuria, graveluria, cloudy urine, and fever with chills & rigour. His ultrasonogram of the whole abdomen showed the right kidney at the lumbar position, and a bright echogenic structure casting an acoustic shadow was present at the renal pelvis. His plain X-ray kidney ureter and bladder region (KUB) was normal (Fig:1). CT scan of the KUB region was

done, and it reveals right kidney is in an ectopic location and seen in pre vertebral region at the L4 level, the kidney is mal rotated, A hyperdense structure measuring about 15 mm in length is seen in the right renal pelvis with mild dilatation of pelvicalyceal system (Fig:2 &3). The left kidney is normal in size and position, but mal rotated (Fig:4).

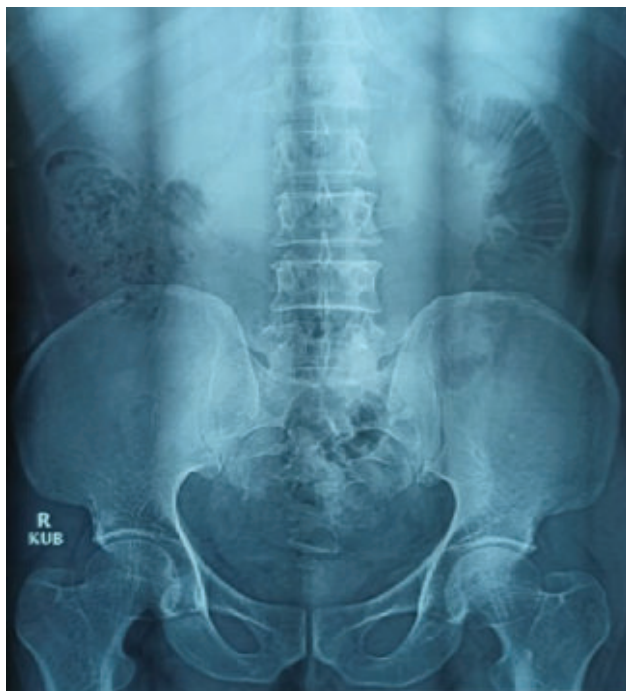

Fig-1

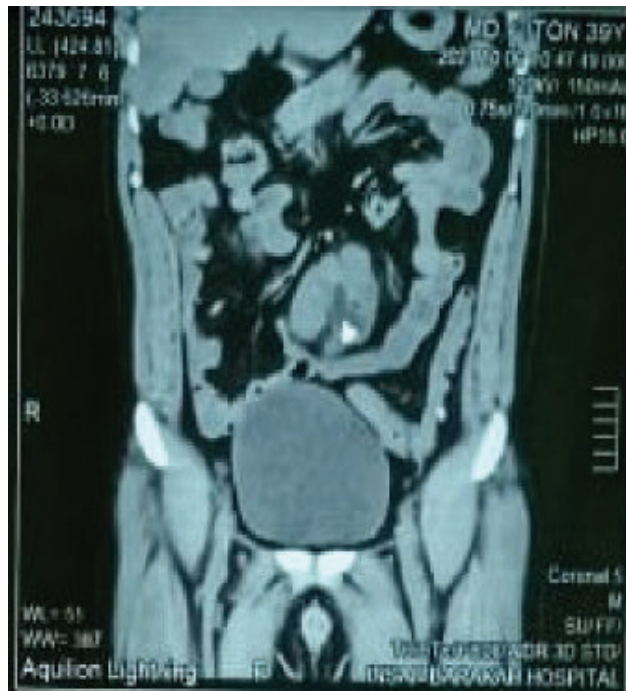

Fig-2

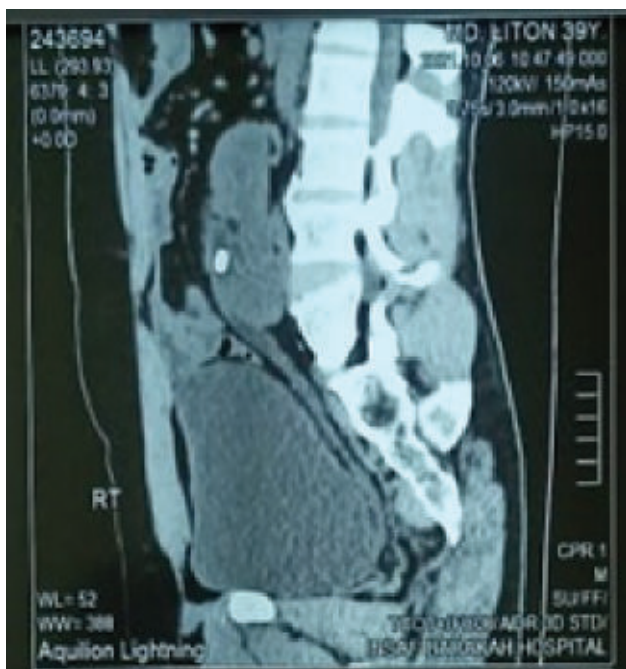

Fig-3

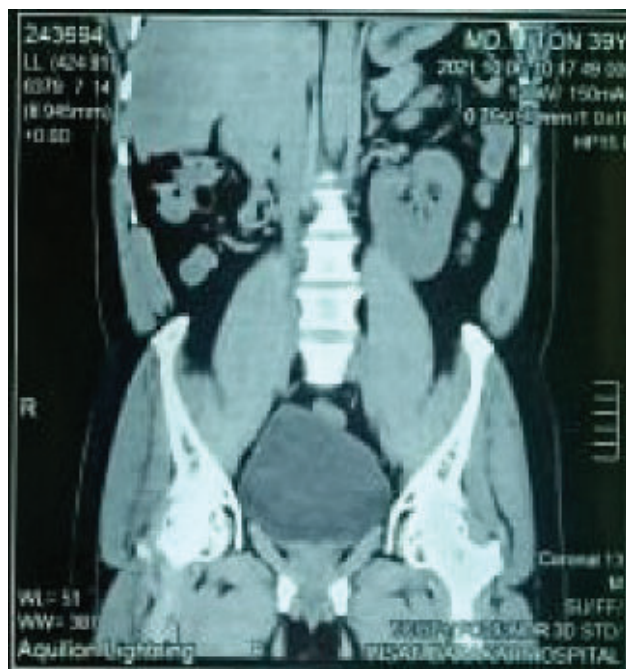


Fig-4

Right-sided prone mini PCNL operation was planned. A 6F ureteral catheter was placed at the right ureter under the subarachnoid block (SAB) with the help of a cystoscope. The puncture was made medial to posterior axillary line 2 cm above the right posterior superior iliac spine with aid of a fluoroscope and contrast. A guidewire was placed through the middle calyx of the right kidney up to the urinary bladder. The tract was dilated using Karl Storz single-step dilator over the guide wire. A 16.5 Fr Karl Storz am Platz sheath was introduced. Stone was visualized with a nephroscope, fragmented by a pneumatic lithotripter, and extracted by vacuum effect & grasping forceps. Complete stone clearance was confirmed by nephroscopy. right-sided double J stenting is done. A 14 Fr Nelaton catheter was used as a nephrostomy tube. The total time for surgery was 55 minutes. There was no adverse event during or after surgery and no post-operative blood transfusion. The post-operative requirement of analgesia was minimum, with only some diclofenac suppositories. The nephrostomy tube was removed after 24 hours. Urine was clear, and the catheter was removed on 2nd post-operative day. The patient was discharged to home on the 3rd post-operative day.

Discussion

Treatment of stones in ectopic kidneys is challenging for urologists due to abnormal location and rotation of the kidney and unfavourable local anatomy. ESWL in the prone position was introduced as a noninvasive method for managing patients with ectopic kidney stones in 1988⁷. However, ectopic kidneys had a lower stone-free rate than normal kidneys (56% vs 78%, respectively), and normal kidneys had a lower rate of clinically insignificant residual fragments than ectopic kidneys (18.5% vs 37%, respectively)⁸. RIRS is another option, but it is not suitable for large stones and also difficult for anatomic alterations, including a tortuous ureter and mal-rotated kidney⁹. Open surgery is associated with higher morbidity due to large scars, bowel manipulation, abnormal vessel position, and increased post-operative pain¹⁰. PCNL is a first-line treatment option for removing large kidney stones, but the approach should differ in the ectopic or transplanted kidney⁶. The ectopic kidney is in the retroperitoneum, and interposing bowel loops between the anterior abdominal wall and the ectopic kidney. Thus, a blind percutaneous transperitoneal approach to an ectopic kidney can cause injury to the bowel and

should be avoided¹¹. Laparoscopic-assisted PCNL in the Trendelenburg position helps prevent such injury⁵. Prone position supra-iliac approach to the ectopic pelvic kidney may result in post-operative incomplete femoral neuropathy due to probable trauma to the dorsal divisions of the lumbar plexus¹². In a prone position, injury to the posterior renal artery is more due to abnormal rotation of the kidney¹³. In our case, prone position supra ileac access to the middle calyx of the lumbar kidney was possible by a mini nephroscope. There was no bowel injury or significant intraoperative complication. No blood transfusion was needed. Complete stone clearance was achieved.

Conclusion

Mini PCNL is an effective treatment modality for stones in ectopic kidneys. It is associated with high stone clearance and good patient satisfaction.

References

1. Matlaga BR, Assimos DG. Changing indications of open stone surgery. *Urology*. 2002 Apr 1;59(4):490-3.
2. Wein AJ, Partin AW, Dmochowski RR, Kavoussi LR, Peters CA, editors. *Campbell Walsh Wein Urology*. 3-Volume Set. 2020.
3. Paterson RF, Lifshitz DA, Kuo RL, Siqueira Jr TM, Lingeman JE. Shock wave lithotripsy monotherapy for renal calculi. *Int Braz J Urol*. 2002 Jul 1;28(4):291-301.
4. Gleason PE, Kelalis PP, Husmann DA, Kramer SA. Hydronephrosis in renal ectopia: incidence, aetiology and significance. *The Journal of Urology*. 1994 Jun 1;151(6):1660-1.
5. HOLMAN E, TÓTH C. Laparoscopically assisted percutaneous transperitoneal nephrolithotomy in pelvic dystopic kidneys: experience in 15 successful cases. *Journal of Laparoendoscopic & Advanced Surgical Techniques*. 1998 Dec; 8(6):431-5.
6. Stein RJ, Desai MM. Management of urolithiasis in the congenitally abnormal kidney (horseshoe and ectopic). *Current opinion in urology*. 2007 Mar 1;17(2):125-31.
7. Jenkins AD, Gillenwater JY. Extracorporeal shock wave lithotripsy in the prone position: treatment of stones in the distal ureter or anomalous kidney. *The Journal of Urology*. 1988 May 1;139(5):911-5.

8. Demirkesen O, Yaycioglu O, Onal B, Kalkan M, Tansu N, Yalcin V, Kural AR, Solok V. Extracorporeal shockwave lithotripsy for stones in abnormal urinary tracts: analysis of results and comparison with normal urinary tracts. *Journal of endourology*. 2001 Sep 1;15(7):681-5.
9. Weizer AZ, Springhart WP, Ekeruo WO, Matlaga BR, Tan YH, Assimos DG, Preminger GM. Ureteroscopic management of renal calculi in anomalous kidneys. *Urology*. 2005 Feb 1;65(2):265-9.
10. Dodia BV, Mahajan A, Patil M, Bathe S, Darakh P. Laparoscopy guided PCNL in a stone holding previously operated ectopic pelvic kidney. *Int J Curr Microbiol Appl Sci*. 2017;6:975-.
11. Matlaga BR, Kim SC, Watkins SL, Kuo RL, Munch LC, Lingeman JE. Percutaneous nephrolithotomy for ectopic kidneys: over, around, or through. *Urology*. 2006 Mar 1;67(3):513-7.
12. Monga M, Castañeda-Zuñiga WR, Thomas R. Femoral neuropathy following percutaneous nephrolithotomy of a pelvic kidney. *Urology*. 1995 Jun 1;45(6):1059-61.
13. Yano H, Konagai N, Maeda M, Itoh M, Kuwabara A, Kudou T, Ishimaru S. Abdominal aortic aneurysm associated with crossed renal ectopia without fusion: case report and literature review. *Journal of vascular surgery*. 2003 May 1;37(5):1098-102.