

Short communication

MORPHOMETRY OF SPLEEN WITH SPECIAL EMPHASIS ON ITS ARTERIAL CIRCULATION OF INDIGENOUS HORSE IN BANGLADESH

M. S. Alam¹, M. A. Awal, S. K. Das and M. N. Islam²

Department of Anatomy and Histology, Faculty of Veterinary Science, Bangladesh Agricultural University, Mymensingh-2202, Bangladesh

ABSTRACT

The creamy-white colored spleen of Bangladeshi horse was triangular, comma shaped. The mean length was 19.187 ± 0.394 cm, width was 6.287 ± 1.156 cm and thickness was 1.437 ± 0.260 cm. It was supplied by single splenic artery, which was the largest branch of the coeliac artery. The coeliac artery was given several branches 0.7 cm away from the abdominal aorta and the main branch was the splenic artery. The main stem of splenic artery runs away from the hilus to the apex and gave off seventeen prominent branches that was entered into the parenchyma of spleen as it was situated superficially on the visceral surface. Among these branches, the most cranial one, just 0.8 cm deep from the hilus gave off several sub-branches that supplied the major basal portion of the spleen.

Key words: Morphometry, arterial circulation, spleen, horse

INTRODUCTION

The spleen is the largest lymphatic organ in the body. It plays multidisciplinary functions. Although it does not filter or clean the lymph but purifies the blood itself by filtering the worn-out blood cells from the blood stream and foreign substances of plasma (Copenhaver *et al.*, 1975; Leeson and Leeson, 1967). Besides its function as blood filtering organ, the architecture of spleen provides evidence to consider this as an organ of blood storage. The anatomy of spleen and its arterial supply of water buffalo (Mia *et al.*, 1981), in bovine (McLeod *et al.*, 1964), Black Bengal goat (Ahmed *et al.*, 1982), in man (Gray, 1973), in dog (Miller *et al.*, 1964) have been studied in details. But practically no work has yet been done on the spleen of horse in Bangladesh. Considering these, the present work was intended to study the morphometry with arterial supply of spleen of horse in Bangladesh.

MATERIALS AND METHODS

The study was conducted in the Department of Anatomy and Histology, Faculty of Veterinary Science, Bangladesh Agricultural University, Mymensingh, Bangladesh during the period from January to June 2002. Four apparently healthy adult horses were used in this study. After proper anaesthetic measures, the animals were bled to kill by incision of the left common carotid artery. Then the animals were fixed with 10% buffer neutral formalin. After opening the left side of the abdominal cavity the topography of the organs, color, length, breadth and thickness of the organs were studied. Then the dissection was made to trace-out the origin of the splenic artery, the branch of the coeliac artery. The branching and distributions of the splenic artery inside the organ were studied with the help of magnifying glass and by dissecting microscope.

RESULTS AND DISCUSSION

The spleen of horse of Bangladesh was triangular, comma shaped. It was partially agreed with the other species, where in sheep (Getty, 1975), it was approximately triangular and rounded angles, in bovine and water buffalo (McLeod *et al.*, 1964; Mia *et al.*, 1981) long and narrow with rounded extremities; in dog (Miller *et al.*, 1964) roughly tongue shaped and in Black Bengal goat (Ahmed *et al.*, 1982) was quadrangular shaped spleen. It was situated chiefly in the left side of the abdomen, in close relation to the left part of the greater curvature of the stomach. It extends obliquely in a curved direction, corresponding to the left part of the greater curvature of the stomach, from the left crus of the diaphragm to the ventral third of the 10th or 11th rib.

Present address: ¹Department of Anatomy and Histology, Dinajpur Government Veterinary College, Dinajpur, Bangladesh, ²Department of Anatomy and Histology, Sylhet Government Veterinary College, Sylhet, Bangladesh.

The color of spleen in the present study was creamy-white. The mean length was 19.187 ± 0.394 cm, width 6.287 ± 1.156 cm and the thickness was 1.437 ± 0.260 cm (Table 1) whereas, Sisson and Grossman (1975) observed the length of about 20 cm and width of 6 cm at the base of spleen of horse.

Table 1. Length, width and thickness of the spleen of horse

Sample No.	Length (cm)		Width (cm)		Thickness (cm)	
	Maximum	Minimum	Maximum	Minimum	Maximum	Minimum
1	20.2	18.9	10	3.8	2.2	0.7
2	20.8	18.1	9.2	3.2	2.1	0.8
3	19.7	17.9	8.9	3.1	2.1	0.7
4	19.9	18.9	9.2	2.9	2.1	0.8
Mean \pm SE	19.187 ± 0.394		6.287 ± 1.156		1.437 ± 0.260	

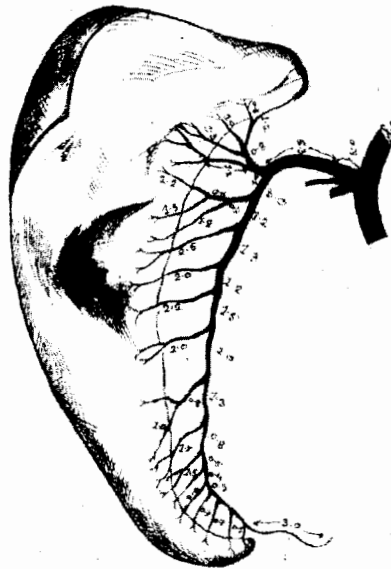


Fig. 1. Diagram showing the blood supply of spleen of horse (Unit of length of artery is cm)

The spleen of horse was supplied by single splenic artery, which was the largest branch of the coeliac artery. The coeliac artery was given several branches 0.7 cm away from the abdominal aorta; the main branch was the splenic artery. The splenic artery entered obliquely into the spleen through the hilus and it was unbranched up to 6.3 cm from its point of origin. The hilus was situated on the visceral or medial surface of spleen. The visceral surface of spleen was divided into two unequal parts by a longitudinal ridge; on this there was a groove, the hilus. These findings were same as reported in dog (Miller *et al.*, 1964), sheep (Vereby, 1943) and man (Gray, 1973). On the other hand, Mia *et al.* (1981) in water buffalo reported three primary branches of splenic arteries originating from two sources, one from the coeliac artery and other two in a common stem from the cranial mesenteric artery.

In the present investigation, the main stem of splenic artery runs away from the hilus to the apex and gave off seventeen prominent branches that was entered into the parenchyma of spleen as it was situated superficially on the visceral surface. Among these branches, the most cranial one, just 0.8 cm deep from the hilus gave off several sub-branches that supplied the major basal portion of the spleen. The splenic vein runs in the hilus in accompany with the artery and nerves, and joins the gastro-duodenal vein to form a large radical of the portal vein.

REFERENCES

1. Ahmed MU, Mia, AKMA and Khan MAB (1982). The arterial supply and its segmentation inside the spleen of Black Bengal goat. *Bangladesh Veterinary Journal* 15: 23-25.
2. Copenhaver WM, Bunge RP and Bunge MB (1975). *Bailey's Text Book of Histology*. 16th edn., The Willams and Wilkins Com., Baltimore 21202, USA.
3. Getty R (1975). *Sisson and Grossman's The Anatomy of the Domestic Animals*. Vol. 1. 5th edn., W. B. Saunders Co., Philadelphia, USA.
4. Gray H (1973). *Gray's Anatomy*. 35th edn., Longman Group Ltd., London.
5. Leeson CR and Leeson TS (1967). *Histology*. W.B. Saunders Co., Philadelphia, London.
6. McLeod WM, Trotter DM and Lumb JW (1964). *Bovine Anatomy*. 2nd edn., Burgess Publishing Co.
7. Mia AKMA, Mia MA and Khan MAB (1981). The arterial supply to the spleen of water buffalo. *Bangladesh Veterinary Journal* 15: 29-32.
8. Miller ME, Christenson GC and Evens HE (1964). *Anatomy of the Dog*. W.B. Saunders Co., Philadelphia, London.
9. Sisson S and Grossman J (1975). *The Anatomy of the Domestic Animals*. 5th edn., Vol. 1, W.B. Saunders Co., Philadelphia, London.
10. Vereby K (1943). Vergleichende untersuchunden uber die kapsel, trabekol un gefasse der mix, I. die milz des schafus and des rindes.