

**MACRO-ANATOMY OF THE BONES OF THE FORELIMB OF
BLACK BENGAL GOAT (*CAPRA HIRCUS*)**

M. S. I. Siddiqui^{1,2}, M. Z. I. Khan¹, S. Moonmoon³, M. N. Islam¹ and M. R. Jahan¹

¹Department of Anatomy and Histology, Faculty of Veterinary Science, Bangladesh Agricultural University, Mymensingh-2202, ²Department of Anatomy and Histology, Faculty of Veterinary and Animal Science, Sylhet Agricultural University, Sylhet, ³Department of Biotechnology, Faculty of Agriculture, Bangladesh Agricultural University, Mymensingh-2202, Bangladesh

*Corresponding author's e-mail: msisiddiqui2000@yahoo.com

ABSTRACT

In the present study, five Black Bengal goats (*Capra hircus*) were used to investigate the bones of fore limb during January to June 2006. It was observed topographically that the scapula was more or less similar to other ruminant animal topographically with exception that, the presence of very short coracoid process, more or less oval shaped glenoid cavity and more extensive subscapular fossa. The humerus of adult Black Bengal goat was 12.06 ± 0.27 cm in length. The diameter of shaft at the level of nutrient foramen was 4.24 ± 0.05 cm. The breadth of humerus was 1.66 ± 0.06 cm. The deltoid tuberosity was less prominent and there was shallow radial and olecranon fossa. The radius of adult Black Bengal goat was 11.12 ± 0.23 cm in length. The diameter of shaft of radius-ulna just below the interosseous space was 3.86 ± 0.12 cm. The total length of ulna of adult Black Bengal goat was 14.20 ± 0.20 cm. The interosseous space was found very narrow in the present study. Six carpal bones arranged in two rows, four in proximally and two in distally were found in Black Bengal goat. Two fully developed digits were found in Black Bengal goat. Each digit had three phalanges. The total length of proximal phalanx of adult Black Bengal goat was 2.88 ± 0.08 cm, in the middle phalanx it was 1.88 ± 0.03 cm and in distal phalanx the length was 2.56 ± 0.05 cm. In conclusion the present data suggest that, the anatomy of the bones of fore limbs of Black Bengal goat was differed slightly, both structurally and morphometrically with other ruminants and varied widely with non-ruminant animals.

Key Words: Macro-anatomy, fore limb, skeleton, black bengal goat

INTRODUCTION

The goat is the only recognized breed of Bangladesh. According to the FAO (1998), there were 35 millions of goat in our country, of which, mostly are Black Bengal goat, whose hides and skin are very famous in the world. About 13.2% of the country's GDP comes from livestock and poultry sector. Very recently Government has taken "Poverty alleviation programme by increasing goat production" The skin and hides of Black Bengal goat are very famous in foreign countries. Bangladesh earn 500 crore of foreign money every year by exporting hides and skin. The muscular growth of Black Bengal goat is directly related with the growth of long bones. So student as well as veterinary practitioners must possess clear conception about goat osteology. There were some macro-anatomical investigations on the skeletal systems of large animals such as horse and cattle (Getty, 1975), small ruminants such as sheep (Getty, 1975), carnivores such as dog (Evans and Christensen, 1979), wild carnivores such as the mink and from the order of Rodentia such as guinea pig and rat (Ozkan *et al.*, 1997; Yalmaz S. 1998), and from the order Lagomorpha such as rabbit (Ozkan *et al.*, 1997), but the skeletal systems of Black Bengal goat have not been investigated in detail.

Therefore the literature on the macro-anatomical features of the skeletal system of Black Bengal goat is meager (Khan *et al.*, 1998), and the aim of the present study is to investigate the Macro-anatomical investigations on the forelimb skeleton of Black Bengal goat (*Capra hircus*) and to contribute to the present level of information.

MATERIALS AND METHODS

A total of five adult Black Bengal goats of both sexes were purchased from the local market during January to June 2006. Fore limb were then collected after slaughtering from each of the Black Bengal goat in the department of Anatomy and Histology, Bangladesh Agricultural University for this study. The skin fascia and muscles were removed from the bones. Then the bones were boiled in soap water for long time for the easy removal of muscle tendons and ligaments. Before boiling, each fore limb was wrapped separately with net to prevent the loss of small bones. After boiling the remained muscles and tendons were removed and washed with tap water. The bones were washed with bleaching powder to remove the unpleasant smell and dried with sunlight for two days and finally kept in the room temperature for gross study.

For gross biometrical study total length, width or breadth of the scapula, humerus, radius-ulna, carpus, metacarpus, and digits were measured. Arithmetic mean (AM) and Standard deviation (SD) were calculated by using statistical method.

RESULTS AND DISCUSSION

Scapula

It was a flat bone situated on the cranial part of the lateral wall of the thorax. It was curved slightly and sloped laterally in adaptation to the form of the thoracic wall. It was triangular in outline and relatively wider at the dorsal end and narrower at the ventral end (Fig. 1a). The scapula of goat in the present study has been represented three borders, three angles and two surfaces which were found to be similar to those of horse (Getty, 1975), cattle (McLeod, 1958), sheep (Getty, 1975), and dog (Millers, 1964). The spine of the scapula of Black Bengal goat extended up to the neck of the bone. The free edge was prominent. The acromion process was thick and pointed (Fig 1a). However, in contrast, the spine of the scapula subsided at the neck of the bone in horse (Getty, 1975). In cattle the free edge of spine not subsided but formed prominent acromion process (McLeod, 1958, Getty, 1975). In dog the acromion process was also found to be prominent (Evans and Chirstensen, 1979). In the cat however, the free edge of the spine of scapula was prominent and contained a curved process (Reighard, 1935). The nutrient foramen in the scapula of goat was found at the neck of the scapula (Fig 1a), which was similar to horse (Getty, 1975), cattle (McLeod, 1958) and sheep (Getty, 1975). The glenoid cavity of goat's scapula was mostly circular and deep (Fig 1b), which was oval in outline in horse (Getty, 1975), circular in cattle (McLeod, 1958) and sheep (Getty, 1975), shallow in the dog (Evans and Chrisensen 1979), and pear shaped fossa in cat (Reighard, 1935). Supra glenoid tubercle in the present study was small and close to the glenoid cavity which were in similar with the Getty (1975) in cattle and dissimilar with horse (Getty, 1975), dog (Evans and Chrisensen, 1979) and cat (Reighard, 1935). The glenoid cavity was found without any distinct glenoid notch which were similar to cattle (McLeod, 1958), sheep (Getty, 1975) and dissimilar to horse (Getty, 1975), dog (Evans and Chrisensen, 1979) and cat (Reighard, 1935). In the present study tuber spine in goat were found absent which was, however, prominent in horse (Getty, 1975) but not distinct in cattle (McLeod, 1964), sheep (Getty, 1975) and dog (Millers, 1964). In the present study the subscapular fossa in goat scapula was observed more extensive, in contrast, in horse it was deep (Getty, 1975) and in cattle it was shallow (Getty, 1975). The total length of scapula with scapular cartilage in adult Black Bengal goat was 13.94±0.30cm (Table 1). The width of scapula at medial surface from cranial angle to caudal angle was 6.62±0.11cm (Table 1). The diameter at distal end was 3.88±0.31cm (Table 1).

Humerus

The humerus was a long bone situated obliquely downward and backward; forms shoulder joint above with the scapula and elbow joint below with the radius and ulna. The shaft was twisted cylindrical and presented four surfaces. The lateral surface is spiral, smooth, and presented a musculospiral groove (Fig. 2a). In the humerus, deltoid tuberosity of the Black Bengal goat was found less prominent (Fig 2a). Similar ovservation was reported in cattle (Getty, 1975) and sheep (Getty, 1975). The radial and olecranon fossa of the humerus of Black Bengal goat were shallow (Fig. 2a, 2b) which was disagreement of (Getty, 1975) in cattle where these fossae were deep and wide and in dog these two fossae often communicate each other through a large supratrochlear foramen. In the present study the shallow musculospiral groove of the humerus of goat was observed (Fig. 2a). This was in agreement with the reports of Getty (1975) in cattle and sheep.

Macro-anatomy of forelimb skeleton of goat

The epicondylid crest of humerus was found prominent in goat, which was inconsistent with the report in cattle (McLeod, 1958) sheep (Getty, 1975) and dissimilar in horse (Getty, 1975) and dog (Millers, 1964). The nutrient foramen of the humerus in the present study were situated about the middle of the caudal surface of humerus which was similar to sheep (Getty, 1975) and dissimilar to cattle (McLeod, 1958), where the nutrient foramen was located at distal third of the lateral surface of humerus. The total length of humerus of adult Black Bengal goat was 12.06 ± 0.27 cm (Table 1). The breadth at proximal end (cranial to caudal border) was 1.66 ± 0.06 cm (Table 1). The breadth at distal (lateral to medial border at the level of nutrient foramen) was 1.46 ± 0.04 cm (Table 1). The diameter of the shaft at the level of nutrient foramen was 4.24 ± 0.05 (Table 1).

Radius and ulna

The radius was short and relatively broad. It was somewhat oblique; forms elbow joint with the humerus above and carpal joint with the carpal bones below. The bone was faintly curved and presents a shaft and two ends. The long shaft was flattened craniocaudally and curved longitudinally. It presented four surfaces. The anterior surface was convex and smooth. Below, this surface presented three grooves for the accommodation of the tendons of extensor muscles. At the middle of the upper part of this surface there was a rough elevation, known as radial tuberosity (Fig. 3). The posterior surface was concave and throughout the whole length along the lateral part, it was attached with the cranial surface of the shaft of the ulna excepting at two interosseous spaces (Fig. 3). The distal interosseous space was small and indistinct (Fig. 3). The lateral surface was rounded and smooth. The medial surface was smooth. The proximal end articulates with the condyles of the humerus and therefore, possesses two articular surfaces separated by a groove. The cranial rim of this articular surface presents a projection, known as coronoid process (Fig. 3). The medial and lateral tuberosities were placed at the corresponding aspect of this end just below the margin of the articular surface. The distal end articulated with the proximal row of carpal bones and presents three articular surfaces. The total length of radius of adult Black Bengal goat was 11.12 ± 0.23 cm (Table 1). The diameter of shaft of radius-ulna just below the interosseous space was 3.86 ± 0.12 cm (Table 1).

Ulna was an ill developed long bone, fused with the radius along its caudolateral aspect. The shaft was roughly prismatic. It had surfaces and three borders. The anterior surface was fused with the posterolateral aspect of the radius excepting at the proximal and distal interosseous spaces (Fig. 3). This surface at the level of proximal interosseous space was in the form of an arch. At the upper part of this surface there were two articular facets for articulation with the corresponding facets of radius. The medial surface is smooth, concave and blends with the posterior surface. Lateral surface was narrow and presented a faint ridge. Out of the three borders, the medial and lateral borders were fused with the radius and the posterior one was smooth and concave on its length. The proximal end was expanded and comprised of one large olecranon process and a semilunar notch (Fig. 3). The olecranon process had two surfaces and two borders. The lateral surface is convex and the medial surface was concave. The anterior border was limited by semilunar notch and there by formed a beak like projection, known as anconeal process (Fig. 3). The semilunar notch was smooth and broader distally. The distal end was projected downward and fused with the radius for the formation of the lateral facet for the ulnar carpal bone. This pointed projection was known as styloid process (Fig. 3). The total length of ulna of adult Black Bengal goat was 14.20 ± 0.20 (Table 1). The breadth of radius-ulna at distal end was 1.10 ± 0.06 cm (Table 1).

In the goat of the present study, the ulna extend up to the distal extremity of the radius, which was in agreement with the cattle (McLeod, 1958), sheep (Getty, 1975) and disagreement with the horse, (Getty, 1975), where the ulna was fused at the proximal third of the radius. The styloid process in black Bengal goat of the present study, was observed similar to cattle, (Getty, 1975), which were however absent in horse (Getty, 1975). In the goat, the interosseous space was two in number located, one proximally (larger) and other distally (thin and smaller). Similar observations were noted in cattle (Getty, 1975), sheep (Getty, 1975) and in the horse, there was only one proximal interosseous space was noted (Getty, 1975).

Carpal bones

In the present study, the carpal bones of Black Bengal goat were six in number, which were arranged in two rows, four in the proximal row and two in the distal row. All the six surfaces were irregular. The dorsal articular surfaces of these bone presented irregular outline. The ventral surfaces had an anterior convexity and a posterior concavity. Anterior medial and posterior surfaces were continuous and rough. The lateral surface was articular.

The intermediates carpal was situated between the radial and ulnar carpal bones (Fig. 4a). These observations were similar to report of cattle (McLeod, 1958), sheep (Getty, 1975) and differs with horse (Getty, 1975) and dog (Evans, 1979). In the present study of goat, the proximal row was consisting of radial, intermediate, ulnar and accessory carpal (Fig 4a). The distal row was consisting of second and third fused carpal and fourth carpal. The first carpal was absent in distal row (Fig 4b). This was agreement of Getty (1975) in cattle, sheep and disagreement of Getty (1975) in horse, where the proximal row consist of radial, intermediate, ulnar, and accessory carpal and the distal row were consist of first, second, third and fourth carpal.

Metacarpal bone

In the present study of Black Bengal goat, only the large metacarpal bone was present which consist of III and IV. Other metacarpal bones were absent. The small metacarpal bone (metacarpal-v) was present in cattle (McLeod, 1964). This was disagreement of Getty (1975) in horse, where three metacarpal bones were present in which the third was fully developed and the second and fourth were much fused with the third and commonly known as small metacarpal or “splint bones”. First and fifth were absent. In the present study, of Black Bengal goat, dorsal longitudinal groove was found in metacarpus (Fig. 5). This was similar in cattle (Getty, 1975) and dissimilar in horse (Getty, 1975). The total length of metacarpus of adult Black Bengal goat was 8.02 ± 0.14 cm (Table 1). The breadth at proximal end was 0.98 ± 0.03 cm (Table 1). The breadth at distal end was 0.92 ± 0.03 cm (Table 1). The diameter of shaft was 3.40 ± 0.07 cm (Table 1).

Digits of black Bengal goat

In the present study, two fully developed digits (III) and IV) were observed in each forelimb of Black Bengal goat. Second and fifth were remaining as dewclaw. First is absent. This was agreement of Getty (1975) in cattle and disagreement of Getty (1975) in horse where, only one digit was found in each leg.

Proximal phalanx

It was an elongated bone situated between the metacarpal bone and second phalanx (Fig. 6a). The dorsal and lateral surfaces are continuous. Axial surface was flat and rough. The proximal end is broad and bears a concave articular surface, which was divided by a groove. The lateral portion was larger. Posteriorly there were two articular facets. The distal end was condyloid. The lateral condyle was larger (Fig. 6a). The total length of proximal phalanx of adult Black Bengal goat was 2.88 ± 0.08 cm (Table 1). The breadth at proximal end was 1.08 ± 0.04 cm (Table 1). The breadth at distal end was 0.82 ± 0.08 cm (Table 1). The diameter of shaft of first phalanx was 2.90 ± 0.04 cm (Table 1).

Middle phalanx

This bone was shorter than the proximal phalanx and situated between the first and distal phalanges (Fig. 6b). The shaft had three surfaces. The lateral surface was rounded and irregularly concave. The posterior surface was flat and the axial surface was depressed. The proximal end presents two concave facets for corresponding condyles of the proximal phalanx. At the posterior aspect there were two tubercles. The distal end was condyloid. The lateral condyle was larger. The total length of middle phalanx of adult Black Bengal goat was 1.88 ± 0.03 cm (Table 1). The breadth at proximal end (lateral to medial surface) was 0.94 ± 0.05 cm (Table 1). The breadth at distal end was 0.78 ± 0.02 cm (Table 1). The diameter of shaft of middle phalanx was 2.48 ± 0.03 cm (Table 1).

Distal phalanx

The distal phalanx resembled the shape of a hoof in which the whole of the bone was situated. Proximally it articulated with the distal end of the middle phalanx. It presented four surfaces. The abaxial surface was convex, rough and traversed by a cranio-caudal groove. At the distal part there were several perforations for vessels (Fig. 6c). The axial surface was rough above and smooth below. There was a groove at the distal part (Fig. 6c). The articular surface possesses concavities for condyles of the middle phalanx. The solar surface was slightly concave and flat. The total length of distal phalanx of Black Bengal goat was 2.56 ± 0.05 cm (Table 1). The breadth of distal phalanx was 0.64 ± 0.05 cm (Table 1).

Macro-anatomy of forelimb skeleton of goat

Sesamoid bones

Four proximal sesamoid bones, two for each digit were present in black Bengal goat (Fig. 6c). These bones were placed palmar to the fetlock joint. Two distal sesamoid bones were present one for each digit. The distal sesamoid bones were placed palmarly in between the middle and distal phalanx.

Table 1. Length, width and diameter (mean±S.E) of scapula of adult Black Bengal goat (n = 5)

Name of bone	Total length of scapula with scapular cartilage	Width of scapula ^a	Diameter at distal end
Scapula	13.94 ± 0.30	6.62 ± 0.11	3.88 ± 0.13
Humerus	12.06 ± 0.27	1.66 ± 0.06	4.24 ± 0.05
Radius/Ulna	11.12 ± 0.23 / 14.20 ± 0.20	1.16 ± 0.06	3.86 ± 0.12
Metacarpus	8.02 ± 0.14	0.98 ± 0.03	3.40 ± 0.07
Proximal phalanx	2.88 ± 0.08	1.08 ± 0.04	2.90 ± 0.05
Middle phalanx	1.88 ± 0.03	0.94 ± 0.05	2.48 ± 0.03
Distal phalanx	2.56 ± 0.05	0.64 ± 0.05	---

^aWidth of scapula at medial surface from cranial angle to caudal angle.

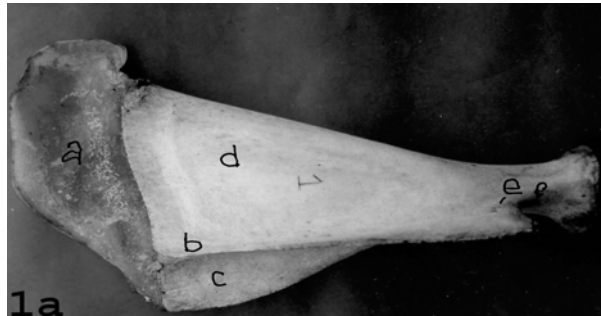

Fig. 1a. Scapula of Black Bengal goat (Lateral View) showing scapular cartilage (a), Scapular spine (b), Supraspinous fossa (c), Infraspinous fossa (d), Nutrient foramen (e), Neck (f), Supraglenoid tubercle (g) and Acromion process (h).

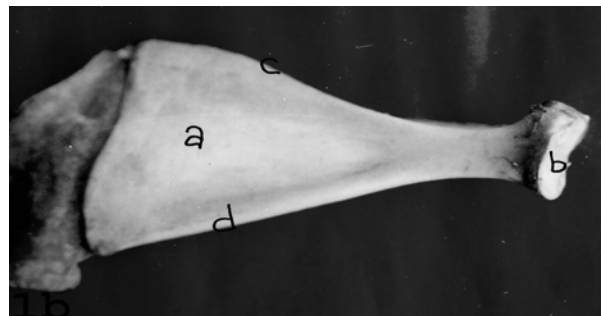


Fig. 1b. Scapula of Black Bengal goat (medial view) showing Subscapular fossa (a), Glenoid cavity (b), Cranial border (c) and caudal border (d).

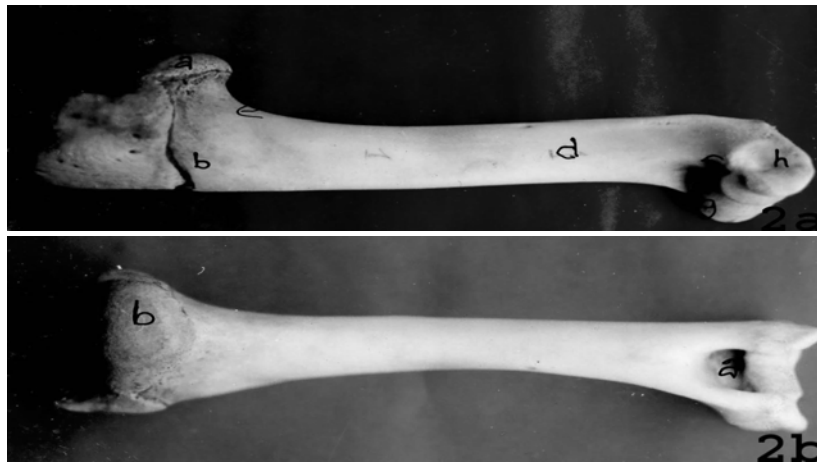

Fig. 2a. Humerus of Black Bengal goat (Lateral View) showing Head (a), Deltoid tuberosity (b), Teres Major tuberosity (c), Musculospiral groove (d), Neck (e), Radial fossa (f), Trochlea (g) and Capitulum (h).
 Fig. 2b. Humerus of Black Bengal goat (Medial View) showing Olecranon fossa (a) and Head (b).

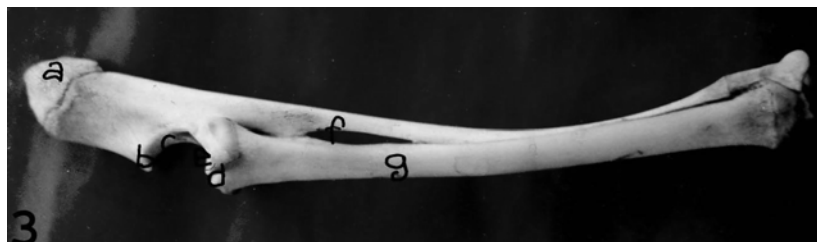

Fig. 3. Radius and Ulna of Black Bengal goat (Lateral View) showing Olecranon tuberosity (a), Anconeal Process (b), Trochlear notch (c), Radial tuberosity (d), Capitular fovea (e), Interosseous space (f) and Body of radius (g).

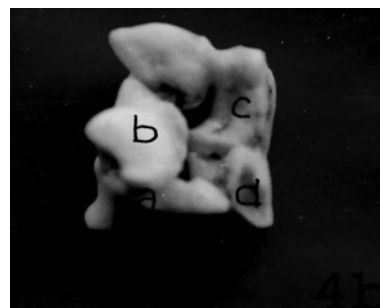



Fig. 4a. Carpal bones of Black Bengal goat (dorsal surface) showing Radial carpal (a), Intermediate carpal (b), Accessory Carpal (c), Second and third fused carpal (d) and Fourth carpal (e).
 Fig. 4b. Carpal bones of Black Bengal goat (palmar surface) showing Ulnar carpal (a), Accessory carpal (b), Second and third fused carpal (c) and fourth carpal (d).




Fig. 5. Metacarpus of Black Bengal goat (dorsal surface) showing Metacarpal tuberosity (a) and Articular facet (b).

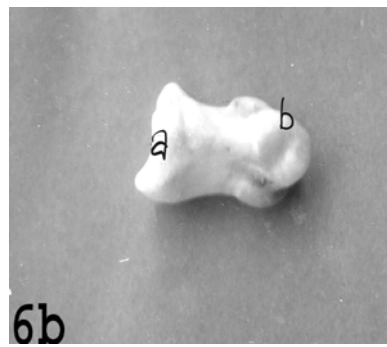
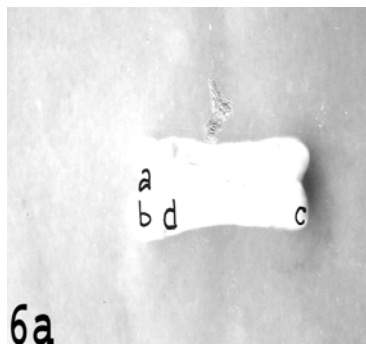


Fig. 6a. Proximal phalanx of Black Bengal goat (dorsal surface) showing Intermediate groove (a), Proximal articular surface (b), Distal articular surface (c) and Tuberosity (d).

Fig. 6b. Middle phalanx of Black Bengal goat (lateral surface) showing Proximal articular surface (a) and Distal articular surface (b).

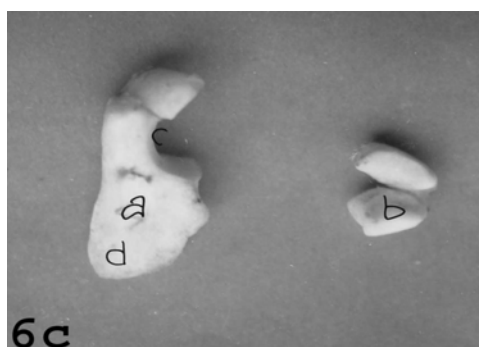


Fig. 6c. Distal phalanx (lateral surface) and Sesamoid bones of Black Bengal goat showing Distal Phalanx (a), Sesamoid bone (b), Groove (c) and Perforations for vessels (d).

REFERENCES

1. Evans and Christensen (1979). *Millers Anatomy of the dog*. 2nd edn., WB Saunders Company, Philadelphia, USA. pp. 177-196.
2. FAO (1998). *FAO Production Yearbook*. FAO of the United Nations. Rome, Italy. Vol. 51.
3. Getty R (1975). *The Sisson and Grossman's the Anatomy of the Domestic Animals*. Volume 1. 5th edn., WB Saunders Company, Philadelphia, USA. pp. 748-762.
4. Khan MZI, Hossain MI, Quasem MA and Ahmed MU (1988). The postnatal growth and development of bones of Black Bengal Goat (Appendicular skeleton). *Bangladesh Veterinary Journal* 22: 29-37.
5. McLeod WM, Trotter DM and Lumb JW (1958). *Bovine Anatomy*. Minneapolis, Burgess. pp. 643-657.
6. Miller ME, Christensen GC and Evans HE (1964). *Anatomy of the Dog*. WB Saunders Company, Philadelphia, USA. pp. 234-245.
7. Özkan ZE, Dýnç G and Aydin A (1997). Investigations on the comparative gross anatomy of scapula, clavícula, skeleton brachii and skeleton antebrachii in rabbits (*Oryctolagus cuniculus*), guinea pigs (*Cavia porcellus*) and rats (*Rattus norvegicus*). *Journal of Health Science* 11: 171-175.
8. Reighard (1935). *Anatomy of the cat*. Henry Holt and Company, New York. pp. 62-76.
9. Yilmaz S (1998). Macro-Anatomical investigations on the skeletons of porcupine (*Hystrix cristita*). *Anatomia Histologia Embryologia* 27: 293-296.