

Case Report

Abdominal wall metastasis of carcinoma breast : a case report

Bhattacharjee A¹, Russell M², Hasan MN³, Debnath BC⁴

Abstract

Abdominal wall metastasis from breast carcinoma is an uncommon occurrence compared to local invasion into muscle from direct tumor spread. A 30 years old lady was referred to our hospital from a medical college hospital for adjuvant treatment after being done the left sided modified radical mastectomy. Pathological examination revealed poorly differentiated infiltrative duct cell carcinoma, metastatic deposits in axillary lymph node with histological grade 3. She underwent adjuvant chemotherapy and radiotherapy with regular schedule and follow up. Her adjuvant treatment and follow up period were uneventful upto 13 months. Thereafter she reported a painless lump in the right upper abdomen which was rapidly growing in size. Cytopathology report confirmed that the cells of the parietal lump were compatible with metastatic duct cell carcinoma. So, though the primary pathology was in the left side but the parietal lump was found in the right side. Skeletal muscle metastasis is uncommon and pain is the commonest symptom. But here the lump is painless and this is another rare presentation. Treatment principle is only palliation.

Key words: Breast cancer, metastasis, abdominal wall.

Case Presentation

A 30 years old lady was referred from the medical college hospital after being done the Modified Radical Mastectomy of left side as she was a diagnosed case of carcinoma of left breast with left sided axillary lymphadenopathy due to metastatic deposits. Immunohistochemistry studies showed receptor status of tumor is triple negative. The cause of referral was to execute adjuvant therapy. Accordingly she underwent 6 cycle chemotherapy with AC, QW and

paclitaxel drug and subsequently 25 cycle radiotherapy. In each visit she was given follow up with tumor marker, baseline blood biochemistry and upper abdominal ultrasound. Upto the 15 months postoperatively her outcome was uneventful. Thereafter she noticed a nodular swelling in her right upper abdomen which was rapidly growing in size. With this complaints with no other feature of metastasis she was admitted into National Institute of Cancer Research & Hospital (NICRH). Her physical examination revealed a 2x2 cm non-tender lump, normal temperature, irregular surface, ill-defined margin, firm to hard in consistency, fixed with overlying skin and underlying skeletal muscle. The lump was non-compressible and non-reducible. We found 2 very small nodular swelling in the upper outer quadrant of her right breast, measuring about 0.5x0.5 cm along with two axillary lymph nodes of medial group in right side, largest one measuring 1x0.5 cm. Diagnostic work up including complete blood count, blood biochemistry and tumor marker CA 15-3 was done. Accordingly we found, raised ESR with mild neutrophilic leucocytosis; liver function and renal function tests were normal. Tumor marker was also normal. Ultrasonography of abdomen showed a parietal wall mass originating from the skeletal muscles and involved skin; the size and site was almost corresponding to the clinical findings. Sonography of her right breast found suspicious nodule but the right axilla found multiple lymph node enlargement of which two were larger in size. Upper abdominal CT scan showed a parietal lump (2.5x2 cm, isodense to muscle) in the right anterior abdominal wall involving the skin to external oblique muscle.(Figure-1)

1. *Dr. Abhishak Bhattacharjee, Department of Surgical Oncology, National Institute of Cancer Research & Hospital (NICRH), Dhaka, Bangladesh, E-mail: abhishakdr123@gmail.com.
2. Dr. Md. Russell, Department of Surgical Oncology, Bangabandhu Sheikh Mujib Medical University, Shahbagh, Dhaka.
3. Dr Md Nazmul Hasan, Medical officer, Department of Cardiology, Bangabandhu Sheikh Mujib Medical University, Shahbag, Dhaka, Bangladesh.
4. Dr Bidyut Chandra Debnath, Medical Officer, Department of Surgery, Bangabandhu Sheikh Mujib Medical University (BSMMU), Shahbag, Dhaka

*For correspondence

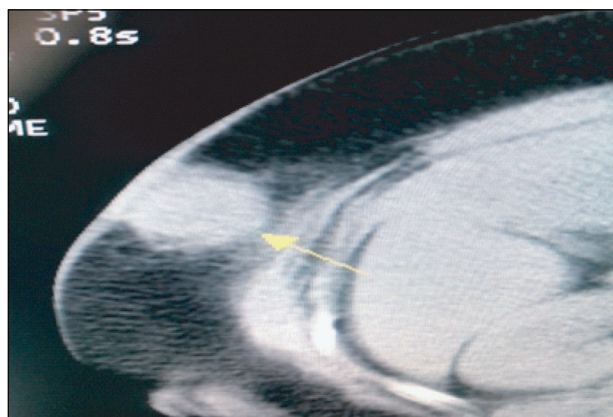


Figure-1: CT scan upper abdomen showing hyperdense shadow of abdominal wall mass

Cyto-pathology of lump shows that the cells were compatible with metastatic duct cell carcinoma. (Figure-2).

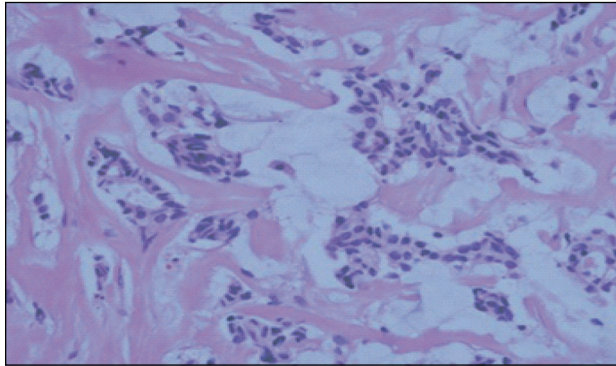


Figure-2: Diffuse scattered neoplastic cells with distraction of muscle fascicles. (H&E stain).

Discussion

Skeletal muscle metastasis at a distant site from the primary lesion is a very rare presentation. Because skeletal muscle is relatively resistant to metastatic disease for its hostile microenvironment. Factors that make skeletal muscle hostile include muscle motion resulting in mechanical tumor destruction, inhospitable muscle pH, the muscle's ability to remove tumor-produced lactic acid associated with angiogenesis, and the activation of lymphocytes and natural killer cells in skeletal muscle.^{1,2}

However, skeletal muscle metastasis from breast cancer is also a very uncommon presentation and is often manifested as disseminated disease with multiple organ metastasis.³ Only 15 cases have been reported so far upto our knowledge. Among them sites of metastasis were extraocular muscles, paraspinous muscles and gluteal muscles, with 3 cases each. Skeletal muscle metastasis is often the part of a disseminated disease with multiorgan involvement. But abdominal wall muscles metastasis from breast carcinoma was first reported by Ogiya et al. with a review of 13 previously reported cases of which four presented as an isolated skeletal muscle metastasis without other distant metastases. Though internal obturator lymph nodes were also present in their case report with no other distant metastasis.³ We have done an FNAC from the lump in the abdominal muscle to confirm our diagnosis.

Niikura et al⁴ reported that the incidence of discordance for ER, PR, and HER2 between primary and metastatic tumors was 18.4%, 40.3%, and 13.6%, respectively. We had the previous report of MRM of our patient but we didn't go for comparison of receptor status of primary lesion and metastatic site as our case was triple negative.

The clinical features of the metastatic carcinoma to skeletal muscles closely resemble those of soft tissue sarcomas in many respects.⁵ Skeletal muscle metastasis generally manifests itself as a painful mass in the involved area or may be an incidental finding in imaging studies without symptoms.⁶ Our patient presented with painless lump and it is the first reported case, to our knowledge, of painless lump as abdominal wall metastasis. Diagnosis is mainly confirmed by the needle biopsy. Radiological evaluation also plays a vital role in evaluating the mass. MR imaging with intravenous gadolinium enhancement is helpful when planning the biopsy of these lesions as it is useful to evaluate the vascularity of the tumor. Yilihamu Tuoheti et al believed that the extensive peritumoral enhancement associated with the central necrosis was one of the characteristic features of the skeletal muscle metastasis. This was found in 92% of the cases.⁷ MRI is the gold standard imaging and show the features of muscle metastases that are relatively typical, consisting of round or oval intramuscular masses with well-defined margins and marked enhancement. Recently it is proved that PET/CT has higher sensitivity than MRI for detecting skeletal muscle metastases.⁷

The treatment depends on the clinical features. Therapeutic options include radiotherapy, chemotherapy, and surgical excision.⁸ In case of painful isolated mass, surgery is the treatment of choice.¹ As our patient had a painless lump so with the valuable opinion of the tumor board, we treated our patients with chemotherapy and confirmed a partial response. We recommend further studies for the prognosis, proper diagnostic and therapeutic strategies for skeletal muscle metastasis in breast cancer.

References

1. Molina-Garrido MJ, Guillén-Ponce C. Muscle metastasis of carcinoma. *Clin Transl Oncol* 2011;13:98-101.
2. Doo SW, Kim WB, Kim BK, Yang WJ, Yoon JH, Song YS et al. Skeletal muscle metastases from urothelial cell carcinoma. *Korean J Urol*. 2012 ; 53:63-6.
3. Ogiya A, Takahashi K, Sato M, Kubo Y, Nishikawa N, Kikutani M, et al. Metastatic breast carcinoma of the abdominal wall muscle: a case report. *Breast Cancer*. 2012 ; 2: 12-13.
4. Niikura N, Liu J, Hayashi N, Mittendorf EA, Gong Y, Palla SL et al. Loss of human epidermal growth factor receptor 2 (HER2) expression in metastatic sites of HER2-overexpressing primary breast tumors. *J Clin Oncol*. 2012 ; 30 : 593-9.

5. Hatori M, Sasano H, Hoshikawa K, Sakuma T, Okaniwa G, Sakurai M. Skeletal muscle metastasis secondary to adenocarcinoma of the lung. *Orthopedics*, 1996;4:145-7.
6. Tuoheti Y, Okada K, Osanai T, Nishida J, Ehara S, Hashimoto M, et al. Skeletal muscle metastases of carcinoma: a clinicopathological study of 12 cases. *Jpn J Clin Oncol*. 2004;34:210-4.
7. Emmering J, Vogel WV, Stokkel MP. Intramuscular metastases on FDG PET-CT: a review of the literature. *Nucl Med Commun*. 2012;33:117-20.
8. Kim YW, Seo1 KJ, Lee SL, Kwon KW, Hur J, An HJ et al. Skeletal Muscle Metastases from Breast Cancer: Two Case Reports; *J Breast Cancer*. 2013; 16(1): 117-21.