

## Case Report

### Pigmented Villonodular Synovitis Treated as Spondyloarthritis for Four Years - A Case Report

\*Islam ME<sup>1</sup>, Hassan MM<sup>2</sup>, Islam MN<sup>3</sup>, Ahmedullah AK<sup>4</sup>, Hasan MN<sup>5</sup>

#### Abstract

*Pigmented villonodular synovitis (PVNS) is a rare disorder where abnormal synovial proliferation and insidious swelling are the characteristic features. As insidious joint swelling has many common causes and PVNS is rare entity, so that it may be missed or under evaluated. Here inconclusive biopsy findings at an early stage and features resembling spondyloarthritis (SpA) delayed the diagnosis. A 28-year-old young man presented with insidious swelling of knee. Here repeated aspiration and synovial fluid analysis with routine serological and radiological examination were inconclusive. Then he was labeled and treated as spondyloarthritis (SpA) for four years without improvement. After four years of sufferings he admitted here and reached the diagnosis of PVNS with the help of MRI and synovial biopsy. Sometimes rare disease diagnosis is complicated by the absence of typical features and inconclusive reports. Common differentials may mimic the diagnosis and rare disease may lose the attention. Here PVNS was treated as SpA for four years before being diagnosed.*

#### INTRODUCTION

Pigmented villonodular synovitis (PVNS) is a proliferative benign disease that involves joints, tendon sheaths<sup>1</sup> and bursae.<sup>2</sup> PVNS can be localized and diffuse type.<sup>3</sup> Jaffe HL, Lichtenstein L, Sutro CJ first reported PVNS in 1941.<sup>2, 4, 5</sup> PVNS looks like frond or leaf, brownish synovial

proliferation with mononuclear stromal cell infiltration, presence of hemosiderin laden macrophages, foam cells and giant cells.<sup>6</sup> Knee<sup>7,8</sup> is the commonest followed by shoulder, hand and hip involvement<sup>9,10</sup> and is usually monoarticular and can be polyarticular.<sup>11</sup> In a study among 20 to 50 years of age, both extra and intra-articular PVNS was found 9.2 and 1.8 per million consecutively.<sup>8</sup> Mean diagnostic delay of PVNS was eighteen months<sup>4</sup> in one study and fifty four months in another study.<sup>12</sup> Here diagnostic delay was four years. Before diagnosing PVNS, JIA, Septic arthritis, bacterial synovitis, rheumatoid arthritis, hemophilia, TB, hemangioma and other causes of hemarthrosis need to be excluded.<sup>12,15</sup>

#### CASE REPORT

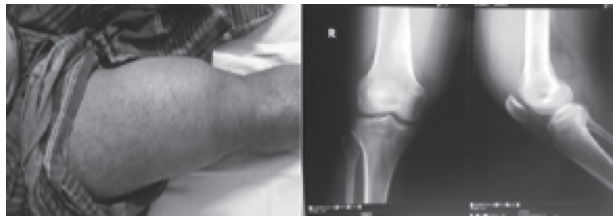A 28-year-old male presented with swelling of right knee joint 4-year back. Insidious swelling with nonspecific mild pain & discomfort was his presenting feature. He did not give any history of trauma, preceding diarrhea or dysentery, family history of psoriasis and did not have any previous and present psoriatic skin and nail changes. The swelling gradually increased and discomfort increased overtime during walking and daily activities. Swelling was diffuse and boggy with normal overlying skin. All other examination findings were normal. Repeated aspiration of reddish synovial fluid was re-accumulate within a few weeks again. Her CBC, ESR, urine R/E, chest X-ray P/A view, X-ray pelvis A/P view, C reactive protein was normal 3.48 (<6mg/l), Anti CCP was 12.8 U/ml (<25 U/l), Synovial fluid analysis was done 4 times before admission but nothing was significant except plenty of RBC. Synovial protein was 41 gm/L, glucose 4.5 mmol/L, Color- red, TC:1000-3500/cu mm, L:80-90%,N:5-10%, plenty of RBC, No AFB, Xpert Gene for MTB was not detected, PCR of MTB was negative, malignant cell was not found. MT (07/01/2017): Negative (02 mm).

Synovial biopsy on August, 2015 showed dense infiltration of acute & chronic inflammatory cells. The synoviocytes were hypertrophic. No granuloma or malignancy is seen. Chronic non-specific arthritis was commented. In Dec' 2016 biopsy report finding was fibro-cartilagenous fatty tissue infiltrated by chronic inflammatory cells including a few hemosiderin laden macrophages and comment was features were consistent with chronic inflammatory tissue.

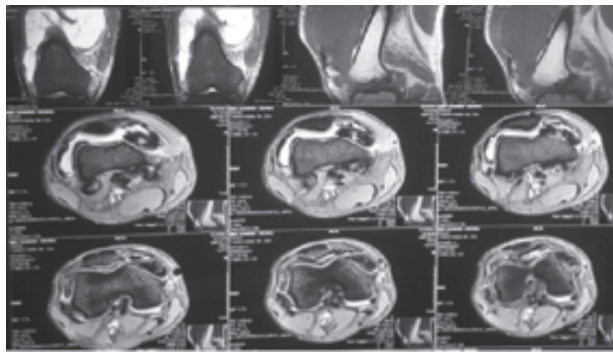
1. \*Dr. Md. Masudul Hassan, department of Rheumatology, Bangabandhu Sheikh Mujib Medical University, Shahbag, Dhaka, Bangladesh. E-mail: masud292@yahoo.com
2. Dr. Md. Ekramul Islam, phase B resident, department of Rheumatology, Bangabandhu Sheikh Mujib Medical University, Shahbag, Dhaka, Bangladesh.
3. Dr. Md. Nazrul Islam, Professor of rheumatology, Department of Rheumatology, Bangabandhu Sheikh Mujib Medical University, Shahbag, Dhaka, Bangladesh.
4. Dr. Abul Khair Ahmedullah, assistant professor, department of Rheumatology, Bangabandhu Sheikh Mujib Medical University, Shahbag, Dhaka, Bangladesh.
5. Dr. Md. Nazmul Hasan, assistant professor, department of Medicine, Bangabandhu Sheikh Mujib Medical University, Shahbag, Dhaka, Bangladesh.

\*For Correspondence

He was also negative for HLAB27 alleles. After exclusion of all possibilities and two episodes of synovial biopsy was done without conclusive remarks. Then he was labeled as spondyloarthritis and treated with NSAIDs, sulfasalazine, intra-articular steroid for two years without significant improvement. He was referred to a tertiary hospital in Bangladesh. Here patient was reevaluated and further drive was given to reach diagnosis. Radiographs of the right knee shows no bony abnormality. Ultrasonography shows synovial hypertrophy and moderate fluid collection but no Doppler activity.



**Fig:1** Picture of right Knee joint and X-Ray of right knee



**Fig:2** MRI of knee joint- Coronal, Sagittal and Axial view

MRI (Fig: 2) reveals- a large loculated joint effusion seen in pre-patellar region, low to Intermediate signal intensity on T1WI & T2WI on the Hoffa's fat pad, posterior to distal femur, medial and posterior aspect of knee joint with some high signal intensity. A multilobulated lesion is seen in continuity with the synovium in the anteromedial, anterolateral, and patello-femoral joint space with few internal septations. Bone erosion involving distal femur was present.

Again synovial biopsy was done and which revealed- The synoviocytes are hypertrophic, infiltration of chronic inflammatory cells and presence of haemosiderin laden macrophages with no granuloma. Multilobulated lesion in antero-medial and antero-lateral aspect of knee joint with loculated effusion- suggestive of Pigmented villonodular synovitis.

## DISCUSSION

Clinical feature may not be typical and varies a great extent and it depends whether the lesion is intra or extra-articular. Extra-articular PVNS generally presents as a mass of soft-tissue (83%-99%) may have pain (22%-71%). Here pain was mild and discomfort was complained. Joint dysfunction and swelling reported rarely (0%-4%).<sup>16</sup> Intra-articular type of PVNS usually have pain and swelling with limitation of movement<sup>11</sup>, joint dysfunction is less (26%-28% cases) and soft tissue mass found in 6%-19% of cases.<sup>16</sup>

The duration of symptoms varies widely from 1 to 120 months with an average of 2-3 years before presentation. Here it took four year to reach diagnosis. Laboratory findings including blood count and sedimentation rate are normal like this case.<sup>11</sup>

In synovial biopsy from PVNS there is synovial cell proliferation, hemosiderin laden macrophages, xanthomatous cell accumulation. The mechanism of bone erosion in PVNS is somewhat unclear. It was believed that erosion results from raised intra-articular pressure while some believe that the synovium releases substances causes erosion and progress to destruction.<sup>17</sup>

The appearances of PVNS on MR imaging are often characteristic, with low to intermediate signal intensity in all pulse sequences due to hemosiderin deposition. Other features of may include synovial proliferation, joint effusion and bone erosion. The combination of hemosiderin deposits, villonodular soft tissue masses and/or multiple bone erosion is highly diagnostic for PVNS. The deposit of hemosiderin, appearing as a low signal area best seen on FFE sequence, is diagnostic for PVNS.<sup>18</sup>

For both localized and diffuse PVNS surgical excision is the treatment of choice. Outcome depends on complete resection with clear margins. For diffuse PVNS, open surgical excision is the primary method. Another method is arthroscopic synovectomy but has reported recurrence rate is as high as 46%.<sup>19</sup> Totalsynovectomy is difficult to perform and the neurovascular structures adjacent to the affected synovium may be injured. One report suggests that total synovectomy seems to be effective in preventing recurrence but osteoarthritis risk is increased, so subtotal synovectomy is preferred than total synovectomy.<sup>20</sup> PVNS has been reported to have a high recurrence rate (14-56%). It rarely in becomes malignant.<sup>19</sup> To prevent recurrence, radiation therapy to a dose of 35 to 50 Gy has been effective. Radiotherapy is particularly useful in patients with mitotic

figures or incomplete excision.<sup>20</sup> Kotwal et al reported no recurrence after post-operative radiotherapy in comparison to 6% recurrence.

## CONCLUSIONS

PVNS is a rare and benign but recurrence is the problem. Diagnosis can be delayed. Hemarthrosis may be the first clue and histopathologist and clinician may exchange views to give attention for rare conditions like PVNS. So that sufferings may be minimized.

## REFERENCES

1. Byers PD, Cotton RE, Deacon OW, Lowy M, Newman PH, Sissons HA, Thomson AD. The diagnosis and treatment of pigmented villonodular synovitis. *The Journal of Bone and Joint Surgery* 1968; May Vol. 50 B: no 2
2. Jaffe HL, Lichtenstein L, Sutro CJ. Pigmented villonodular synovitis, bursitis and tenosynovitis. *Arch Pathol* 1941;31:731-765
3. Lucas DR. Tenosynovial giant cell tumor: case report and review. *Arch Pathol Lab Med.* 2012; 136(8):901-6
4. Xie G, Jiang N, Liang C, et al. Pigmented Villonodular Synovitis: A Retrospective Multicenter Study of 237 Cases. *Assassi S, ed. PLoS ONE.* 2015; 10(3):e0121451. doi:10.1371/journal.pone.0121451
5. Lee MK, Choong PF, Smith PJ, Powell GJ, Slavin JL, Schlicht SM. Pigmented villonodular synovitis of the hip mimicking soft-tissue sarcoma: a case report. *J Orthop Surg (Hong Kong)* 2006; 14 (1): 76-80
6. Frassica FJ, Bhimani MA, McCarthy EF, Wenz J. Pigmented villonodular synovitis of the hip and knee. *Am Fam Physician.* 1999; Oct 1; 60 (5): 1404-10; discussion 1415
7. Miller WE: Villonodular synovitis: pigmented and nonpigmented variations. *South Med J.* 1982; 75:1084-1086
8. Myers BW, Masi AT. Pigmented villonodular synovitis and tenosynovitis: a clinical epidemiologic study of 166 cases and literature review. *Medicine (Baltimore).* 1980 May. 59(3):223-38
9. Muller LP, Bitzer M, Degreif J, Rommens PM. Pigmented villonodular synovitis of the shoulder: review and case report. *Knee Surg Sports TraumatolArthrosc* 1999; 7:249.
10. Mankin H, Trahan C, Hornicek F. Pigmented villonodular synovitis of joints. *J SurgOncol* 2011; 103:386

11. Dorwart RH, Genant HK, Johnston WH: Pigmented villonodular synovitis of synovial joints: clinical, pathologic and radiological features. *AJR AM J Roentgenol.* 1984; 143:877-885.
12. Ma, X., Shi, G., Xia, C. et al. *International Orthopaedics (SICOT)* (2013) 37: 1165. doi:10.1007/s00264-013-1858-9
13. Neubauer P, Weber AK, Miller NH, McCarthy EF. Pigmented villonodular synovitis in children: a report of six cases and review of the literature. *The Iowa orthopaedic journal.* 2007; 27:90-94
14. Costallat B, Montagner S, Amstalden E, Ferreira D, Zoppi A, Costallat L. A case of villonodular synovitis of the shoulder in an adolescent: imaging and pathologic diagnosis. *Rev Bras Reumatol.* 2009; 49 (1): 70-80
15. Raman RB, Singh R, Choudhary V, et al. Pigmented villonodular synovitis of the knee joint: a case report. *J. Evolution Med. Dent. Sci.* 2016; 5(72):5329-5330, DOI: 10.14260/jemds/2016/1208
16. Bassetti E, Candreva R, Santucci E: pigmented villonodular synovitis of the knee: A case report. *J ultrasound.* 2011 sep; 14(3): 167-169
17. Bhimani MA, Wenj JF, Frassica FJ. Pigmented villonodular synovitis, keys to early diagnosis. *ClinOrthopRelat Res.* 2001; 386:197-202
18. Cheng XG, You YH, Liu W, Zhao T, Qu H. MRI features of pigmented villonodular synovitis (PVNS). *Clin Rheumatol* 2004; 23:31-4
19. Chin KR, Brick GW. Extra-articular pigmented villonodular synovitis: a cause for failed knee arthroscopy. *ClinRheumatolRelat Res.* 2002; 404:330-338
20. Vastel L, Lambert P, De pinieux G. Surgical treatment of pigmented villonodular synovitis of the hip. *J Bone Joint surg Am.* 2005; 87:1019-1024