

**Original Article****Role of CT in the Evaluation of Nasopharyngeal Angiofibroma in Para Nasal Sinus**T Islam<sup>1</sup>, M Rahman<sup>2</sup>, S Nabi<sup>3</sup>, L Khondker<sup>4</sup>, S Sultana<sup>5</sup>**Abstract:**

Computed tomography (CT) is the gold standard for exact delineation of paranasal sinus (PNS) disease. There are many radiologically important diseases of paranasal sinuses. Objective of the study was to evaluate the role of computed tomographic image (CT) in the diagnosis of nasopharyngeal angiofibroma. A cross sectional study was carried out in the department of Radiology & Imaging, Bangabandhu Sheikh Mujib Medical University (BSMMU), Dhaka in collaboration with department of Otolaryngology and department of Pathology of BSMMU. This study was carried out with patients having suspected PNS mass and the duration of the study was from January 2009 to October 2010. Maximum 30.3% patients were belonged to 46 to 60 years age group and of them maximum 73.7% had complaints of nasal obstruction. Maximum 53.9% patients had PNS mass in maxillary sinuses and out of all cases 8 were diagnosed as having nasopharyngeal angiofibroma by CT scan and confirmed by histopathological evaluation. Two cases were diagnosed as having nasopharyngeal angiofibroma by CT scan but not confirmed by histopathological findings. By CT evaluation total 66 cases were diagnosed as having other than nasopharyngeal angiofibroma and confirmed by histopathology. Sensitivity of CT scan to diagnose nasopharyngeal angiofibroma was 100.0%, specificity 97.1 %, positive predictive value 80.0%, negative predictive value 100.0% and accuracy 97.4%. In conclusion, CT scan of the nasopharyngeal angiofibroma in para nasal sinus provides more information and better image quality and CT diagnosis correlate well with the findings of histopathology.

**Key words:** CT evaluation of nasopharyngeal angiofibroma, histopathology of nasopharyngeal angiofibroma.

1. Dr Tahmina Islam, OSD, DGHS, Mohakhali, Dhaka.
2. Dr. Mizanur Rahman, Assistant Professor, Department of Radiology & Imaging, Dhaka Medical College Hospital, Dhaka.
3. Dr. Shahryar Nabi, Assistant Professor, Department of Radiology & Imaging, Dhaka Medical College Hospital, Dhaka.
4. Dr. Lubna Khondker, Assistant Professor, Dept of Dermatology and Venereology (BSMMU) Shahbag, Dhaka.
5. Dr. Sohely Sultana, Specialist in Radiology and Imaging Square Hospital, Panthopath, Dhaka.

**Corresponding Author:**

Dr Tahmina Islam  
75/1 Shangshad View Apartment (B 4), Indira Road

**Introduction:**

There are many radiologically important diseases of paranasal sinuses.<sup>1</sup> The diagnosis of sinus neoplasia remains a clinical problem for most physicians treating large numbers of patients with sinus complaints.<sup>2</sup> CT (computed tomography) play complementary roles in the evaluation of sinus neoplasia. CT continues to play a key role in the evaluation of the bony changes accompanying the tumor and in helping to determine the surgical approach to the tumor in paranasal sinus region.<sup>3</sup> The radiologic examination is considered sometimes a complementary or supplementary diagnostic procedure to the clinical findings.<sup>4</sup> CT scanning has the ability to obtain thin-slice, high-resolution sectional images. CT scanning provides three-dimensional information, whereas conventional radiography produces two-dimensional images.<sup>5</sup> CT scan is an imaging modality of choice for evaluation of a mass in paranasal sinus. Recent advances in imaging techniques have made it possible to detect various mass in paranasal sinus with the aid of computed tomography (CT) and magnetic resonance (MR) imaging.<sup>6</sup>

One of the most important benign tumors of the sinonasal structures although by no means the most common benign tumor in this region is the juvenile angiofibroma or nasopharyngeal angiofibroma. This is a highly vascular and nonencapsulated polypoid mass that is histologically benign but highly aggressive. It occurs almost exclusively in males in the second decade of life, who present with nasal obstruction and severe epistaxis as well as facial deformity and proptosis. The site of origin is thought to be the nasopharyngeal region at the pterygopalatine fossa or sphenopalatine foramen. Involvement of the pterygopalatine fossa is seen in approximately 90% of patients as asymmetry in the size or widening of this structure and an absence of the normal flat plane between the pterygoid plates and the back of the maxillary sinus. The tumor may extend anteriorly and superiorly into the maxillary and ethmoid sinuses or superiorly into the cranial fossa. There is also the possibility of extension superiorly through the inferior orbital fissure into the orbit and then through the superior orbital fissure into the brain. Because of the extreme vascularity of the tumor and propensity for profuse hemorrhage, the imaging physician must recognize this entity when it occurs and should strongly discourage biopsy. Contrast-enhanced CT reveals a polypoid and infiltrating enhancing mass that involves the nasopharynx and pterygo-palatine fissures and extends anteriorly into the nasal cavity, maxillary sinuses, and

ethmoid sinuses. Again, the orbits and cavernous sinuses may be involved. The treatment of choice is surgical resection. The role of radiation therapy is not clear, although control of tumor growth has been reported. The use of estrogen therapy is also recommended. Many of these tumors begin to involute toward the end of puberty, and the goal of therapy is to minimize facial deformity and bone destruction and to minimize the need for transfusions and the occurrence of fatal epistaxis until the tumor begins to involute and fibrose as part of its natural history. There is no premalignant potential.<sup>7</sup>

This study will help our people to save their hard earnings as well as policy maker to take proper action in case of the patients of PNS mass. Present study was designed to evaluate the diagnosis of nasopharyngeal angiofibroma in paranasal sinus(PNS) by CT(computed tomographic image) and findings of this modality were compared with histopathological result.

**Materials and Methods:**

A cross sectional study was carried out in the department of Radiology & Imaging, Bangabandhu Sheikh Mujib Medical University(BSMMU), Dhaka in collaboration with department of Otolaryngology and department of Pathology of BSMMU. This study was carried out with patients having suspected PNS mass who were attended in the department of Otolaryngology and department of Radiology & Imaging. The duration of the study was from January 2009 to October 2010 and samples were selected purposively among the patients. Inclusion criterias were -patients with PNS mass evaluated clinically and patients with PNS mass evaluated by PNS radiograph. Exclusion criterias were patients refusing to do CT scan and patients who were unwilling to do histopathology. A pre-tested questionnaire were used as research instruments. Statistical analysis of the results were presented in tables and figures. For the validity of study outcome, sensitivity, specificity, accuracy, positive predictive value and negative predictive value of CT scan in the diagnosis of nasopharyngeal angiofibroma in para nasal sinus(PNS)were calculated.

**Scanning technique of CT scan and Histopathological correlation**

All patients were undergone CT examination of PNS at the department of Radiology and Imaging, BSMMU, Dhaka. All CT scan was performed with a third generation CT, Hitachi W2000 (3-5) mm thick contiguous slice was taken. These scans were obtained using 120 kv, 150 mA, 7.5 mm collimation and 1 sec scanning time for 1 slice. Both pre and post contrast scan was performed. 50 ml of non ionic water soluble iodinated contrast medium of 370 strength was administered. Immediately after completion of bolus injection 3-5 mm contiguous slice was obtained. The postoperative resected tissues were examined histopathologically in the department of pathology, BSMMU and then the collected reports were correlated with findings of CT.

**Result :**

Figure I showed the age distribution of the patients. Maximum 30.3% patients were belonged to 46 to 60 years age group followed by 26.3% within 16- 30 years, 17.1% more than 60 years, 15.8% within 31 to 45 years and 10.5% up to 15 years. Mean (SD) age of the patients was 35.95 (± 18.24) and all patients were belonged from 4 years to 70 years. Table I showed the different clinical presentations of patients having PNS mass. Of them maximum 73.7% had complaints of nasal obstruction, followed by 47.4% had breathing difficulties, 39.5% had headache, 21.1% had epistaxis, 11.8% had eyeache, 10.5% had proptosis and 9.2% had puffiness of their face. Table II showed the frequency distribution of the PNS mass at different locations. Maximum 53.9% patients had PNS mass in maxillary sinuses followed by 17.1% in nasal cavity, 14.5% in ethmoid sinuses, 10.5% in sphenoid sinuses and rest 6.6% in frontal sinuses. Figure II showed the CT diagnosis of PNS masses. Out of 76 cases 31.6% had polyp, 21.1% had malignant mass, 15.8% had fungal infection/mass, 13.2% had nasopharyngeal angiofibroma, and 18.4% had retention cyst. Figure III showed the histopathological diagnosis of PNS masses. Out of 76 cases 31.6 % had inflammatory polyp, 19.7% had malignant mass, 21.1% had fungal infection, 10.5% had nasopharyngeal angiofibroma, and 17.1% had benign cyst. Out of all cases 8 were diagnosed as having nasopharyngeal angiofibroma by CT scan and confirmed by histopathological evaluation. Two cases were diagnosed as having nasopharyngeal angiofibroma by CT scan but not confirmed by histopathological findings. By CT evaluation total 66 cases were diagnosed as having other than nasopharyngeal angiofibroma and confirmed by histopathology. They were true negative. Sensitivity of CT scan to diagnose nasopharyngeal angiofibroma was 100.0%, specificity 97.1 %, positive predictive value 80.0%, negative predictive value 100.0% and accuracy 97.4%.

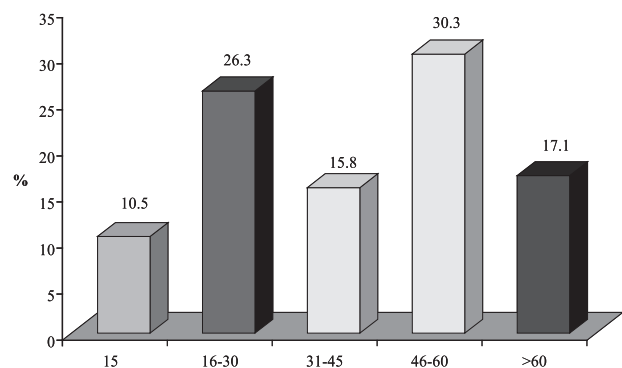


Figure I: Bar diagram of the patients by age

**Table I: Distribution of patients by clinical presentation (n=76)**

Clinical presentation	Frequency	Percent
Nasal obstruction	56	73.7
Breathing difficulty	36	47.4
Headache	30	39.5
Epistaxis	16	21.1
Eyeache	9	11.8
Proptosis	8	10.5
Gadual swelling of face	7	9.2

**Table II: Distribution of location of the lesion of PNS (n=76)**

Location of the lesion	Frequency	Percent
Maxillary sinuses	41	53.9
Nasal cavity	13	17.1
Ethmoid sinuses	11	14.5
Sphenoid sinuses	8	10.5
Frontal sinuses	5	6.

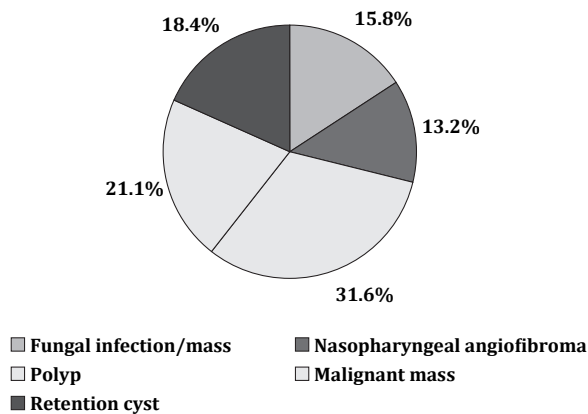


Figure II: CT diagnosis of PNS masses

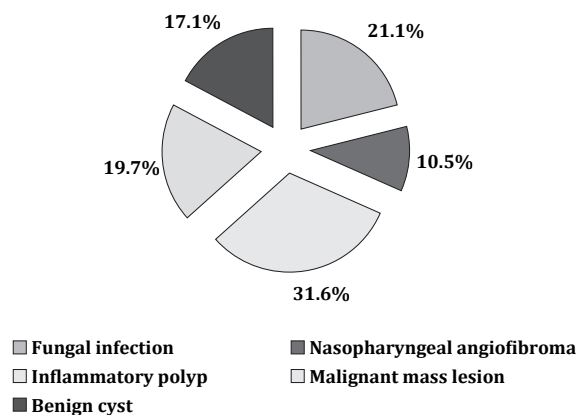


Figure III: Histopathological diagnosis of PNS masses

**Table III: Distribution of nasopharyngeal angiofibroma in PNS by CT scan and histopathological diagnosis**

CT diagnosis	Histopathological diagnosis		Total
	Nasopharyngeal angiofibroma	Other	
angiofibroma	8	2	10
Others	0	66	66
Total	8	68	76

**Table IV: Sensitivity, specificity, accuracy, positive and negative predictive values of the CT scan in the diagnosis of nasopharyngeal angiofibroma**

Validity test	Percentage	95% CI
Sensitivity	100.0	74.5 -100.0
Specificity	97.1	94.1 -97.1
PPV	80.0	59.6 -80.0
NPV	100.0	96.9 -100.0
Accuracy	97.4	92.0 -97.4

**Discussion:**

This cross sectional study was conducted with total 76 patients. Mean (SD) age of these patients was 35.95 (± 18.24) and maximum 30.3% patients were belonged to 46 to 60 years age group. In a previous study done by Rupa et al, similar age group was evaluated. Mean age of their patients was 29.39 years and maximum patients were within 10-19 year age group.<sup>8</sup> In study by Swamy and Gowda study age incidence for various benign tumours of nose and paranasal sinuses varied from 9 months to 60 years and commonest age group was 11 to 20 years (36.66%).<sup>9</sup> Nasal obstruction (73.7%), breathing difficulties (47.4%), headache (39.5%), epistaxis (21.1%), eyeache (11.8%), proptosis (10.5%) and puffiness face (9.2%) were the commonest presenting symptoms of the patients of present study. In study by Swamy and Gowda, nasal obstruction (76.66%), epistaxis (53%), and nasal discharge (50.0%) were the commonest symptoms followed by mass, headach, hyposmia and nasal twang of speech.<sup>9</sup>

In the present study CT scan evaluated the patients with provisionally diagnosed PNS masses. Out of 76 cases 31.6% had polyp, 21.1% had malignant mass, 15.8% had fungal infection/mass, 13.2% had nasopharyngeal angiofibroma, and 18.4% had retention cyst. After radiological diagnosis, all of these patients underwent surgical procedure and histopathological dignosis and finally 31.6 % patients were diagnosed as having inflammatory polyp, 19.7% malignant mass, 21.1% fungal infection, 10.5% nasopharyngeal angiofibroma, and 17.1% benign cyst. In Rupa series out of 33 patients 33.0% had sinonasal polyp, 9% fungal infection, 24.24% angiofibroma, 3% heamangioma and 27.27% malignant mass. These findings were evaluated by CT scan. After histopathology 30.3% patients were diagnosed as polyp, 12.12% fungal infection, 21.21% malignant mass, 27.27% angiofibroma, 6% haemangioma and 3% meningioma.<sup>8</sup>

Sensitivity of CT scan to diagnose nasopharyngeal angiofibroma was 100.0%, specificity 97.1 %, positive predictive value 80.0%, negative predictive value 100.0% and accuracy 97.4%. Similar observation was also made by Cagici et al. In their study sensitivity and specificity of three-slice CT for identifying inflammatory sinus disease were 95.1% and 92.6%, respectively.<sup>10</sup>

A review of 23 consecutive patients with tumors of the nasopharynx and maxillary sinus seen by Abayomi and Bankoff over a two-year period was carried out. The purpose was to assess the value of computerized tomography (CT) in the definition of tumor extension to contiguous structures and its effect on treatment selection and management. CT was found to be very useful in detailing bone and soft-tissue invasion. In 11 of 15 patients with nasopharyngeal cancer and in the eight patients with maxillary sinus tumors, the selection of treatment and the techniques of irradiation were influenced by the CT findings. There is a high degree of accuracy in the evaluation of the nasopharynx and maxillary sinus by CT. This improvement in pretreatment assessment of the tumors enables adequate treatment to be offered. Since most of the failures of treatment are a result of local recurrence, improvement in local control is likely to result in improved survival.<sup>2</sup>

#### Conclusion:

In conclusion, CT scan of the nasopharyngeal angiofibroma in para nasal sinus provides more information and better image quality and CT diagnosis correlate well with the findings of histopathology.

1. Zinreich JS, Kennedy DW, Rosenbaum AE, Gayler BW, Kumar AJ, Stammberger H. Paranasal sinuses: CT imaging requirements for endoscopic surgery. *Radiology* 2007;163: 769-75.
2. Abayomi OK, Bankoff MS. Computerized tomographic evaluation of tumors of the nasopharynx and maxillary sinus: potential impact on results of treatment. *Journal of the National Medical Association* 2006;78(4): 311-16.
3. Bhattacharyya N, Fried MP. The accuracy of computed tomography in the diagnosis of chronic rhinosinusitis. *Laryngoscope* 2003;113(1): 125-29.
4. Reider-Grosswasser I, Solomon A, Zikk D, Godel V. Computerized tomography in conditions concomitantly involving the orbits and the paranasal sinuses. *Computerized Radiology* 2006;10(2-3): 119-126.
5. Som PM, Shapiro MD, Biller HF, et al. Sinonasal tumors and inflammatory tissues: Differentiation with MR. *Radiology* 2008;167: 803-808.
6. Duncavage JA, Campbell BH, Hanson Gil. Diagnosis of malignant lymphomas of the nasal cavity, paranasal sinuses and nasopharynx. *Laryngoscope* 2003;93:1276.
7. Som PM, Cohen BA, Sacher M. et al. The angiomalous polyp and the angiofibroma: Two different lesions. *Radiology* 2002; 144: 324.
8. Rupa LT, Zimmerman RA. Computed tomography in evaluation of the paranasal sinuses. *Radiol Clin North Am* 2002;20: 51-66.
9. Swamy KV, Gowda BVC. A clinical study of benign tumours of nose and paranasal sinuses. *Indiana Journal of Otolaryngology and Head and Neck Surgery* 2004;56(4).
10. Cagici CA, Cakmak O, Hurcan C, Tercan F. Three-slice computerized tomography for the diagnosis and follow-up of rhinosinusitis. *European Archives of Oto-Rhino-Laryngology* 2005;262(9):