

## Case Report

### A case of congenital maldisposition of pelvic peritoneum & chronic retention of urine at term pregnancy

Banu N<sup>1</sup>, Ferdous J<sup>2</sup>

#### Abstract

Mal disposition of peritoneum over abdominal organs were reported both in cadaver & in diseased persons; but no report was found particularly about mal disposition of pelvic peritoneum. We are sharing our experience of a rare cause of chronic urinary retention due to abnormal disposition of pelvic peritoneum, diagnosed incidentally during lower segment caesarian section. A 23 years young lady admitted at her term pregnancy as a case of prolong labour with failure of descend of fetal head. A healthy female baby was delivered by ower segment caesarian section. But the procedure was not so smooth, though she had no risk factors for adhesive disease or past abdominal surgery. The bladder was hugely distended & atonic without any sign of obstructed labour. The peritoneal reflection was near fundus of the uterus; that's why the bladder was pulled up along with the growing uterus. On further inquiry, she gave the history of incomplete voiding from her 28th weeks of pregnancy. The peritoneum over other pelvic organs was also found loosely attached. The abnormal disposition of peritoneum over bladder & uterus is absolutely benign congenital malformation; but the condition is not free from complication.

**Key words:** Chronic urinary retention, maldisposition, pelvic peritoneum

#### Introduction

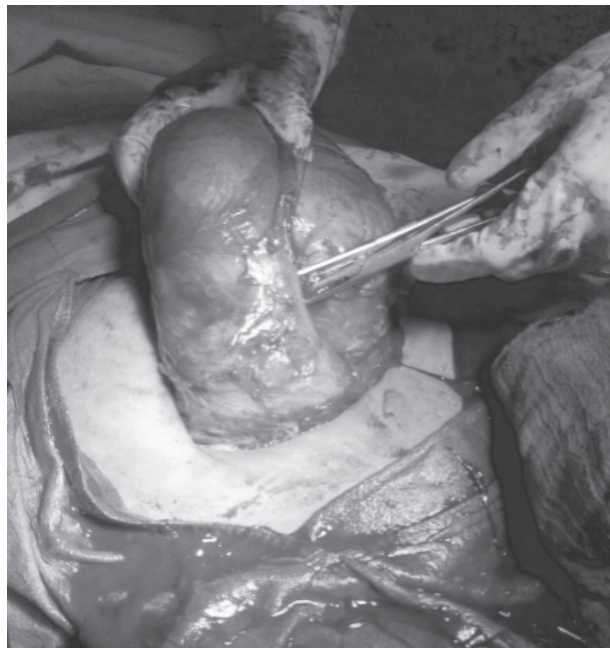The peritoneum is one of the important & complex serous membrane. It encases the peritoneal cavity, composes mesenteries, and covers the abdominal & pelvic organs partly or completely. The anatomic compartmentalization of the peritoneum by the attachments of the mesenteries dictates the distribution & free movements or enlargement (when necessary) of the abdominal organs.

The complexity of embryonic development of abdominal organs & mesenteries provides a platform for formation of a wide variety of variant veils, folds & membranes,

collectively termed peritoneal bands.<sup>1</sup> The aberration in peritoneal distribution has the potentiality to cause clinically significant manifestations both in neonate and in adult. Clinical manifestations are highly variable as a result of diverse location of these variant structures.

#### Case report

Mrs. Chhobee, 23 years old, primi gravid woman admitted at her term pregnancy as a case of prolong labour with failure of descend of fetal head. Lower segment caesarian section was done and a healthy female baby was delivered with good Apgar score. But the procedure was not so smooth though she had no risk factors for adhesive disease or past abdominal surgery. Abdomen had to open just beneath the umbilicus through a small window due to bladder distension. The bladder was hugely distended and atonic in spite of continuous drainage and absence of obstruction (Figure-1).



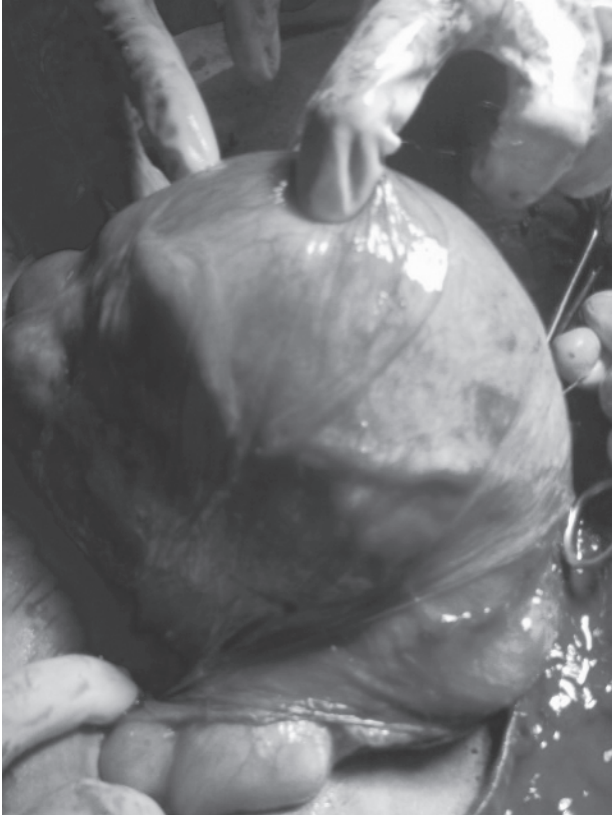**Figure-1:** Loose utero-vesical fold of peritoneum, obscuring the caesarean incision margin

The loosely attached uterovesical fold of peritoneum was near fundus, forming a hood like structure with its bilateral extension.

The broad ligaments could not be identified as lateral wings, rather found on posterior surface of uterus with its contents. The openings of the tubes were found antero-laterally (Figure-2).

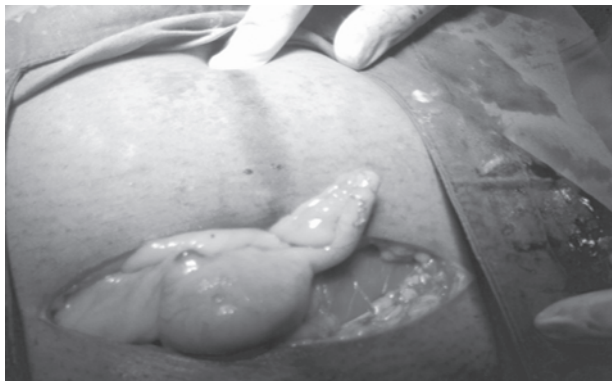
1. \* Dr Nasreen Banu, Assistant Professor of Gynecology & Obstetrics, Chittagong Medical College, Chittagong, Bangladesh. Email: drnasreenb@yahoo.com
2. Dr Jannatul Ferdouse, Assistant Professor of Gynecology & Obstetrics, Chittagong Medical College, Chittagong, Bangladesh

\*For correspondence



**Figure-2:** Hugely distended bladder with the fallopian tubes on posterior aspect of uterus

Due to too loose peritoneal reflection at utero-vesical fold the bladder was pulling up along with the enlarging uterus throughout pregnancy. For the same reason the broad ligaments were filled up with enlarged uterus and hence the tubes with ovaries were found on posterior aspect of uterine body. The sigmoid mesocolon was loosely attached up to left para colic gutter and rectum was hanging from posterior surface of cervix with loose peritoneum (instead of attachment on posterior aspect of vagina). The caecum and appendix were protruded out through incision margin of abdominal wall while lower segment caesarian section was completed (Figure-3).



**Figure-3:** Protrusion of caecum with appendix through the abdominal wound of caesarian section

The Pouch of Doglus was not a deep pouch rather full of loose peritoneal folds of adjacent organs. The peritoneal disposition over rest of the abdominal organs could not be discovered due to in appropriate exposure (through lower transverse incision). On further inquiry she gave the history of incomplete voiding around her 28th weeks of pregnancy till the onset of labour pain.

Her post operative recovery was smooth. She was managed with catheter in situ throughout her involution period (6 weeks) so that, the bladder could be a pelvic organ along with the original size of uterus & could regain its tonicity.

She had no more urinary complaints after removal of her catheter and was re-evaluated with Ultrasonogram (USG) to see post voided urine volume which was absolutely normal.

### Discussion

Normally the peritoneal distribution is such that the particular organ remains in particular place for their free movement and enlargement when necessary.

The anatomically unabsorbed portions of omentum and mesentery although often benign, have the potentiality to cause clinically significant manifestations. These deviant structures may be identified over a broad range of abdominal cavity; mostly in the regions of duodenum, duodenojejunal flexure, ileocecal junction and ascending colon. Diverse locations of these variant structures produce diverse clinical presentations; ranging from acute intestinal necrosis to chronic abdominal pain.<sup>1</sup> Lickly and Cameron reported an abnormal peritoneal disposition, where the small gut enveloped in a peritoneal sac distinct from general cavity. They discovered this aberrant disposition of peritoneum during dissection of a cadaver.<sup>2</sup> Small gut was concealed from view on a cadaveric dissection described by Cleland, which was being lodged with in a secondary sac.<sup>3</sup> The small gut was encased in an accessory peritoneal sac between omentum and mesocolon reported by Narayan et al<sup>4</sup>. A case of persistence of a peritoneal band extending from gall bladder to the right colic flexure was seen by Mehta et al.<sup>5</sup> Internal hernia related to abnormal peritoneal fibrous bands (of Ladd) that attached to the right colon was another complication seen in adults.<sup>6</sup> Al-Ta'an OS et al reported peritoneum encasing small bowel to form an accessory peritoneal sac which was an incidental diagnosis.<sup>7</sup>

So far, the upper abnormal mal-dispositions of peritoneum were reported both in diseased persons and in cadavers. But no one reported about pelvic peritoneal malposition. Many surgeons may face such abnormal situation and we are reporting this symptomatic abnormal pelvic peritoneal disposition.

**References**

1. Oelhafen K, Shavota BJ, Muhleman M, Klaassen Z, Shola MM, Tubbs RS et al. Peritonal bands: a review of anatomical distribution & clinical implications. *Am Surg* apr 2012; 78(4): 377-384.
2. Lickley JD, Cameron J. Note on a abnormal disposition of the peritoneum. *J Anat Physiol*. Oct 1906; 41(pt 1): 88- 90.
3. Cleland. On an abnormal arrangement of the peritoneum with remarks on the development of the mesocolon. *J Anat Physiol*. 1868; 2(2): 201-206.
4. Narayanshing V, Maharaj D, Singh M, Ramdass MJ. Peritoneal encapsulation: a preoperative diagnosis is possible. *Postgrad Med J*. Nov 2001; 77 (913): 725-726.
5. Mehta V, Arora J, Suri RK, Kumar H, Gupta V, Rath G et al. Clinical relevance of a cystocolic peritoneal band found incidentally during cadaveric dissection. *Clin Ter* 2010; 161(2): 153-154.
6. Pickhardt PJ, Sanjeev B. intestinal malrotation in adolescents & adults: spectrum of clinical & imaging features. *AJR* Dec 2002; 179(6): 1429-1435.
7. Al-Taan OS, Evans MD, Shami JA. An asymptomatic case of peritoneal encapsulation: case report & review of the literature. Available from: [www.casesjournal.com/content/3/1/13](http://www.casesjournal.com/content/3/1/13).