

Case Report

Bilateral simultaneous central retinal vein occlusion secondary to trauma

Debnath PR¹, Bhowmik NC², Debnath DK³, Sarker SK⁴

Abstract

Retinal vein occlusion refers to the closure of the central retinal vein that drains the retina or to that of one of its branches. Central retinal vein occlusion (CRVO) is caused by age related changes in the retinal vessels. Bilateral CRVO is a relatively rare event. Only less than 10% cases are bilateral, simultaneous bilateral CRVO is very rare. We are presenting a case report regarding a middle aged patient with history of trauma who presented with bilateral CRVO in the department of ophthalmology, BIRDEM General Hospital, Dhaka. After detailed clinical work up and investigation a diagnosis of bilateral CRVO secondary to trauma was made.

Key words: Central retinal vein occlusion, loss of vision, retinal hemorrhages

Introduction

Central retinal vein occlusion (CRVO) is a painless loss of vision that can be caused by a swollen optic disc - the small area in the retina where the optic nerve enters the eye, by dilated retinal veins, and by retinal hemorrhages. CRVO is also called venous stasis retinopathy, or hemorrhagic retinopathy. CRVO is a common cause of sudden unilateral loss of vision in elderly. It is usually a unilateral phenomenon presenting in more than 90% of case as unilateral sudden loss of vision, only in less than 10% of case it present as bilateral disease and simultaneous presentation is even more rare.¹ Common risk factors include systemic diseases like age related atherosclerosis, hypertension, Diabetes mellitus, hyperlipidaemia, blood dyscrasias, clotting disorders and autoimmune disorders. Local factors like raised intra cranial pressure, vasculitis of retinal vein, closed-head

trauma, primary open-angle glaucoma or angle-closure glaucoma and congenital anomaly of retinal vein. Clinically it presents in two forms ie non ischemic and ischemic. The non ischemic eye carries good prognosis and ischemic eye carries poor prognosis.^{1,2}

Case report

A 45 years old male presented with sudden blurring of vision of both eye as out patient in department of ophthalmology, BIRDEM General Hospital. He is diabetic. Patient was admitted at DMCH with head injury and treated by neurosurgeons. For his blurring of vision he reported at eye OPD, BIRDEM There were no relevant past ophthalmic history.

On clinical examination his best corrected visual acuity was CF -2ft in right eye and 6/60 in left eye. Intra ocular pressure was 15 mm of Hg in both eyes. Both pupils were equally reactive with no afferent pupillary defect. Media were clear. On systemic examination blood pressure reading was 120/80 mm of Hg.

Laboratory investigations including CBC, RBS, Lipid profile, serum creatinine and activated partial prothromboplastin time were done and found to be normal.

Fundoscopy revealed bilateral extensive scattered deep blot and flame-shaped hemorrhage involving all four quadrants with dilated veins. Optic discs were oedematous and hyperaemic. Cotton wool spots were observed. (Figure - 1)

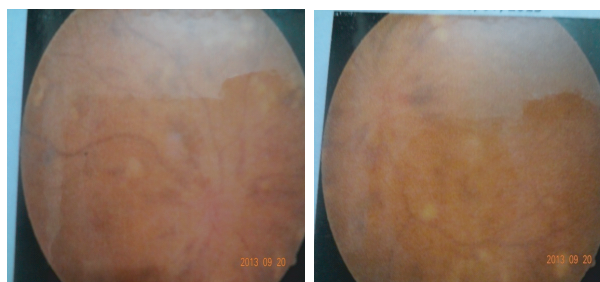


Figure -1: Fundoscopy of right and left eye

Fundus fluorescein angiography demonstrated delayed venous filling in each eye, blockade by haemorrhage and good retinal capillary perfusion. (Figure -2)

1. *Dr Purabi Rani Debnath, Associate Professor
Department of Ophthalmology, BIRDEM General Hospital, Dhaka.
2. Dr Narayon Chandra Bhowmik, Medical officer,
Department of Ophthalmology, BIRDEM General Hospital, Dhaka.
3. Dr Dilip Kumar Debnath, Assistant Professor,
Department of Ophthalmology, Dhaka Medical College Hospital, Dhaka
4. Dr Sujit Kumar Sarker, MS (Thesis) Student,
Department of Ophthalmology, BIRDEM General Hospital, Dhaka.

*For correspondence

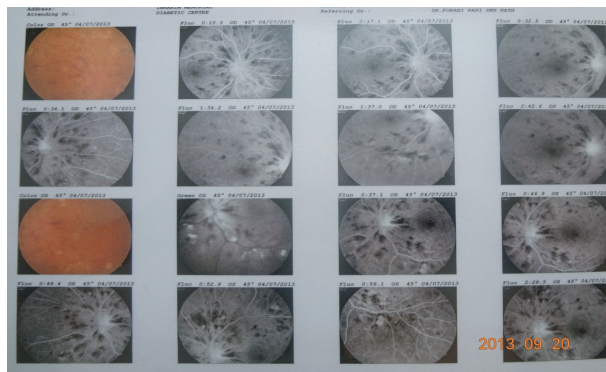


Figure - 2: Fundus fluorescein angiography (FFA) of right and left eye

Optical coherence tomography (OCT) Showed increase retinal thickness due to macular edema in both eyes (Figure -3)

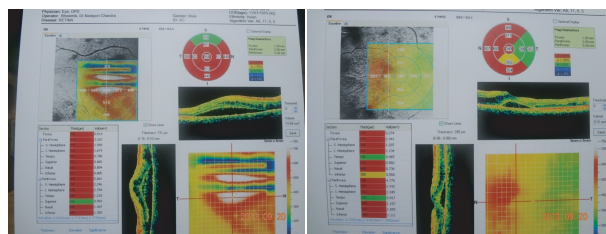


Figure - 3: OCT of left & right eye

Discussion

Central retinal vein occlusion is the most common retinal vascular disease only after diabetic retinopathy. Occlusion of central retinal vein is often a result of local or systemic causes. Local causes such as primary open angle or closed angle glaucoma were ruled out in our patient.

The systemic diseases which may cause central retinal vein occlusion are

- Atherosclerosis and other systemic diseases like hypertension
- Conditions associated with elevated central venous pressure like pulmonary hypertension
- Hypercoagulability states and
- Collagen vascular diseases and vasculitis

Patient was thoroughly investigated for systemic diseases and trauma was the only positive finding. In the central retinal venous occlusion study (August 1988 to July 1992) a total of 725 with years were enrolled, only three cases were bilateral (0.41%).¹ However in a 17 years study Hayrchi et al (1973 to 1990) which included all forms of vascular occlusions, there were 515 patients of CRVO, of whom 88 were bilateral (7.38%).² Fani et al presented a case of bilateral central retinal vein occlusion in a colonic

cancer patient in 2001.³ Balogh Z, Berta A and associates presented a case report in 2011 regarding a young patient. Patient was thoroughly investigated for systemic diseases and trauma was the only positive finding. In the central retinal venous occlusion study (August 1988 to July 1992) a total of 725 with years were enrolled, only three cases were bilateral (0.41%).¹ However in a 17 years study Hayrchi et al (1973 to 1990) which included all forms of vascular occlusions, there were 515 patients of CRVO, of whom 88 were bilateral (7.38%).² Fani et al presented a case of bilateral central retinal vein occlusion in a colonic cancer patient in 2001.³ Balogh Z, Berta A and associates presented a case report in 2011 regarding a young patient who presented with bilateral central retinal vein occlusion caused by malignant hypertension.⁴ In our case the cause of Bilateral simultaneous central retinal vein occlusion was trauma alone.

The treatment recommendation have generally been panretinal photocoagulation or PRP, intravitreal steroid and intravitreal Anti-VEGF agents. Panretinal photocoagulation or PRP is a LASER treatment that destroys the outward parts of the retina and is reserved for very severe cases of ischemic CRVO. While it is reasonably good at preventing the dreaded complication of neovascular glaucoma, it does nothing to help the patient's vision.

Laatikainen et al, in a prospective randomised trial, determined that, prophylactic xenon panretinal photocoagulation reduced the incidence of neovascularisation and cystoid macular oedema but had no effect on visual acuity.⁵ These findings have been confirmed⁶ and others have used panretinal photocoagulation to reverse neovascular glaucoma and rubeosis.⁷⁻¹⁰ More recently, however, the CRVO study group recommended providing frequent follow up of at risk patients and application of laser when neovascularisation occurs¹¹ because there was no benefit of prophylactic therapy over therapy when complications arise. The follow-up recommended was at least monthly and perhaps more in the early stages of the condition.

In the last few years, another treatment option has emerged. Injection of Anti-VEGF therapies blocks the growth factor that stimulates the growth of new abnormal blood vessels. VEGF, the vascular endothelial growth factor, contributes to the leaking of fluid out of the vessels, and anti-VEGF counteracts this effect. One anti-VEGF drug has been approved by the US drug authority FDA for treatment of CRVO. Anti-VEGF therapy works without destroying parts of the retina and can actually reverse some vision loss in a majority of the

affected patients. In cases that do not subsequently become ischaemic, the prognosis is reasonably good with return of vision to normal or near normal in about 50% cases. The main cause for poor vision is chronic macular oedema which may lead to secondary RPE changes.

The prognosis of ischemic CRVO is extremely poor due to macular ischaemia. Rubeosis iridis develops in about 50% of eyes, usually between 2 and 4 months (100-day glaucoma), and there is a high risk of neovascular glaucoma. The development of opticociliary shunts may protect the eye from anterior segment neovascularisation and probably indicates a dramatic reduction in risk. Retinal neovascularisation occurs in about 5% of eyes.

There are many patients of old ages suffering from hypertension, diabetes or otherwise who can get blocked central retinal vein. In normal course of events and the therapy available is a drawn out process with indefinite horrible outcome. The people can lose their eyesight either due to 100-day glaucoma or from membrane formation in the retina leading to drastic complications.

References

1. Clarkson JG. Central retinal vein occlusion. In : Ryan SJ, Eeditor. Retina. St Louis MO, USA: Mosby ; 1994. p. 379-85
2. The Central retinal vein occlusion study group. Baseline & Early natural history report : Central retinal vein occlusion study. Arch ophthalmol 1993; 111: 1087-95
3. Segev S, Segev A, Livne A, Assia EI, Mekori YA. Bilateral Central Retinal Vein Occlusion in a Patient with Occult Colonic Cancer. Arch Ophthalmol. 2001; 119:1552- 1553.
4. Balogh Z, Berta A, Pfliegler G, Nagy V. Bilateral Central Retinal Vein Occlusion in a Young Patient. Clin Exp Hypertens. 2011; 33(1): 53-5.
5. Laatikainen L, Kohner EM, Khoury D, Blach RK. Panretinal photocoagulation in central retinal vein occlusion: a randomised controlled clinical study. Br J Ophthalmol 1977; 61:741-53.
6. Laatikainen L. Photocoagulation in retinal venous occlusion. Acta Ophthalmol (Copenh) 1977; 55:478-88.
7. Magargal LE, Donoso LA, Sanborn GE. Retinal ischemia and risk of neovascularisation following central retinal vein obstruction. Ophthalmology. 1982; 89:1241-5.
8. Murdoch IE, Rosen PH, Shilling JS. Neovascular response in ischaemic central retinal vein occlusion after panretinal photocoagulation. Br J Ophthalmol 1991; 75:459-61.
9. Magargal LE, Brown GC, Augsburger JJ, Donoso LA. Efficacy of panretinal photocoagulation in preventing neovascular glaucoma following ischemic central retinal vein obstruction. Ophthalmology 1982; 89:780-4.
10. May DR, Klein ML, Peyman GA. A prospective study of xenon arc photocoagulation for central retinal vein occlusion. Br J Ophthalmol 1976; 60:816-8
11. The Central Vein Occlusion Study Group. A randomised clinical trial of early panretinal photocoagulation for ischaemic central vein occlusion: The central vein occlusion study group report. Ophthalmology 1995; 102:1434-44.