

Case Report

A case of acute pancreatitis with normal serum lipase

Alam A¹, Rahman MFU², Rahman M³, Khan AH⁴, Chowdhury MMH⁵, Chowdhury MAJ⁶

Abstract

Patients with acute pancreatitis typically present with epigastric pain. In such patients, demonstration of elevated pancreatic enzymes and swollen pancreas by radiological investigations are sufficient to confirm the diagnosis. Here we present case history of a middle aged man who had epigastric pain, fever and swollen pancreas but enzyme levels were normal. He responded to conventional conservative treatment.

Keywords: acute pancreatitis, serum amylase, serum lipase

Introduction

Acute pancreatitis is a medical emergency. Clinical manifestations range from mild epigastric discomfort to critical illness and even death. Common aetiology

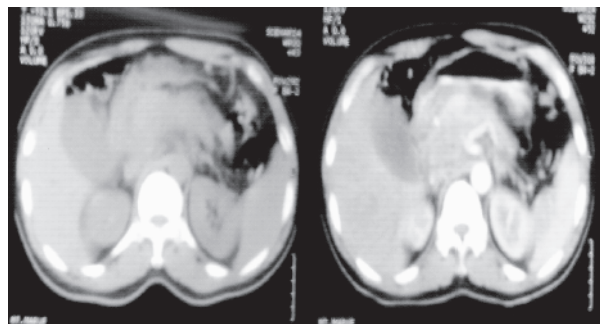
includes alcohol use, gallstones, hypertriglyceridemia, hypercalcemia, medications, endoscopic retrograde cholangiopancreatography and trauma; however, approximately 20% of cases remain idiopathic.¹ Diagnosis of acute pancreatitis requires the presence of the two of the following three criteria: a) characteristic abdominal pain; b) serum amylase and/or lipase more than 3 times the upper limit of normal; and b) computed tomography (CT) scan findings compatible with acute pancreatitis.² Mortality in acute pancreatitis may be up to 47%.³

Case report

A 43-year-old Bangladeshi non-alcoholic male presented with fever for 12 days with mild upper abdominal pain. Fever was intermittent, highest temperature 103⁰ F and did not respond to intravenous ceftriaxone 1 gm daily for 7 days. After admission, patient had mild upper abdominal tenderness with an ill-defined epigastric lump that did not move with respiration. Abdominal USG revealed that pancreas was slightly swollen (body - 2.4 cm x head - 3 cm x tail- 2.6 cm) and hypoechoic, distended gallbladder with biliary sludge and trace ascites in lower abdomen. CT scan revealed pancreas was enlarged in size, oedematous with mild peri-pancreatic collection, stranding of peri-pancreatic fat plane was noted an pancreatitis with mild ascites (Figure-1)

1. * Dr Afroja Alam
Assistant Professor & Resident Physician
Department of Internal Medicine
Bangabandhu Sheikh Mujib Medical University
Dhaka. E-Mail: shafiohi@gmail.com
2. Dr Mohammad Ferdous Ur Rahman
Assistant Professor, Department of Internal Medicine
Bangabandhu Sheikh Mujib Medical University
Dhaka
3. Dr Mahbubur Rahman
Consultant, Department of Internal Medicine,
Bangabandhu Sheikh Mujib Medical University
Dhaka
4. Dr Abed Hussain Khan
Medical Officer, Department of Internal Medicine
Bangabandhu Sheikh Mujib Medical University
Dhaka
5. Dr Mohammad Mainul Hasan Chowdhury
MD-Resident, Phase-B, Department of Internal
Medicine, Bangabandhu Sheikh Mujib Medical
University, Dhaka
6. Professor Dr M A Jalil Chowdhury
Chairman, Department of Internal Medicine
Bangabandhu Sheikh Mujib Medical University
Dhaka

*For correspondence



Before contrast

After contrast

Figure-1: CT-scan of abdomen showing enlarged, oedematous pancreas, mild pancreatic collection, stranding of peri-pancreatic fat plan. Main pancreatic duct is mildly dilated.

Pancreatic enzyme analysis revealed normal serum amylase- 77U/L (normal upto 95), serum lipase- 170 U/L

(normal range, 23-300) and urinary amylase- 292 IU/L (normal <360). Total and differential WBC count was normal, ESR- 25mm in 1st hour, CRP was 29 mg/L (normal <6mg/L). S Alk Phos - 340 U/L (50-136), CA-19-9- 1.76 U/ml (<37), S TG - 63mg/dl (<150), chol- 132 mg/dl (<200), HDL- 17 mg/dl (>40), LDL- 102 mg/dl (<130). After restarting ceftriaxone 1 gm BD with fluid resuscitation, analgesic and nutritional support patient became afebrile after 3 days and abdominal pain improved and he was discharged after continuation of ceftriaxone for 12 days. At six months follow-up no more fever or abdominal pain improved and he was discharged after continuation of ceftriaxone for 12 days. At six months follow-up no more fever or abdominal pain were noticed. Pancreas became radiologically normal after six months on repeat CT-scan of abdomen (Figure-2).

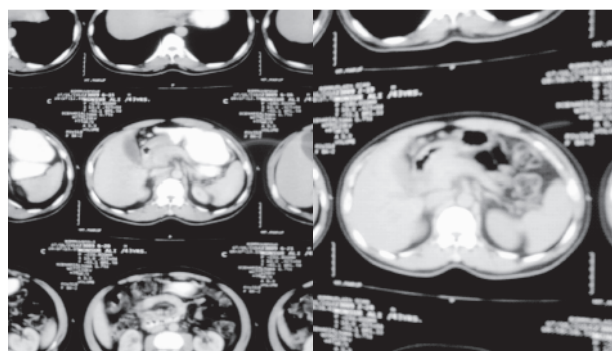


Figure-2: CT-scan of abdomen showing normal pancreatic morphology after six months. Here Pancreas is not enlarged, not oedematous. No pancreatic collection. Normal peri-pancreatic fat plan. Main pancreatic duct is not dilated.

Discussion

Acute pancreatitis is one of the most common causes for hospitalization in the United States.⁴ It carries an overall mortality of around 5% and as high as 47% in patients with multi-organ failure.³ Necrotizing pancreatitis is responsible for almost all mortalities attributed to acute pancreatitis. Diagnosis is based on clinical features, biochemical tests and imaging studies. Normal serum amylase levels have been reported in some cases of acute pancreatitis, but serum lipase levels are usually elevated.⁵ Normal serum lipase in the setting of acute pancreatitis is an extremely rare occurrence.⁶⁻⁹ We present this case of acute pancreatitis (diagnosed on clinical and radiological grounds) with normal serum amylase, lipase and urinary amylase levels without any established aetiology.

Following the initial onset of acute pancreatitis, serum amylase level increases rapidly over 3 to 6 hours, with a half-life of 10-12 hours; it remains elevated for 3 to 5 days

and is excreted by the kidneys.⁵ Serum lipase level increases in 3 to 6 hours, peaks in 24 hours and remains elevated for one to two weeks.⁶ Serum lipase, unlike amylase, is reabsorbed by the kidney tubules and hence remains elevated for prolonged period which may be helpful in late presenting patients.¹⁰ Serum amylase can be normal in acute or chronic pancreatitis, hypertriglyceridemia-induced pancreatitis or in late presentations.⁵ In our case, late presentation may be the possible cause of normal serum amylase. Normal blood lipase level in our patient is a rare event. Cartier et al. reported acute pancreatitis diagnosed on CT scan with normal lipase levels in a patient presenting with abdominal pain and vomiting for 24 hours.⁶ Mayersak et al. reported a case of pancreatitis diagnosed on CT scan in a post-operative patient with normal serum amylase, lipase and urinary amylase.⁷ The normal enzyme levels may be due to late presentation of the patient and/or pancreatic necrosis leading to decrease in the levels of amylase and lipase.

Although some experts criticize the use of early imaging in the presence of other supporting evidence of pancreatitis, it may be helpful in establishing the diagnosis when biochemical markers are not compatible with the clinical suspicion. The treatment of mild acute pancreatitis is supportive and our patient improved with fluid resuscitation, pain management and nutritional support. In conclusion, we suggest that in the appropriate clinical setting, diagnosis of acute pancreatitis should be suspected even with normal amylase and lipase levels and imaging modalities may provide confirmation of diagnosis.

References

1. Whitcomb DC. Value of genetic testing in management of pancreatitis. *Gut*. 2004; 53:1710-17.
2. Banks PA, Freeman ML. Practice Parameters Committee of the American College of Gastroenterology. Practice guidelines in acute pancreatitis. *Am J Gastroenterol*. 2006; 101: 2379-400.
3. Talukdar R, Vege SS. Recent developments in acute pancreatitis. *Clin Gastroenterol Hepatol*. 2009; 7(11 Suppl) : S3-9.
4. DeFrances CJ, Hall MJ, Podgornik MN. Advance Data From Vital and Health Statistics. No. 359. 2003 National Hospital Discharge Survey. Centers for Disease Control and Prevention. Atlanta, GA 30333, USA. National Center for Health Statistics, 2005.

5. Clavien PA, Robert J, Meyer P, Borst F, Hauser H, Herrmann F, et al. Acute pancreatitis and normoamylasemia. Not an uncommon combination. *Ann Surg.* 1989; 210:614-20.
6. Cartier T, Sogni P, Perruche F, Meyniard O, Claessens YE, Dhainaut JF, Der Sahakian G. Normal lipase serum level in acute pancreatitis: a case report. *Emerg Med J.* 2006; 23:701-2.
7. Mayersak JS, Viviano CJ, Babiarz JW. Computed axial tomography pancreatitis: an atypical asymptomatic postoperative disease without serum or urinary enzyme evaluation. *Wis Med J.* 1997; 96:25-28.
8. Shah AM, Rodney E, Kothari ST, Maksoud C, DiGiacomo WS, Baddoura W. Acute Pancreatitis with Normal Serum Lipase: A Case Series. *J Pancreas.* (Online) 2010 Jul 5; 11(4):369-72.
9. Khan FY, Matar I. Chylous ascites secondary to hyperlipidemic pancreatitis with normal serum amylase and lipase. *World J Gastroenterol.* 2007 January 21; 13(3): 480-82 Sternby B, O'Brien JF,
10. Zinsmeister AR, Di Magno EP. What is the best biochemical test to diagnose acute pancreatitis? A prospective clinical study. *Mayo Clin Proc.* 1996; 71:1138-44.