

Case Report

Acute myopericarditis presenting as effusive-constrictive pericarditis— a case report

Adhikary DK¹, Hasan MN², Siddique MA³, Banerjee SK⁴, Iqbal ATM⁵, Hasan MN⁶, Amin MR⁷

Abstract

Myopericarditis is primarily a pericardial inflammatory syndrome occurring when clinical diagnostic criteria for pericarditis are satisfied and concurrent mild myocardial involvement is documented by elevation of biomarkers of myocardial damage (i.e. increased troponins). Limited clinical data on the causes of myopericarditis suggest that viral infections are among the most common causes in developed countries. Cardiotoxic viruses can cause pericardial and myocardial inflammation via direct cytolytic or cytotoxic effects and/or subsequent immune-mediated mechanisms. Many cases of myopericarditis are subclinical. In other patients, cardiac symptoms and signs are overshadowed by systemic manifestations of infection or inflammation. The increased sensitivity of troponin assay and contemporary widespread use of troponins has greatly increased the reported number of cases. Management is similar to that reported for pericarditis, generally with an empiric anti-inflammatory drugs mainly aimed to control symptoms. Rest and avoidance of physical activity beyond normal sedentary activities has been recommended for 6 months is recommended as for myocarditis. At present, there is no evidence that troponin elevation confers worse prognosis

(i.e. a greater risk of recurrence, death or transplantation) in patients with preserved left ventricular function. Usually complete remission is seen in 3 to 6 months. We report here a case of a 18 year young man with acute myopericarditis who presented with transient effusive-constrictive pericarditis.

Key words: Myopericarditis, effusive-constrictive pericarditis, increased troponins.

Introduction

Acute myocarditis is an acute inflammatory disorder that primarily involves the myocardium. It can be caused by infections, various drugs, systemic diseases and toxins, although viral infection is the most common etiology.¹ Acute pericarditis is often accompanied by some degree of myocarditis, although these two entities are not always associated. In clinical practice, pericarditis and myocarditis coexist because they share common etiologic agents, mainly cardiotoxic viruses such as coxsackie viruses.^{2,3} Effusive-constrictive pericarditis is a clinical hemodynamic syndrome in which constriction of the heart by the visceral pericardium occurs in the presence of tense effusion in a free pericardial space.⁴

Diagnosing and managing acute myopericarditis at an early stage is important, but difficult, since it mimics acute myocardial infarction and its natural course is markedly heterogeneous, ranging from self-limiting illness to cardiopulmonary collapse or death. Few reports have described acute myopericarditis, presenting as transient effusive-constrictive pericarditis and mimicking acute myocardial infarction.

Case Report

A 18 year young man, presented to the emergency department with chest pain, nausea, shortness of breath and general weakness. The patient mentioned having flu-like symptoms 2 weeks prior to presentation. He had no significant past medical history or family history. He had a heart rate of 136 beats/min, blood pressure 100/75 mm of Hg, respiratory rate 24 breaths/min and body temperature 36.8°C.

Initial laboratory findings revealed a white blood cell count of 15,230/mm³, a hemoglobin level of 14.3 g/dl and a platelet count of 188,000/mm³. Cardiac enzyme findings

1. *Dr Dipal Krishna Adhikary, Assistant Professor Department of Cardiology, Bangabandhu Sheikh Mujib Medical University, Shahbag, Dhaka, Bangladesh.
2. Dr Md Nazmul Hasan, Resident, Phase-B, Department of Cardiology, Bangabandhu Sheikh Mujib Medical University, Shahbag, Dhaka, Bangladesh.
3. Dr Md Abu Siddique, Professor, Department of Cardiology, Bangabandhu Sheikh Mujib Medical University, Shahbag, Dhaka, Bangladesh.
4. Dr Sajal Krishna Banerjee, Professor and Chairmen Department of Cardiology, Bangabandhu Sheikh Mujib Medical University, Shahbag, Dhaka, Bangladesh.
5. Dr ATM Iqbal, Associate Professor, Department of Cardiology, Bangabandhu Sheikh Mujib Medical University, Shahbag, Dhaka, Bangladesh.
6. Dr Md Nazmul Hasan, Medical Officer, Department of Cardiology, Bangabandhu Sheikh Mujib Medical University, Shahbag, Dhaka, Bangladesh.
7. Dr Md Rasul Amin, Assistant Professor, Department of Cardiology, Bangabandhu Sheikh Mujib Medical University, Shahbag, Dhaka, Bangladesh.

*For correspondence

were: creatinine kinase (CK)- 238 IU/L (reference range 0 - 190), CK-MB- 17.83 ng/mL (reference range 0 - 5), and troponin I - 11.36 ng/mL (reference range 0 - 0.78). The B-type natriuretic peptide level was elevated at 170.58 pg/mL (reference range 2 - 100). The initial electrocardiogram showed ST segment elevation with concavity upward in lead II, III, AVF & V2-V6 (Figure-1).

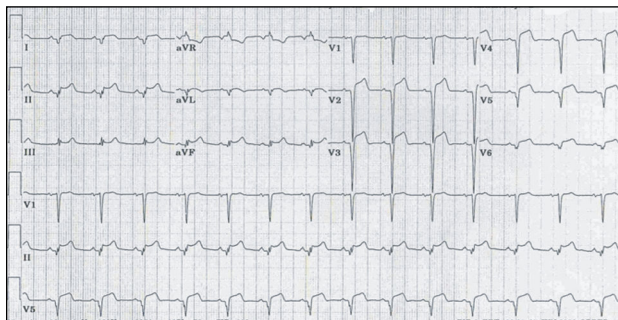


Figure-1: 12 lead electrocardiogram showed ST segment elevation in lead II,III,Avf & V2-V6

Echocardiography showed global wall motion abnormalities and mild systolic dysfunction (EF-48%) of the left ventricle, with a moderate amount of pericardial effusion (figure-2).

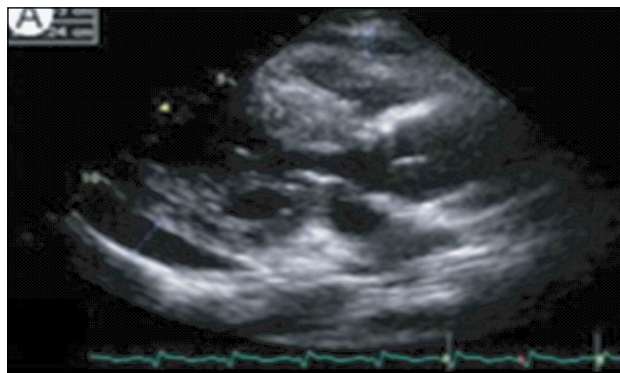


Figure-2: Echocardiography showed global wall motion abnormalities with a moderate amount of pericardial effusion.

Echocardiography revealed constrictive physiology, such as septal bouncing, significant respiratory variation in the mitral inflow E wave, and increased diastolic flow reversal in the hepatic vein on expiration. Initial chest X-ray and computed tomography (CT) of chest showed pericardial effusion and bilateral pleural effusions. Tests for Epstein-Barr virus IgM, cytomegalovirus IgM, herpes simplex virus IgM, antineutrophil cytoplasmic antibodies (ANCA), antinuclear antibodies (ANA), and anti-ds DNA were negative. However, enzyme-linked immunosorbent assay (ELISA), serologic antibody tests for coxsackie virus revealed a high serum titer (> 1:32).

The patient received conservative treatment with ibuprofen, ramipril and furosemide. His cardiac enzymes and ST segment elevation normalized within 3 weeks. After 6 weeks, chest CT indicated disappearance of the pericardial and pleural effusions. Echocardiography showed disappearance of constrictive physiology and normalized LV systolic function without regional wall motion abnormalities. A follow-up echocardiogram revealed normalized septal motion and left ventricular systolic function, disappeared pericardial effusion, and normal respiratory variation of the mitral inflow E wave and inferior vena cava.

Discussion

This case illustrates acute myopericarditis with transient effusive-constrictive pericarditis. When considering acute myocarditis and acute pericarditis, physicians usually place clinical emphasis on one or the other diagnosis. However, acute myopericarditis must be distinguished from pericarditis since a diagnosis of myocarditis has greater prognostic significance than that of pericarditis. Myocarditis can lead to fatal complications, including ventricular arrhythmia, or cardiac dilatation and subsequent cardiac collapse. These complications can develop abruptly and rapidly become life-threatening.^{1,5}

Endomyocardial biopsy is not always required, as it is associated with certain procedural risks and offers limited benefits from a therapeutic perspective. Nevertheless, it remains the gold standard for diagnosing myocarditis.² We did not perform an invasive endomyocardial biopsy on our patient since he responded well to medical treatment. The limited sensitivity and specificity of this diagnostic test demonstrate that the accurate diagnosis of myocarditis should not be based on histopathologic findings alone.

Effusive-constrictive pericarditis is an uncommon clinical entity characterized by pericardial effusion with constrictive physiology. It is regarded as a form of subacute constrictive pericarditis. The effusion may be lobulated, concentric, or regional. Over time, the effusion may become organized and the pericardial layers may become thickened.⁶

In some patients with acute constrictive pericarditis, however, the symptoms and constrictive physiologic features resolve with medical management alone, a phenomenon that was first reported in 1987 and has been designated as transient constrictive pericarditis;⁷ this occurs frequently in post-pericardiectomy patients. However, it is also seen after infection or in the setting of uremia. A recent study of 212 patients who had echocardiographic findings of constrictive pericarditis showed that 17% of these patients had resolution of constrictive physiology on follow-up

echocardiography, without the need for pericardiectomy. In a subset of 22 patients who were followed regularly during the course of their illness, resolution of the constrictive hemodynamic features occurred an average of 8.3 weeks after diagnosis.⁸ In the present case, 4 weeks was required for transient constrictive hemodynamics to resolve based on echocardiographic follow-up studies.

Respiratory variations in the mitral inflow and central venous flow velocities can be diagnostic, even in patients without definite pericardial abnormalities.⁹ Tissue Doppler imaging (TDI) is a relatively new and effective echocardiographic tool that can help in the clinical diagnosis of constrictive pericarditis. Incremental M-mode, 2D, and transmitral flow Doppler studies with TDI provide an overall sensitivity and specificity of 88.8% and 94.8%, respectively, for the diagnosis of constrictive pericarditis.¹⁰

Pericardiectomy is the gold standard for the treatment of recurrent or constrictive pericarditis.³ However, in some patients, such as our own, constrictive pericarditis may resolve spontaneously or after treatment with anti-inflammatory agents such as those mentioned above. Our patient recovered without sequelae.

In conclusion, acute myopericarditis must be distinguished from acute pericarditis because of the possibility of rapid, life-threatening progression. Thus, early diagnosis and management are important. With that in mind, clinical examination and echocardiography are essential. If a patient presenting with acute viral myopericarditis has signs of transient effusive-constrictive pericarditis, then he or she can be treated with medical therapy and followed with serial echocardiographic examinations.

References

1. Oakley CM. Myocarditis, pericarditis and other pericardial diseases. *Heart*. 2000; 84: 449–54.
2. Imazio M, Trinchero R. Myopericarditis: Etiology, management and prognosis. *Int J Cardiol*. 2008 ; 127 : 17–26.
3. Lange RA, Hillis LD. Clinical practice: acute pericarditis. *N Engl J Med*. 2004 ; 351 : 2195–2202.
4. Sagrista-Sauleda J, Angel J, Sanchez A, Permanyer-Miralda G. Effusive-constrictive pericarditis. *N Engl J Med*. 2004 ; 350 : 469–75.
5. Roubille F, Gahide G, Moore-Morris T. Epstein Barr virus (EBV) and acute myopericarditis in an immunocompetent patient: first demonstrated case and discussion. *Intern Med*. 2008 ; 47: 627–629.
6. Sengupta PP, Eleid MF, Khandheria BK. Constrictive pericarditis. *Circ J*. 2008; 72 :1555–62.
7. Sagrista-Sauleda J, Permanyer-Miralda G, Candell-Riera J, Angel J, Soler-Soler J. Transient cardiac constriction: an unrecognized pattern of evolution in effusive acute idiopathic pericarditis. *Am J Cardiol*. 1987 ; 59 : 961–66.
8. Haley JH, Tajik AJ, Danielson GK, Schaff HV, Mulvagh SL, Oh JK. Transient constrictive pericarditis: causes and natural history. *J Am Coll Cardiol*. 2004 ; 43 : 271–5.
9. Sun JP, Abdalla IA, Yang XS, et al. Respiratory variation of mitral and pulmonary venous Doppler flow velocities in constrictive pericarditis before and after pericardiectomy. *J Am Soc Echocardiogr*. 2001 ; 14 : 1119–26.
10. Sengupta PP, Mohan JC, Mehta V, Arora R, Pandian NG, Khandheria BK. Accuracy and pitfalls of early diastolic motion of the mitral annulus for diagnosing constrictive pericarditis by tissue Doppler imaging. *Am J Cardiol*. 2004 ; 93 : 886–90.