

## Case Report

### Adrenoleukodystrophy: two case reports

Kundu GK<sup>1</sup>, Rahman MM<sup>2</sup>, Amin MR<sup>3</sup>, Habib MA<sup>4</sup>, Ahmed S<sup>5</sup>, Kabir MS<sup>6</sup>, Laila K<sup>7</sup>

#### Introduction

Adrenoleukodystrophy (ALD) is a peroxisomal disorder characterized by the accumulation of saturated very long chain fatty acids (VLCFA) in plasma, various tissues of body and central nervous system. It causes demyelination and adrenocortical insufficiency.<sup>1</sup> High levels of very long chain fatty acids are found in tissues and body fluids, resulting from their impaired  $\beta$ -oxidation in the peroxisomes. The most common form of ALD is an X-linked disorder with various presentations which is caused by mutations in the ABCD1 gene located on Xq28. The gene encodes a transmembrane transporter involved in the importation of very long chain fatty acids into peroxisomes. The phenotypic presentations are highly variable, which may lead to delayed recognition and misdiagnosis, as attention deficit and/or hyperactivity disorder in boys or multiple sclerosis in adults. The most common clinical picture is of a degenerative neurologic disorder appearing in childhood or adolescence and progressing to severe dementia and deterioration of vision, hearing, speech, and gait and death occur within a few years. Many patients have evidence of adrenal insufficiency at the time of neurologic presentation.<sup>2</sup> Hydrocortisone and mineralocorticoid are necessary to treat adrenal insufficiency. High doses of hydrocortisone preoperatively and during recovery are needed for surgery and other stressful illnesses in affected individuals.<sup>3</sup>

Here, we described two patients with childhood onset ALD with clinical and laboratory features to illustrate the wide clinical variability of this condition.

**Key words:** Adrenoleukodystrophy (ALD), very long chain fatty acid(VLCFA), X- linked disorder.

#### Case 1

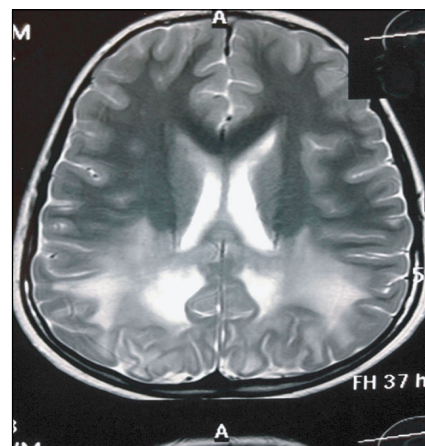
An 8 years old male child from rural area of Bangladesh was admitted into Paediatric neurology unit of department of pediatrics, BSMMU with the complaints of difficulty in walking for 6 months. His walking and gait disorder was gradually increasing and now became bed ridden. He had a history of repeated attacks of seizure for 6 months. His mother also noticed deterioration of school performance of the child over last 1 year due to impairment of vision. His past medical history was unremarkable. His family history was nothing contributory. He was treated by some indigenous medication prior to admission.

His physical examination revealed pigmentation of skin, vital signs including blood pressure was within normal limit. Ophthalmological examination revealed bilateral optic atrophy. Neurological examination revealed normal muscle bulk, increased tone, reduced muscle power, exaggerated jerks and bilateral extensor plantar response. Gait could not be evaluate due to weakness.

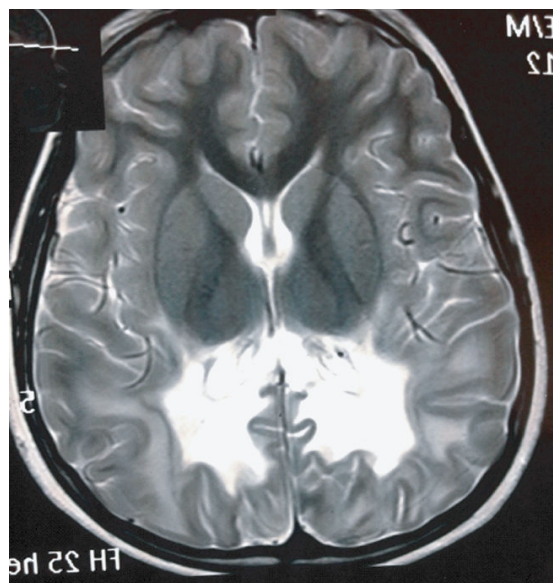
All routine investigations revealed normal findings. MRI of brain showed bilateral, symmetric hyper intense signal change in T2 and FLAIR weighted images (Figure-1, 2) in subcortical white matter of both parieto-occipital regions which is compatible with Adrenoleukodystrophy.

1. \*Dr Gopen Kumar Kundu, Associate Professor Department of Paediatric Neurology, BSMMU, Dhaka. Email : gopen.kundu@gmail.com
2. Dr Md Mizanur Rahman, Professor, Department of Paediatric Neurology, BSMMU, Dhaka
3. Dr Md Rezaul Amin, Assistant Professor, Department of Neurosurgery, BSMMU, Dhaka
4. Dr Md Ahsan Habib, Assistant Professor, Department of Neurology, BSMMU, Dhaka
5. Dr Sanjida Ahmed, Medical Officer, Department of Paediatric Neurology, BSMMU, Dhaka
6. Dr Md Showkat Kabir, Assistant Professor of Community Ophthalmology, Department of Ophthalmology, BSMMU, Dhaka
7. Dr Kamrul Laila, Resident Phase-B, Department of Paediatrics, BSMMU, Dhaka

\*For correspondence



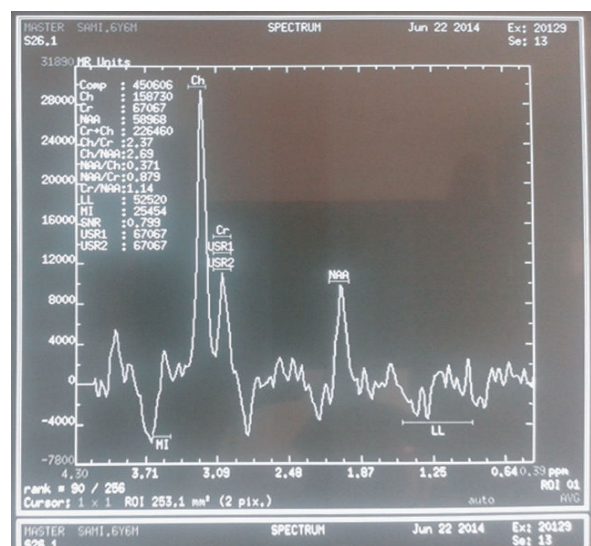
**Figure-1:** MRI of brain (T2 weighted image) shows hyperintense signal change in both parieto- occipital regions



**Figure-2:** MRI of brain (FLAIR) shows hyperintense signal change in both parieto- occipital regions

His random blood sugar and serum electrolyte were within normal limit, but serum Adrenocorticotropic hormone (ACTH) level was very high, 2018 pg/ml (normal 5 – 49 pg/ml). serum cortisol level was low, 2.1 microgm/dl (normal 5 – 25 microgm/dl). Ultrasonogram of abdomen to see adrenal gland was also normal. We have done a Magnetic Resonance Spectroscopy (MRS). Raised choline peak in comparison to creatine peak in MRS of brain indicates leukodystrophy (Figure-3).

The diagnosis of Adrenoleukodystrophy was strongly suggested from history, physical examination, laboratory



**Figure-3:** MRS of brain shows high choline peak in comparison to creatine peak indicate demyelination (ALD)

investigations and neuroimaging findings (MRI and MRS).

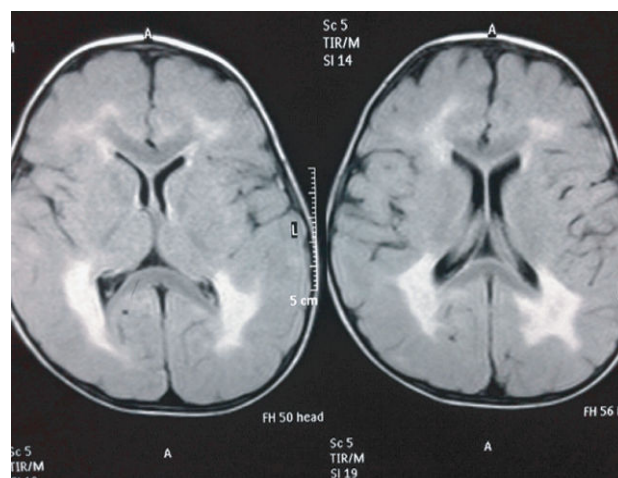
Treatment was started with steroids (hydrocortisone and fludrocortisones). The patient was symptomatically improved. Now he is on follow up.

**Case 2:**

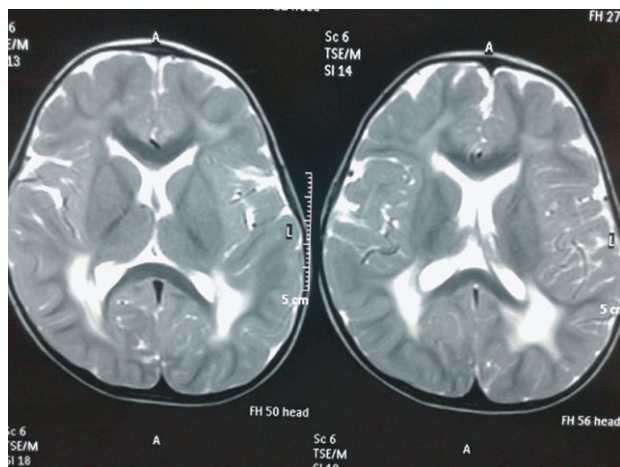
An 8 years old male child of consanguineous mating from Rangpur got admitted into Paediatric Neurology department of BSMMU with the complaints of visual and hearing impairment for 6 months and history of several episodes of convulsion for last 20 days. Convulsion was focal, tonic-clonic in nature, persisted for 2-3 minutes, total 3 episodes occurred over 5 hours. His blurring of vision and hearing impairment was increasing day by day. On query mother gave history of poor school performance over last 6 months due to inattention and poor co-ordination. His past medical history was unremarkable. His family history was nothing contributory. He was hospitalized locally prior to admission in BSMMU and treated with parenteral phenobarbitone for seizure.

His vital signs including blood pressure were within normal limit. Fundoscopy examination showed bilateral optic atrophy. Neurological examination revealed bilateral sensory neural hearing loss. Motor system was normal.

All routine investigations revealed normal findings. EEG was done and there was partial seizure. MRI of brain showed bilateral, symmetrical hypointense signal change in T1 weighted images and bilateral, symmetrical hyper intense signal change in T2 weighted image and FLAIR weighted images in subcortical white matter of both parieto-occipital region gradually progresses to frontal lobe which is compatible with Adrenoleukodystrophy ( Figure-4,5). His random blood sugar and serum electrolyte were normal, but serum Adrenocorticotropic Hormone (ACTH) level was



**Figure-4:** MRI of brain (FLAIR image) shows hyperintense signal change in both parieto- occipital regions



**Figure-5:** MRI of brain ((T2 weighted image) shows hyperintense signal change in both parieto- occipital regions.

high, 265 pg/ml (normal – 5 – 49 pg/ml), Serum cortisol level was low, 66.5 nmol/L (normal 138 – 690nmol/L). Ultrasonogram of abdomen to see adrenal gland was also normal. No ketone was detected in urine.

The diagnosis of Adrenoleukodystrophy was strongly suggested from history, physical examination, laboratory investigations and neuroimaging (MRI). Treatment was started with steroids (hydrocortisone and fludrocortisones) & discharged with proper counseling.

### Discussion

ALD is the most common inherited peroxisomal disorder characterized by abnormal accumulation of saturated VLCFA in plasma, white matter of brain, testis, adrenal cortex and cultured skin fibroblasts which are associated with reduced ability to degrade these fatty acids by peroxisomal  $\alpha$ -oxidation.<sup>4-7</sup>

The estimated incidence of the disease is 1-5/100000.<sup>7</sup> The classification of the different phenotypes of X-ALD is somewhat arbitrary. At present, at least six variants can be distinguished.<sup>8</sup> These are childhood cerebral ALD, adolescent cerebral ALD, adult cerebral ALD, AMN, the Addison only and asymptomatic phenotype.<sup>9</sup>

The clinical course in ALD is characterized by behavioral disorders, ataxia, visual loss, decreased hearing and epileptic seizures and followed by mental deterioration, psychosis and death. Adrenal insufficiency is a usual finding, but does not always precede neurologic disease.<sup>10, 11</sup> About 30% cases have normal adrenal function.<sup>12</sup> We should think a case of ALD when a patient present with adrenal insufficiency associated with neurologic manifestations, like our patients.

MRI is more sensitive than computed tomography to detect these demyelinating diseases.

MRI of brain of ALD patient showed bilateral, symmetrical hypointense signal change in T1 weighted images and bilateral, symmetrical hyperintense signal change in T2 and FLAIR weighted images in subcortical white matter of both parieto-occipital regions which is compatible with adrenoleukodystrophy. Typical demyelination begins bilaterally in the occipital region but gradually spreads to parietal, temporal and the finally frontal white matter.<sup>12</sup> Features of primary adrenal insufficiency evidenced by high serum adrenocorticotropic hormone (ACTH), low serum cortisol level should be measured. VLCFA can be measured in plasma, which will be increased.<sup>13</sup>

The disease is progressive, culminating within a few years in dementia, blindness, quadriplegia and death.<sup>12</sup> Neurological manifestations may precede, follow or occur concomitantly with symptoms of adrenocortical insufficiency. Reduced adrenocortical reserve may be demonstrable even in children without clinical manifestations of the disorder.<sup>13</sup> In this child the symptoms of adrenocortical insufficiency preceded the onset of neurological manifestations.

After the discovery of increased concentrations of VLCFAs in blood and other tissues of patients with X-ALD, several dietary treatments were developed. No effective treatment is available. So treatment is supportive and symptomatic. Bone marrow transplantation and immunosuppressive therapies are currently being investigated. Oleic acid (C18:1), a monounsaturated fatty acid, was shown to competitively inhibit the fatty acid elongation system, thus interfering with the biosynthesis of VLCFAs. With the combination of fat restriction and oral supplementation with glycerol trioleate (GTO) it was possible to reduce plasma VLCFA concentrations by about 50 %. The 4:1 combination of the GTO and GTE oils became known as Lorenzo's oil is essential for the the treatment of ALD patient in early stage.<sup>14</sup> So many patients are still treated with Lorenzo's oil worldwide. Lorenzo's oil has no effect in patients with neurologic symptoms but it may postpone the onset of neurological symptoms in asymptomatic males.<sup>15</sup> Early diagnosis of the disease gives the opportunity of genetic counseling, carrier detection and antenatal diagnosis and thus prevents the incidence of this devastating disease.

### References

1. B.lent . Okan Y. Olcay G. Adrenoleukodystrophy: Two Case Reports and a Review of the Literature. Turkish Journal of Endocrinology and Metabolism 2000; 1 : 37-40.

2. White P C. Adrenocortical insufficiency. Kliegman RM, Behrman RE, Geme JWS, Schor NF, Stanton BF editors. In : Nelson Textbook of Pediatrics. 19th Ed. Philadelphia : Saunders; 2012. p.1924 -6.
3. Ibrahim Abdulhamid, Sermin Saadeh and Nedim Cakan. A three-year-old boy with X-linked adrenoleukodystrophy and congenital pulmonary adenomatoid malformation: a case report. Journal of Medical Case Reports. 2009; 3:1947-9.
4. Moser HW. Adrenoleukodystrophy: phenotype, genetics, pathogenesis and therapy. Brain. 1989; 120: 1485-1508.
5. Singh I, Moser AB, Goldfischer S, Moser HW. Lignoceric acid is oxidized in the peroxisome: implications for the Zellweger cerebro-hepato-renal syndrome and adrenoleukodystrophy. Proc Natl Acad Sci. 1994; 81: 4203-7.
6. Siemerling E, Creutzfeldt HG. Bronzkrankheit und sclerosierende Encephalomyelitis (Diffuse sklerose). Archiv fr Psychiatrie. 1993; 68: 217-44.
7. Mosser J, Douar AM, Sarde CO, et al. Putative X-linked adrenoleukodystrophy gene shares unexpected homology with ABC transporters. Nature. 1993;361: 726-30.
8. Gartner J, Braun A, Holzinger A, Roerig P, Lenard HG, Roscher AA. Clinical and genetic aspects of X-linked adrenoleukodystrophy. Neuropediatrics. 1998; 29(1): 3-13.
9. Sobue G, Ueno-Natsukari I, Okamoto H. Phenotypic heterogeneity of an adult form of adrenoleukodystrophy in monozygotic twins. Ann Neurol. 1994; 36: 912-915.
10. O Neill BP, Marmion LC, Feringa R. The adrenoleukomyeloneuropathy complex: expression in four generations. Neurology. 1994; 31: 151-156.
11. Castellote A, Vera J, Vazquez E, Ruig M, Belmonte JA. MR in Adrenoleukodystrophy: Atypical presentation as Bilateral frontal demyelination. AJNR. 1995; 16: 814-5.
12. Sadeghi-Nejad A, Senior B. Adrenomyeloneuropathy presenting as Addison,s disease in childhood. N Eng J Med. 1990 ; 322: 13-6.
13. Lee AG, Olson RJ, Bonthius DJ, Phillips PH. Increasing extropia and decreasing vision in a school age boy. Surv Ophthalmol. 2007; 52(6): 672-9.
14. Odone A, Odone M. LorenzoÕs oil: a new treatment for adrenoleukodystrophy. J Pediatr Neurosci. 1989; 5: 55-61.
15. Moser HW, Naidu S, Kumar AJ, Rosenbaum AE. The adrenoleukodystrophies. Crit Rev Neurobiol. 1987; 5: 29-88.