

Case Report

Ruptured aneurysm of right sinus of valsalva - a case report

Hasan MN¹, Hasan MN², Hoque MH³, Zaman SMM⁴, Amin MR⁵, Haque M⁶, Joarder AL⁷

Abstract

The sinus of valsalva aneurysm (SVA) is a small dilatation caused by a separation between the aortic media and annulus fibrosus. It may be either acquired or congenital. The right coronary sinus is most frequently affected, with the most common complication being rupture of the sinus. Cardiac failure and sudden auscultation changes suggest the possibility of SVA rupture. Echocardiography is sufficient to diagnose SVA, its complications, repercussions and to determine surgical options. SVA, even if asymptomatic, has potential risks of expansion, rupture, cardiac failure, endocarditis, embolism and sudden death. This justifies surgical correction which has a low mortality rate in both the short and long-term.

Keywords: Sinus of valsalva, aneurysm rupture,

Introduction

Aneurysm of a sinus of valsalva is a rare congenital cardiac defect first described by Hope in 1839. Thurnam reported the first case of rupture of the sinus of Valsalva in 1840.¹ The

1. *Dr Md Nazmul Hasan, Resident, Department of Cardiology, Bangabandhu Sheikh Mujib Medical University, Dhaka, Bangladesh, Email: nazmulhasan45cmc@gmail.com
2. Dr Md Nazmul Hasan, Medical Officer, Department of Cardiology, Bangabandhu Sheikh Mujib Medical University, Dhaka, Bangladesh.
3. Dr Md Harisul Hoque, Associate Professor, Department of Cardiology, Bangabandhu Sheikh Mujib Medical University, Dhaka, Bangladesh.
4. Dr SM Mustafa Zaman, Associate Professor, Department of Cardiology, Bangabandhu Sheikh Mujib Medical University, Dhaka, Bangladesh.
5. Dr Md Rasul Amin, Assistant professor, Department of Cardiology, Bangabandhu Sheikh Mujib Medical University, Dhaka, Bangladesh.
6. Dr Mostashirul Haque, Assistant Professor, Department of Cardiology, Bangabandhu Sheikh Mujib Medical University, Dhaka, Bangladesh.
7. Dr Ariful Islam Joarder, Medical officer, Department of Cardiology, Bangabandhu Sheikh Mujib Medical University, Dhaka, Bangladesh.

*For correspondence

clinical characteristics of aneurysm of sinus of valsalva appear to be more common in patients of Asian origin. Male to female ratio is 3:1; it is uncommon in infancy and childhood and comprises approximately 0.1-3.5% of all congenital cardiac anomalies.

The mortality rate in patients with a sinus of Valsalva aneurysm in whom surgery is not performed is high within the first year after rupture. Cases of sudden death from sinus of valsalva aneurysm most commonly involve rupture of the aneurysm with the acute onset of overwhelming congestive heart failure, cardiac tamponade, dysrhythmia or coronary ischaemia depending on the location of the aneurysm and the subsequent flow disturbance. Size and location of the shunt are the major determinants of presentation and prognosis.^{2,3}

Case report

A 28 year old housewife, presented with the complaints of breathlessness for last 8 months which initially appeared on mild to moderate exertion but for last 2 months she felt breathlessness on minimal physical activity (NYHA class-iv). She also noticed chest pain and occasional palpitation at rest since last 8 months. She also complained of swelling of both lower limbs which decreases after taking diuretics. She denied any history of bronchial asthma and rheumatic fever in her childhood. She is a mother of 2 children and both of her pregnancies were uneventful. On examination, her pulse rate was 96 beats/min and blood pressure was 110/70 mm of Hg. Pitting type of pedal oedema was present. Respiratory system showed bilateral equal, normal vesicular breath sounds with no rhonchi or crepitations. On auscultation of cardiovascular system a loud continuous murmur was present over whole of the precordium. It was best heard along the lower left sternal border. A palpable thrill was present along the left sternal border. The remainder of the examination was otherwise normal. Routine blood investigations were normal except haemoglobin was 9 gm/dl. Chest X-Ray was normal. Electrocardiogram showed sinus tachycardia. Transthoracic echocardiography (TTE) showed a membranous out pouching of the right coronary cusp (RCC) protruding into right ventricle out flow tract (RVO) with a small (3.2 mm width) perforation (Figure-1). There was continuous

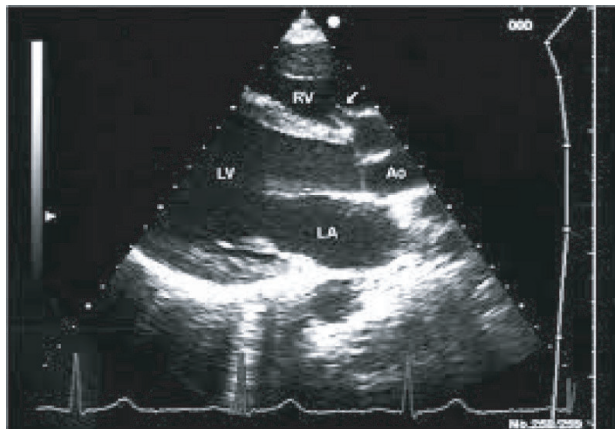


Figure- 1 : Transthoracic echocardiogram in parasternal short axis (PSAX) view

wave flow with a left to right shunt into the right ventricular outflow tract (RVO) below the pulmonary valve with a high-velocity systolic and diastolic flow signal (Figure-2).

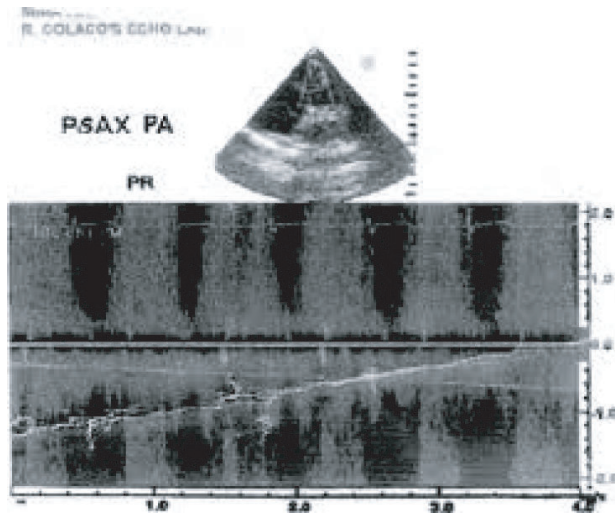


Figure 2 : Transthoracic echocardiogram in parasternal short axis (PSAX) view

The ventricular chambers were normal in size and there was good left ventricular function at rest. A diagnosis of perforated aneurysm of right sinus of valsalva was confirmed. Patient was continued with oral digoxin and furosemide and referred to cardiac surgery for repair of ruptured sinus of Valsalva.

Discussion

A ruptured sinus of valsalva aneurysm is a rare cardiac anomaly usually due to congenital cause. The sinuses of valsalva are dilatations in the aortic wall immediately superior to the attachments of three aortic wall cusps. The

sinuses are named according to their relationship with the coronary arteries i.e. the right coronary sinus, the left coronary sinus, and the non coronary sinus.^{4,5} Aneurysmal dilatation of the sinuses of valsalva occurs when the aortic media is defective, resulting in lack of fusion between aortic media and annulus fibrosus of the aortic valve.

Aneurysm typically develops as a discrete flaw in the aortic media within one of the sinuses of valsalva. Under the strain of aortic pressure, the sinus gradually weakens and dilates, causing the formation of an aneurysm. Lack of supporting tissue (e.g. ventricular septal defect) may contribute to instability and progressive distortion of the aortic sinus. Distortion and prolapsed of the sinus and aortic valve tissue can lead to progressive aortic valve insufficiency.

Other cases result from an inherited connective tissue abnormality (as in Marfan' syndrome or Ehlers-Danlos syndrome), from inflammatory disease (as in infective endocarditis, syphilitic or granulomatous aortitis, Behcet's disease) and from mechanical disruption (as in stab wounds, aortic dissection, after aortic valve replacement or ventricular septal defect repair).⁶

The right coronary sinus is the most common site of aneurysm formation and mostly ruptures into the right ventricle producing left to right shunting.⁷ Right coronary sinus aneurysms may also rupture into the right atrium. Non coronary sinus aneurysms generally rupture into the right atrium. Left coronary sinus aneurysms are extremely rare but they may rupture in to the pericardium, resulting in cardiac tamponade and death if not quickly recognized. Echocardiography is very accurate and reliable tool in diagnosing a sinus of valsalva aneurysm when correlated with clinical findings.⁸ In addition CT angiography and MRI also have been reported useful in diagnosing the sinus of valsalva.⁹ Cine phase contrast MRI can be used for assessment of insufficiency and shunt flow.

Sinuses of Valsalva aneurysms have one of three basic pathologic patterns.⁵⁻⁶ Unruptured aneurysms may cause distortion and obstruction in the right ventricular outflow tract. Dissection of the aneurysm into the cardiac tissue may occur causing obstruction or destruction of adjoining structures. Aneurysm may compress the interventricular septum, resulting in complete heart block with subsequent dizziness and syncope. Coronary artery compression may occur producing myocardial ischemia and chest pain. Occasionally a patient with unruptured sinus of valsalva aneurysm presents with symptoms related to chronic aortic regurgitation.

A slowly enlarging small perforation develops a fistulous

tract in to the right ventricle and presents with a small left to right shunt. Major risks are infective endocarditis and an extension of rupture with an increased shunt. Patient may remain asymptomatic for several years before presentation because of haemodynamic adjustment. However, as the degree of shunting gradually increases, symptoms related to volume overload such as dyspnoea and exercise intolerance develops.

An aneurysm that actually ruptures is often heralded by the sudden onset of dyspnoea and severe chest pain. Following this initial symptomatic period, the patient may become asymptomatic even without treatment as the body adjusts haemodynamically to the left to right shunting. However as the shunting and volume overload overcome the compensatory mechanisms, symptoms of congestive heart failure result.

Ruptured sinus of valsalva connects the high pressure reservoir of the systemic circulation with the low pressure system of the pulmonary circulation resulting in a systolic-diastolic, left to right shunt. There is volume overload of the left atrium, left ventricle and the aortic root. This volume overload is proportional to the shunt volume. Amount of shunt volume is influenced by the diameter of the ruptured sinus of valsalva and by the level of pulmonary vascular resistance. A large shunt causes a large volume of blood that is shunted from the systemic circulation into the pulmonary circulation. The inevitable consequence of this is pulmonary congestion and rapidly developing left sided heart failure.

Differential diagnosis may be venous hum, patent ductus arteriosus, traumatic injury to the aortic root, infective endocarditis, ventricular septal defect with aortic regurgitation, truncus arteriosus with truncal valve, aortic-ventricular tunnel.

References

1. Ott D. Aneurysm of the sinus of Valsalva. *Cardiac Surg Ann.* 2006;9:165-76.
2. Steves W. Congenital heart surgery nomenclature and database project:aortic aneurysm, sinus of valsalva aneurysm, and aortic dissection. *Ann Thoracic Surg.* 2000;69:147-63.
3. Vautrin E, Barone Rochette G, Philippe J. Rupture of right sinus of valsalva into right atrium: ultrasound, magnetic resonance, angiography and surgical imaging. *Arch Cardiovasc Dis* 2008;101:501-2.
4. Missault L, Callens B, Taeymans Y. Echocardiography of sinus of Valsalva aneurysm with rupture into the right atrium. *Int J Cardiol.*1995;47:269-72.
5. Chu SH, Hung CR, How SS, Chang H, SS Wang, Tsai CH et al. Ruptured aneurysms of the sinus of valsalva in oriental patients. *J Thorac Cardiovasc Surg.* 1990;99:288-98.
6. Dong C, YuWu Q, Tang Y. Ruptured sinus of valsalva aneurysm: a Beijing experience. *Ann Thorac Surg.* 2002;74:1621-4.
7. Harkness J, Fitton T, Barreiro CJ, Alejo D, Gott VL, Baumgartner WA. A32-year experience with surgical repair of sinus of Valsalva aneurysms. *J Cardiac Surg.* 2005;20:198-204.
8. Sánchez M, Garcia M, Quintana C, Kareh J. Heart failure in rupture of asinus of valsalva aneurysm. *Am J Med Sci.* 2006;331:100-102.
9. Lobato E, Greene M, Malias M, Gravenstein N. Intraoperative usefulness of transesophageal echocardiography: detection of unsuspected rupture of an aneurysm of the sinus of Valsalva. *J Cardio thorac Vasc Anesth.*1997;11:619-621.