

## Case Report

### Bell's Palsy due to Congenital Cholesteatoma of Petrous Apex: A Case Report

\*Zulkifli MFB<sup>1</sup>, Saim LB<sup>2</sup>

#### Abstract

*Congenital cholesteatoma (CC) is a rare disease, it accounts for 2-5% of all cholesteatomas [2] most common site being middle ear. Case report: We reported a case of 23-year-old female presented with progressive left sided facial asymmetry for 4 years and progressive hearing loss in the left ear for 2 years. She had normal left tympanic membrane and complete left lower motor neuron facial nerve palsy. High resolution computed tomography with contrast temporal bone showed extensive bony destruction, petrous apex and soft tissue lesion.*

*Patient then proceed with transmastoid translabyrinthine approach. Diagnosis of cholesteatoma confirmed by histopathological examination (HPE).*

*Congenital cholesteatoma of petrous apex is a rare case. It is a challenge to diagnose congenital cholesteatoma pre-operatively without specific radiological sign.*

*This is because the disease is generally difficult to differentiate with mucocele and cholesterol granuloma on CT scan. Therefore, intraoperative diagnosis more accurate rather than the preoperative diagnosis.*

*Keywords: Bell's palsy, congenital cholesteatoma, petrous apex.*

#### INTRODUCTION

Congenital cholesteatoma is one of the rare diseases of temporal bone. However, this disease rarely involves the petrous apex. In addition, it needs to be differentiated from the cerebello-pontine angle lesion and the petrous apex's lesions such as acoustic neuroma, epidermis cyst, mucocele, archanoid cyst and cholesterol granuloma. Generally, the incidence involving congenital cholesteatoma is estimated to be around 2-5 percent of all the cases involving

cholesteatoma, where the reported ratio of male to female predominance is 3:1 (2). Moreover, even in a normal temporal bone, it has been discovered that the congenital cholesteatoma can occur even in the absence of otorrhea. The first symptom of the disease is the facial nerve deficit then the unilateral sensorineural hearing loss (2). In order to investigate various lesions which are involving the cerebello-pontine angle, computed tomography (CT) scan is recommended and it is one of most important investigative tool. However, cholesteatoma is very difficult to diagnose because it does not have CT scan's specific radiological sign. At the age of 23 years, especially in female patients, petrous apex's congenital cholesteatoma cases are very rare (8). There are several surgical approaches for petrous lesion. The middle cranial fossa approach is preferred by neurosurgeons, and the transmastoid translabyrinthine approach is preferred by otologists.

#### CASE SUMMARY

A 23-year-old female patient presented with progressive left sided facial asymmetry in the past 4 years to complete facial nerve palsy and progressive hearing loss left ear in the past 2 years.

Initially, she was treated at peripheral clinic as Bell's palsy. After 1 year, she noticed that facial asymmetry worsening. So, she decided to seek treatment at a bigger hospital, only then patient was referred to us after high resolution CT and MRI mastoid with suspicious of cholesteatoma.

Complete Ear Nose Throat evaluation revealed normal tympanic membrane left side with complete left lower motor facial nerve palsy and severe sensorineural hearing loss in the left ear on pure tone audiogram.

Cerebellar sign was negative. High resolution CT and Magnetic resonance imaging (MRI) temporal bone revealed sclerosis of the mastoid bone with loss of mastoid air cells due to chronic mastoiditis. Soft tissue lesion and some fluid in the left middle ear and the attic of the tympanic canal. The left eustachian tube also occluded with soft tissue lesion or secretion and does not enhance with intravenous contrast. There is bony erosion in the tegmen tympani and expansion of the petrous bone. [Fig.-1, Fig.-2] This finding suggest cholesteatoma in the left middle ear with erosion of the

1. \*Dr. Muhd Faiz Bin Zulkifli, Department of Otorhinolaryngology- Head and Neck Surgery, KPJ Healthcare University College, Malaysia. Email:irshadianz@yahoo.com

2. Dr. Lokman Bin Saim, Ear, Nose and Throat – Head and Neck Consultant clinic, KPJ Tawakkal Specialist Hospital/ KPJ Healthcare University College, Malaysia

\*For Correspondence

petrous bone and involvement of the left facial nerve canal. Patient then proceed for transmastoidtranslabyrinthine approach.

Intraoperative finding showed that cholesteatoma occupying petrous apex of temporal bone, dura, tegmen tympani and superior posterior cranial fossa exposed. Long process of incus, stapes and oval window eroded. Tympanic part of facial nerve damaged. Neuroma at proximal part of chorda tympany noticed. Temporomandibular joint exposed. In this patient, we did not try for nerve repair or grafting as symptom of facial paralysis persist more than 6 months. Cholesteatoma completely removed. Diagnosis of cholesteatoma confirmed by HPE taken intra operative.

Post-operative patient was kept in ward for 2 days for intravenous antibiotic and close monitor.

Repeat check CT scan planned after 6 months.

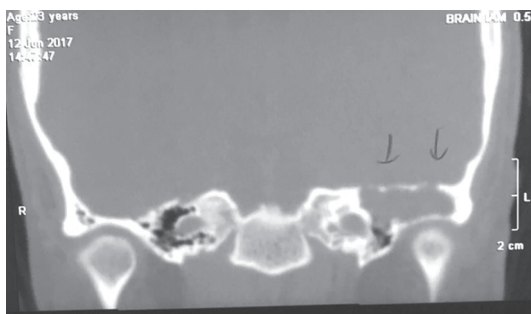


Fig.1 CT mastoid. Shows bony expansion of the petrous bone with soft tissue lesion in the tympanic cavity and attic.

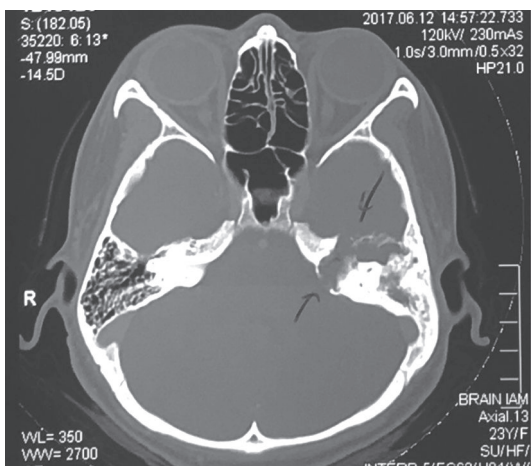


Fig.2. MRI brain and IAM. Shows bony expansion of the petrous bone with soft tissue lesion in the tympanic cavity and attic.

## DISCUSSION

The diagnosis of Bell's palsy is often regarded as a diagnosis of exclusion, thus all patients must be checked thoroughly to find the cause.<sup>1</sup> In this case, the patient has congenital cholesteatoma of the petrous apex. This disease can be either acquired or congenital. However, it is believed that the congenital cholesteatoma of the petrous apex is caused by the resting squamous cell.<sup>2</sup> The disease is described as congenital when it manifests itself without a past history of trauma or infection with intact and located behind the tympanic membrane.<sup>3</sup> This disease is destructive in nature, most of congenital cholesteatoma appear to be asymptomatic and appear to be innocuous keratin pearl. In severe conditions, they can enlarge and cause serious complications that include ossicular destruction, base of skull complications and facial paralysis.<sup>3</sup> Patients suffering from congenital cholesteatoma often have symptoms which are dependent on the direction of the extension of the disease. Those who are suffering from posterior mesotympanum lesions, usually anticipate that conductive deafness will be present owing to the ossicles' earlier erosion.<sup>4</sup>

As mentioned earlier, it is a challenge to diagnose congenital cholesteatoma by using radiological investigation. This is because the disease is generally difficult to differentiate with mucocele and cholesterol granuloma on CT scan. Therefore, this case preferred intraoperative diagnosis rather than the pre-operative one due to such challenges.<sup>5</sup>

To remove the cholesteatoma of the petrous apex, the transmastoid translabyrinthine method is the most basic technique to be considered, with or without transcochlear technique. However, these techniques cannot adequately remove cholesteatoma that is located deep down the petrous apex, which is fixed firmly onto the middle cranial fossa dura. In this case, the middle cranial fossa approach can be an effective method.<sup>5</sup>

In our case, we proceeded with the transmastoid translabyrinthine approach to remove the entire disease deep down the middle of the cranial fossa dura. This is possible through performing the partial labyrinthectomy. However, we are not considering cochlea's preservation and the vestibular function during the removal of extensive cholesteatoma of the petrous apex.

In cases where damage to the facial nerve in the extensive cholesteatoma of the petrous apex, the existing literature seems to favor sacrificing the facial nerve having the residual function needed for complete removal.<sup>6</sup>

## CONCLUSIONS

It is however not recommended to completely obliterate the cavity because there could be residual cholesteatoma as well

its complications such as the rupture of dura, jugular valve and the internal carotid artery. If cholesteatoma recurs, it would be difficult to investigate it in the obliterated cavity through CT and MRI<sup>7</sup>.

Regular follow up and 6 monthly MRI planned for this patient.

#### REFERENCES

1. Yetter, M. F., Ogren, F. P., Moore, G. F., & Yonkers, A. J. (1990). Bell's palsy: a facial nerve paralysis diagnosis of exclusion. *The Nebraska medical journal*, 75(5), 109-16.
2. Torun F, Taficiolu A, Tuna H. Primary petrous apex cholesteatoma: A case report. *Turk Neurosurg* 2004; 14:28-32.
3. Braganza RA, Kearns DB, Bilateral congenital cholesteatomas. *AM J Otol*1993;14:191-93.
4. Karmarker S, Bhatia S, Khashaba A, Saleh E, Russo ,Sanna M. Congenital cholesteatomas of the Middle Ear: A Different Experience. *AM J Otol* 1996; 17: 288-92.
5. Achilli V, Danesi G, Caverni L, Richichi M. Petrous apex arachnoid cyst: A case report and review of the literature. *Acta Otorhinolaryngol Ital* 2005;25:296-300.
6. Komune S, Nakagawa T, Haruta A, Matsuda K, Tono T. Management of cholesteatoma in the petrous apex. *Skull Base Surg* 2000;10:47-51.
7. Yanagihara N, Nakamura K, Hatakeyama T. Surgical management of petrous apex cholesteatoma: A therapeutic scheme. *Skull Base Surg* 1992;2:22-7.
8. Horn KL. Intracranial extension of acquired aural cholesteatoma. *Laryngoscope* 2000;110:761-72.